

Breast necrosis in a patient with COVID-19

Breast necrosis

Hakan Baysal¹, Begumhan Baysal², Gulnur Erdem², Gozde Kir³, Orhan Alimoglu¹¹ Department of General Surgery² Department of Radiology³ Department of Pathology, Faculty of Medicine, Istanbul Medeniyet University, Goztepe Prof Dr Suleyman Yalcin City Hospital, Istanbul, Turkey**Abstract**

Severe acute respiratory syndrome coronavirus 2 (SARS-CoV-2) is a highly contagious and pathogenic coronavirus that was detected in late 2019. It is a systemic disease that affects the entire body and is associated with various complications. Endothelial inflammation due to coronavirus disease (Covid-19) can affect the entire vascular system leading to thrombosis and vasculitis. A seventy-eight-year-old woman was admitted with complaints of sudden pain and color change in the right breast, suggestive of breast necrosis, in the first week of Covid infection. The necrosis did not regress, and simple mastectomy was performed. Herein, we present a case of unilateral breast necrosis that developed in a patient with Covid-19, which we have treated. In a disease like COVID-19 that affects all systems, a complete evaluation should be done, including the breasts.

Keywords

Breast Necrosis, Covid-19, Vasculitis

DOI: 10.4328/ACAM.22038 Received: 2023-11-05 Accepted: 2023-12-22 Published Online: 2023-12-26 Printed: 2024-03-20 Ann Clin Anal Med 2024;15(Suppl 1):S29-31

Corresponding Author: Hakan Baysal, Department of General Surgery, Istanbul Medeniyet University, Goztepe Prof Dr Suleyman Yalcin City Hospital, Fahrettin Kerim Gokay Street, Istanbul, Turkey.

E-mail: hakanbaysal_tr@yahoo.com P: +90 532 345 21 08

Corresponding Author ORCID ID: <https://orcid.org/0000-0003-3604-6177>

Introduction

Coronavirus disease (COVID-19) emerged in December 2019 and spread rapidly worldwide [1]. It affects multiple systems in the human body and causes symptoms depending on the damage caused. Vasculitis, vasculitis-like processes, and coagulopathy have been reported as a result of Covid-19 [2]. Breast involvement and multicentric breast abscesses have also been reported [3]. In addition, primary necrotizing fasciitis of the breast was reported with the late presentation of the patient in the initial days of the pandemic [4]. We present a case of breast necrosis that developed in a Covid-19 patient, which has not been previously reported in literature.

Case Report

A seventy-eight-year-old woman was admitted to the emergency department with complaints of severe pain and discoloration of the right breast in November 2021. She was diagnosed with Covid-19 one week prior to admission. The patient had a 20 year history of hypertension. No breast pathology was reported in the patient or her family histories. The patient had extensive hyperemic, painful, ecchymotic and bullous lesions (Figure 1a). Laboratory findings revealed neutrophilic leukocytosis and elevated lactate dehydrogenase (250 U/L), C-reactive protein (80 mg/L), and fibrinogen (800 mg/dl). Serum lipase was 210 U/L (normal 10–140 U/L). Among the hematological tests, haemoglobin, hematocrit, prothrombin time, activated partial thromboplastin time, international normalized ratio (INR), protein C, protein S and protein electrophoresis were normal respectively. D-Dimer levels (normal value < 0.55 mg/L) remained high between 6–10 mg/L. Bilateral ground-glass appearance and consolidations on thoracic computed tomography (CT) was consistent with a diagnosis of viral pneumonia. The patient was hospitalized for multidisciplinary follow-up, and treated with a double-dose inactivated vaccine, along with antiviral (Flavipavir) and antiaggregant (acetylsalicylic acid) therapy. On the 10th day, her PCR (Polymerase Chain Reaction) test result was negative, and cultures of discharge of breast bullous lesions and blood were sterile. Right breast ultrasound showed increased echogenicity of the skin and the subcutaneous fatty layers. Contrast-enhanced magnetic resonance imaging (MRI) revealed diffuse edema in the right breast and a hypovascular area, suggesting necrosis, in the retroareolar area (Figure 2). Tru-cut biopsy results were consistent with inflammatory lesions suggestive of fat necrosis. During follow-up, severe hemorrhagic necrosis continued at 15–20 cm, covering the nipple diametrically (Figure 1b). A simple mastectomy was performed due to progressive necrosis (Figure 1c). The pathology results showed total hemorrhagic infarction, microabscess formation, thrombi in medium and large vessels, and leukocytoclastic vasculitis (LCV). Grossly, large areas of hemorrhagic necrosis were observed in the breast skin and parenchyma (Figure 3). Post-operatively, the patient reported no new symptoms on follow-up for two years.

Discussion

Covid-19 is a SARS-CoV-2 syndrome that can affect all organs, including the circulatory system. Endothelial cell inflammation occurs in arteries, arterioles, capillaries, venules, and veins,

inducing pathological events such as tissue hypoperfusion, injury, thrombosis, and vasculitis. Mechanisms that facilitate these events include an antiphospholipid syndrome-like state, complement activation, systemic endothelial infection with viral spread, viral RNA absorption with immune thrombosis, coagulation pathway activation mediated by hypoxemia and immobility. The morbidity and mortality associated with Covid-19

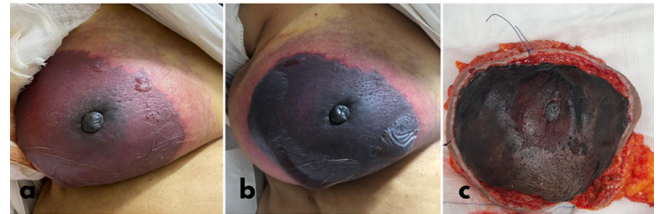


Figure 1. The skin was warm and painful on breast examination and had large ecchymotic and bullous lesions (a). Diametrically severe hemorrhagic necrosis persisted (b). Simple mastectomy was performed (c).

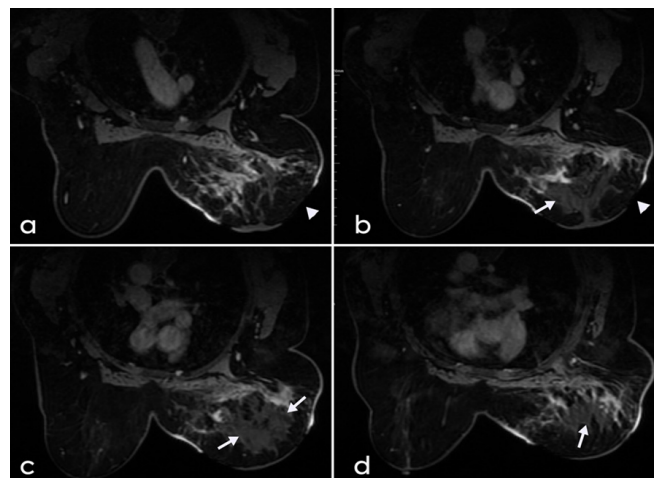


Figure 2. Contrast-enhanced MRI revealed skin necrosis (arrow heads) (a-b) in the right breast and hypovascular area (arrows), suggesting necrosis in the retroareolar area (b-c-d).

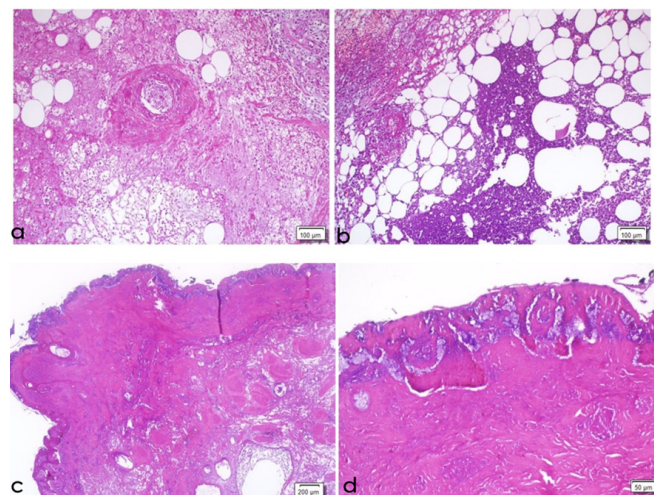


Figure 3. Fibrinoid necrosis of vessel wall with associated inflammatory cell infiltrate (hematoxylin and eosin x40) (a). Fat necrosis and abscess formation in the breast parenchyma (hematoxylin and eosin x100) (b). Completely necrotic epidermis and upper dermis in the breast (hematoxylin and eosin x40–100) (c-d)

have been attributed to an exogenous immune response. In vitro and in vivo data have shown that complement activation plays a critical role in the pathogenesis and disease severity in SARS-CoV and SARS CoV-2 [5]. There are 3 main independent but overlapping pathways for complement activation: classical, Lectin, and alternative pathways. With the activation of these pathways, severe localized tissue damage or systemic involvement and multi-organ failure may develop, as in our case, with endothelial pathogenesis and thromboinflammation. It has been stated that complement activation contributes significantly to thrombotic microangiopathies (TMA). The endotheliopathy that occurs here is the prototype of TMA-mediated damage induced by C5b-9. Significant microvascular accumulation of C4d and C5b-9, the primary enzymatic initiator of the Lectin pathway in mannan-binding lectin serine protease 2 (MASP-2) complement activation, has been reported in the skin and lungs of patients. Extensive endothelialitis with endothelial adherence and platelet-rich fibrin thrombosis in large and small arterial vessels has been reported [6]. In autopsy results of patients with COVID-19, macro- and microvascular thromboses, in all major organ arteries, arterioles, capillaries, and venules, have been revealed [7]. Thrombosis often accompanies vasculitis, but may be the cause of tissue damage in obliterated arteriolite [8]. Some types of vasculitides associated with Covid-19 have been reported in literature. These are LCV, IgA, and Kawasaki disease-like types of vasculitis. The treatment of vasculitis includes corticosteroids, monoclonal antibodies, immunosuppressive drugs, anticoagulants, antiplatelet agents, and immunoglobulins. The choice of drug mainly depends on the type of vasculitis and the affected organ [9]. In 6% of patients with Covid-19-related skin lesions, these may result in necrosis. Our patient presented with breast necrosis related to Covid-19, which has not been reported in literature, and the progressive necrosis was thought to be associated with a vasculitis-like and thrombotic process.

Conclusion

An exogenous immune response has been identified in mortality and morbidity associated with Covid-19. Thrombosis and developing vasculitis due to thrombotic microangiopathies seen in complications are responsible for many pathological conditions. Except for a few cases of Covid-19 breast involvement reported in the literature, we report our case as the first case of progressive breast necrosis. Additional studies are needed to fully elucidate the underlying mechanism of breast necrosis that may develop in patients with Covid-19 and to establish a definitive treatment protocol.

Scientific Responsibility Statement

The authors declare that they are responsible for the article's scientific content including study design, data collection, analysis and interpretation, writing, some of the main line, or all of the preparation and scientific review of the contents and approval of the final version of the article.

Animal and Human Rights Statement

All procedures performed in this study were in accordance with the ethical standards of the institutional and/or national research committee and with the 1964 Helsinki Declaration and its later amendments or comparable ethical standards.

Conflict of Interest

The authors declare that there is no conflict of interest.

References

1. Liu YC, Kuo RL, Shih SR. COVID-19: The first documented coronavirus pandemic in history. *Biomed J.* 2020;43(4):328-33.
2. Iba T, Connors JM, Levy JH. The coagulopathy, endotheliopathy, and vasculitis of COVID-19. *Inflamm Res.* 2020;69(12):1181-9.
3. Van Wert M, Ghio M, Graham C, Smetherman D, Sanders R, Corsetti R. Multicentric Breast Abscesses in a Patient Who Had COVID-19. *Ochsner J.* 2021;21(4):402-5.
4. Kamagate N, DeVito R. Necrotizing Soft Tissue Infection of the Breast during COVID-19 Pandemic. *Case Rep Surg.* 2020;2020:8876475.
5. Java A, Apicelli AJ, Liszewski MK, et al. The complement system in COVID-19: Friend and foe?. *JCI Insight.* 2020;5(15):e140711.
6. Afzali B, Noris M, Lambrecht BN, Kemper C. The state of complement in COVID-19. *Nat Rev Immunol.* 2022;22(2):77-84.
7. Schaller T, Hirschtbühl K, Burkhardt K, Braun G, Trepel M, Märkl B, et al. Postmortem Examination of Patients With COVID-19. *JAMA.* 2020;323(24):2518-20.
8. Carnevale S, Beretta P, Morbini P. Direct endothelial damage and vasculitis due to SARS-CoV-2 in small bowel submucosa of COVID-19 patient with diarrhea. *J Med Virol.* 2021;93(1):61-3.
9. Wong K, Farooq Alam Shah MU, Khurshid M, Ullah I, Tahir MJ, Yousof Z. COVID-19 associated vasculitis: A systematic review of case reports and case series. *Ann Med Surg (Lond).* 2022;74:103249.

How to cite this article:

Hakan Baysal, Begumhan Baysal, Gulnur Erdem, Gozde Kir, Orhan Alimoglu. Breast necrosis in a patient with COVID-19. *Ann Clin Anal Med* 2024;15(Suppl 1):S29-31