





# EX LIBRIS

DR. C. E. KIDDER  
LOS ANGELES

## ATLASES.

are authorized translations

Landatanten,

beauty, compactness, and published.

ored plates, besides numer- have been executed by the cases more than twenty im- result. Each plate is accom- and each book contains a con- to which it is devoted.

the atlases is that they offer a cal observation. Such ob- ents in large medical centers; y after long years of routine portant clinics these books g in a complete and con- of clinical work interpreted

ed plates, the profession has

heretofore been practically debarred from purchasing similar works because of their extremely high price, made necessary by a limited sale and an enormous expense of production. Now, however, by reason of their projected **universal translation** and reproduction, affording international distribution, the publishers have been enabled to secure for these atlases the **best artistic and professional talent**, to produce them in the **most elegant style**, and yet to offer them at a **price heretofore unapproached in cheapness**. The great success of the undertaking is demonstrated by the fact that the volumes have already appeared in **nine different languages**—German, English, French, Italian, Russian, Spanish, Danish, Swedish, and Hungarian.

The same careful and competent **editorial supervision** has been secured in the English edition as in the originals. The translations have been edited by the **leading American specialists** in the different subjects. The volumes are of a uniform and convenient size ( $5 \times 7\frac{1}{2}$  inches), and are substantially bound in cloth.

(For List of Books, Prices, etc. see back cover.)

HL

200



Digitized by the Internet Archive  
in 2007 with funding from  
Microsoft Corporation





ATLAS  
OF  
LEGAL MEDICINE

BY  
DR. E. VON HOFMANN

Professor of Legal Medicine and Director of the Medico-Legal Institute  
at Vienna

---

AUTHORIZED TRANSLATION FROM THE GERMAN

---

EDITED BY

FREDERICK PETERSON, M. D.

Clinical Professor of Mental Diseases in the Woman's Medical College,  
New York; Chief of Clinic, Nervous Department, College  
of Physicians and Surgeons, New York

ASSISTED BY

ALOYSIUS O. J. KELLY, M. D.

Instructor in Physical Diagnosis, University of Pennsylvania; Adjunct Professor  
of Pathology, Philadelphia Polyclinic; Visiting Physician to St. Mary's and  
St. Agnes' Hospitals; Pathologist to the German Hospital, Philadelphia

---

56 Plates in Colors, and 193 Illustrations in Black

---

PHILADELPHIA  
W. B. SAUNDERS

925 WALNUT STREET

1898

W, 700

H713a

1898

---

COPYRIGHT, 1898,  
By W. B. SAUNDERS.

---

---

ELECTROTYPED BY  
WESTCOTT & THOMSON, PHILADA.

---

PRESS OF W. B. SAUNDERS,  
PHILADA.

## AUTHOR'S PREFACE.

---

IN cheerfully complying with an expressed request of the publishers, asking me to prepare a "Hand-Atlas of Legal Medicine," I have been actuated by a variety of motives. In legal medicine, as in other branches, the desire for illustrations becomes daily more apparent, and this desire can be complied with but in part within the limits of the general text-books. Further, the hand-atlases which have already been issued by this publishing-firm exhibit evidences of decided progress in this department of art, and in consequence, as also because of their inherent qualities, have been accorded a widespread recognition. Finally, an opportunity was for the first time presented to provide a cheap book, and therefore one of easy acquisition, which would enable the practising physician, as also the student of medicine, to become acquainted graphically with the most important occurrences of medicolegal interest.

The illustrations are entirely original, and have been prepared either from recent cases or from museum specimens. A few have been reproduced from other publications, but they also are original observations.

In the preparation of the atlas my purpose has been that it should serve for further illustration of a good text-book—that it should be, to a certain extent, a supplement to the latter. I have therefore limited the descriptive

text, and have not considered a series of illustrations such as are found in every good text-book of legal medicine and in other widely distributed books, as, for instance, blood-spectra, spermatozoa, etc. This, on the one hand, diminishes the cost of the book, and, on the other, permits of the introduction of other important illustrations.

An exhaustive account of the subject has not been thought of, nor has it been considered possible. I have rather striven, as far as space, opportunity, and a regard to the cost permitted, to portray instructive instances of at least the most important medicolegal occurrences.

The colored plates and the photographic reproductions have been very ably executed by Mr. A. Schmitson, artist, and, for a layman, with an accuracy of comprehension worthy of commendation.

My two assistants, Drs. Haberda and Richter, privatis-docents, have heartily co-operated in the preparation of the work, and to them, for their assistance, I express my warmest thanks.

## PREFACE TO THE TRANSLATION.

---

THERE is perhaps no field of science in which the value of illustrations is greater than in forensic medicine. The problems which confront the coroner, the post-mortem examiner, and the courts of law must be solved by the presentation of indisputable facts. Many of these facts can be fully appreciated and understood only by the medicolegal expert of years of experience. But a volume such as this, made up chiefly of photographs and original drawings of various lesions and pathological conditions, taken directly from actual cases, supplies to every physician and student an enormous array of medicolegal data, such as would take one many years to acquire alone and unaided. This volume is a veritable treasure-house of information, gained from the rich material of one of the greatest institutes of legal medicine in the world, and collected by one who, until his death a few months ago, was perhaps the ablest living expert in his chosen domain of work.

The text has been Englished by Dr. Kelly, and the translation carefully compared with the original by the Editor-in-chief. Every effort has been made, while preserving so far as possible the difficult style of the author, to make the statements explicit and clear. There are some words in the text (such as *lochbruch*) which have no good equivalents in our tongue, and these have been necessarily rendered into literal English.

FREDERICK PETERSON.

NEW YORK, April, 1898.



## LIST OF PLATES AND FIGURES.

---

- Fig. 1. Abnormal smallness of the penis; incomplete cryptorchidism.
- Fig. 2. Cicatricial deformity of the penis.
- Fig. 3. Union of the under surface of the penis and the scrotal skin (synechia).
- Fig. 4. Epispadias.
- Fig. 5. Masculine pseudohermaphrodism.
- Fig. 6. Unusual development of the clitoris.
- Fig. 7. External masculine pseudohermaphrodism.
- Figs. 8-13. Hymen annularis and semilunaris (circular and semilunar hymens).
- Figs. 14-24. Varieties of hymens with congenital notches.
- Figs. 25-27. Hymen fimbriatus.
- Figs. 28-33. Divided hymens with symmetric openings.
- Figs. 34-36. Divided hymens with asymmetric openings.
- Fig. 37. Hymen of irregular form.
- Figs. 38-44. Hymens with partial or rudimentary septa.
- Figs. 45, 46. Hymens with two circular openings, situate one below the other.
- Fig. 47. Semilunar hymen with thinning of the right, and perforation of the left, lateral half. Indication of the formation of a hymen cribriformis.
- Fig. 48. Deflorated hymen annularis with congested and swollen lacerated edges.
- Figs. 49-52. Ordinary deflorated hymens.
- Figs. 53-55. Carunculæ myrtiformes.
- Figs. 56-59. Hymen septus (divided hymen) after defloration and after parturition.
- Figs. 60-62. Traumatic injuries of the external genitalia.
- Figs. 63-65. Os uteri of adult virgins.
- Fig. 66. Os uteri (pathological?) of a virgin of advanced age.
- Fig. 67. Os uteri of a woman who has given birth.
- Plate 1.** Cervix and vagina directly after parturition.

- Plate 2.** Spontaneous rupture of the uterus.
- Plate 3.** Tubal pregnancy; rupture of the sac; internal hemorrhage.
- Plate 4.** Embryo found within an uninjured amniotic sac among blood-clots, from a case of tubal pregnancy.
- Fig. 68. Fatal hemorrhage from retention of a portion of the placenta.
- Fig. 69. Retention of a portion of the placenta, with consecutive fatal hemorrhage.
- Figs. 70, 71. Two uteri in the very earliest stages of pregnancy.
- Fig. 72. Human ovum of the eighth or tenth week.
- Fig. 73. Rupture of the vagina through coitus or by the finger.
- Fig. 74. Acute sepsis following abortion. Punctured wound in the fornix of the vagina.
- Fig. 75. Abortion induced by a probe-like instrument. Perforation of the posterior wall of the uterus.
- Fig. 76. Abortion induced by rupture of the membranes of the ovum. Slit-like laceration above and below the internal os uteri.
- Fig. 77. Abortion induced by injections. Perforation of the fornix of the vagina and the fundus of the uterus.
- Fig. 78. Divulsion of the cervix from the uterus. Abortion.
- Plate 5.** Respiratory organs and heart of a full-term child which died during birth of "fetal suffocation" from premature respiration.
- Fig. 79. The epiphyses of the lower extremity and of the humerus of a mature, newly born child.
- Fig. 80. Epiphyses and posterior tarsal bones of a premature, and of a full-term newly born, and of a 3½-months-old child.
- Figs. 81, 82. Suffocation of the newly born by intentional obstruction of the pharynx.
- Plate 6.** Lungs of newly born infants.
- Plate 7.** Newly born child. Suffocation by a portion of the membranes.
- Fig. 83. Congenital fissure-formation of the skull of the newly born.
- Fig. 84. Defects of ossification in the skull of a newly born child.
- Fig. 85. Pretended precipitate birth in a closet. Spoon-shaped depression of the left, compression-fracture of the right, parietal bone.
- Fig. 86. Fracture of the skull from a fall on the vertex.
- Plate 8.** Fracture of the base of the skull, with extradural hemorrhage.
- Plate 9.** Traumatic extradural hematoma.
- Plate 10.** Fracture of the base of the skull, with rupture of the middle meningeal artery—after removal of the extradural hematoma.
- Fig. 87. Fracture of the skull due to compression.
- Fig. 88. Star-shaped fracture of the parietal region.
- Plate 11.** Recent contusions of the brain.

- Fig. 89. Healed hole-fractures (Lochbrüche) produced by a black-jack.
- Figs. 90, 91. Fractures of the skull due to blows of a horse's hoof.
- Plate 12. Healed contusions of the brain.
- Fig. 92. Hole-fractures (lochfracturen).
- Fig. 93. Fractures of the skull produced by blows with a round or so-called French hammer.
- Fig. 94. Skull of a man who was murdered and remained buried in a manure-mound for four years.
- Fig. 95. Circumscribed destruction of the right occipital region produced by a blow with a hatchet.
- Fig. 96. Fracture of the frontal bone produced with a brick.
- Fig. 97. Fracture of the skull produced with a mason's hammer.
- Fig. 98. Fracture of the skull produced by a fragment of glass.
- Fig. 99. Manslaughter by means of a long, angular bar of iron.
- Plate 13. Contusion of the lung.
- Plate 14. Peritonitis from traumatic rupture of the jejunum.
- Fig. 100. Healed fracture of the right parietal region.
- Figs. 102, 103. Injury of the lung the result of various fractures of the ribs.
- Plate 15. } Murder the result of various blows inflicted with different  
Fig. 101. } instruments.
- Plate 16. Suicide by cutting the throat. Death through suffocation.
- Figs. 104-106. Suicide by cutting the throat.
- Fig. 107. Body of a 4-months-old child, perforated, to show the cleavage of the skin.
- Fig. 108. Numerous punctured wounds of the stomach produced with a conical instrument.
- Plate 17. Suicide through stabbing.
- Plate 18. Triple injury to the small intestine produced by a stab. Peritonitis.
- Fig. 109. Stab-wounds produced with a four-cornered picture-nail.
- Fig. 110. Punctured wound in the parietal bone produced with a knife.
- Fig. 111. Punctured wounds of the skull.
- Fig. 112. Punctured wounds produced with a sharpened three-cornered file.
- Figs. 113, 114. Punctured-incised wounds of the left hand received in self-defence.
- Figs. 115, 116. Murder produced with a fascine-knife.
- Fig. 117. Saber-blow.
- Fig. 118. Murder caused by numerous hatchet-blows.
- Fig. 119. Murder caused by a saber-blow.

Fig. 120. Fracture of the skull produced by a blow with the cutting-edge of a hatchet.

**Plate 19.** Close-range gunshot-wound in the region of the heart produced with a revolver of 9 mm. caliber.

Fig. 121. Suicide with a carbine.

Fig. 122. Gunshot-wound of the right temporal region produced with a double-barrelled rifle, which in shooting burst; suicide.

Fig. 123. Suicide by six shots in the cardiac region, four of which penetrated the heart itself.

Fig. 124. Revolver-shot in the mouth.

Fig. 125. Suicide by a gunshot-wound in the mouth.

Fig. 126. Shot through the dependent mamma, with three external openings.

Fig. 127. Suicide by a shot with a hunting-rifle and "spreading-cartridge" (Stauchpatrone).

Fig. 128. Grazing gunshot-wound of the right external ear, with scattered grains of powder in its vicinity.

Fig. 129. Gunshot-wound transversely through the brain; suicide.

Fig. 130. Simple punctured gunshot-wound of the frontal bone produced with an ordinary revolver.

Fig. 131. Close-range shot with a Mannlicher rifle; suicide.

Fig. 132. Wound of exit of the gunshot-injury produced with a Mannlicher rifle, illustrated in Fig. 131.

Fig. 133. Revolver-shot in the frontal bone.

Fig. 134. Wound of exit at the right side of the occiput of a gunshot-wound through the left frontal region; suicide.

Fig. 135. Suicide by a shot with an army revolver into the right temporal region.

Fig. 136. Suicide by a shot in the left temporal region with a moderately large revolver loaded with broken lead.

Fig. 137. Murder by anarchists; gunshot-wound.

Figs. 138, 139. Suicides by gunshots; unusual situation of the wounds of entrance.

Fig. 140. Gunshot-wound by a hunting-rifle.

**Plate 20.** Encircling gunshot-wound.

Figs. 141-169. Deformation of projectiles.

**Plate 21.** Burns produced by flames.

Fig. 170. Murder or suicide by burning.

Fig. 171. Right upper arm and scapula of a charred body, with the muscles attached to them.

Fig. 172. Healed scald-wound of the esophagus.

**Plate 22.** Suicide by hanging; suspension of the body for several days; peculiar distribution of the hypostases.

Figs. 173-177. Various positions of the noose in cases of persons hanged.

**Plate 23.** Suicide by hanging with a double rope. Asymmetric position of the noose.

**Plate 24.** Suicide by hanging with an old rope wound five times about the neck.

Fig. 178. Suicide by hanging in the kneeling posture.

Fig. 179. Suicide by hanging in a semi-sitting posture.

Fig. 180. Suicide by hanging in the prone posture.

Fig. 181. Fracture of the larynx and of the hyoid bone in a person hanged.

Fig. 182. Bilateral rupture of the sternocleidomastoid muscles in a person hanged.

Fig. 183. Fracture of the thyroid and cricoid cartilages in a person hanged.

Fig. 184. Self-strangulation.

Fig. 185. Newly born child killed by having its throat cut and by being strangled.

**Plate 25.** Lungs of a dog which was drowned.

**Plate 26.** Left hand of a drowned day-laborer whose body remained in the water twenty-four hours.

**Plate 27.** Left hand of a drowned person whose body had remained in running water for several weeks.

**Plates 28, 29.** Fungus- (algæ-) formation on a cadaver found in water.

**Plate 30.** Alterations of the blood due to irritant poisons.

**Plate 31.** Poisoning by caustic soda.

**Plate 32.** Poisoning with concentrated sodium hydrate colored with ultramarine-blue.

**Plate 33.** Suicidal poisoning with concentrated sulphuric acid.

**Plate 34.** Poisoning with dilute sulphuric acid.

**Plate 35.** Hydrochloric-acid poisoning.

**Plate 36a.** Duodenum from a case of hydrochloric-acid poisoning.

**Plate 36b.** Spleen from a case of carbolic-acid poisoning.

**Plate 37.** Poisoning with concentrated nitric acid.

**Plate 38.** Poisoning with carbolic acid. Suicide or accident?

**Plate 39.** Poisoning with carbolic acid. Suicide.

**Plate 40.** Cauterization of the lips and the region about the mouth with lysol.

**Plate 41.** Acute poisoning with corrosive sublimate.

**Plate 42.** Subacute poisoning with corrosive sublimate.

**Plate 43.** Corrosive-sublimate dysentery.

**Plate 44.** Kidney from a case of corrosive-sublimate poisoning.

Fig. 186. Stricture of the esophagus and cicatrix of the stomach the result of poisoning with liquor potassæ.

Fig. 187. Stricture of the esophagus following the ingestion of caustic potash. Perforation of the esophagus with an esophageal sound.

Plate 45. Potassium-cyanid poisoning.

Plate 46. Fauces, pharynx, and entrance to the larynx from a case of potassium-cyanid poisoning.

Plate 47. Subacute phosphorus-poisoning.

Plate 48a. Liver from a case of subacute phosphorus-poisoning.

Plate 48b. Kidney from a case of subacute phosphorus-poisoning.

Plate 49. Stomach from a case of acute arsenical poisoning. Murder by poison.

Plate 50. Small intestine from a case of acute arsenical poisoning.

Plate 51. Carbonic-oxid poisoning (charcoal-fumes).

Plate 52. Agonal injuries of the face.

Plate 53. Abnormal situation of postmortem lividity as a result of the abdominal position of the body.

Plate 54. Lower extremity of a newly born child which remained several months in running water; formation of adipocere.

Plate 55. Portion of the abdominal skin of a body which had been in water two or three months, and which demonstrates the formation of so-called adipocere.

Fig. 188. Larvæ of flies in the angles of the eyelids and mouth.

Fig. 189. Lower extremity of a newly born child gnawed by rats.

Figs. 190, 191. Lower half of the body of a newly born child with numerous puncture-like wounds of the skin.

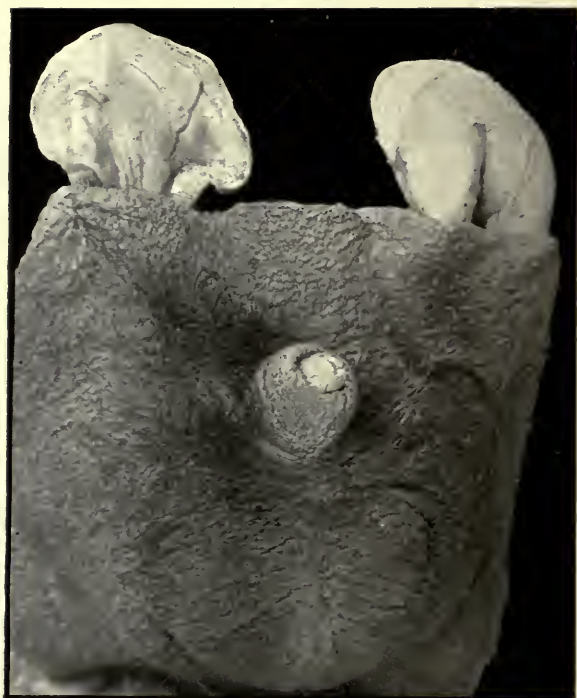Plate 56. Mummified cadaver.

Fig. 192. Excessively putrescent body of an old man—in great part consumed by maggots—found sixteen days after death.

Fig. 193. Skull of a five-year-old child, with all the temporary teeth and the germinal deposits of the permanent teeth.



Fig. 1.



## FIGURE 1.

### **Abnormal Smallness of the Penis; Incomplete Cryptorchidism.**

The genitals are from an unmarried man, aged 46 years, who died suddenly of cerebral hemorrhage.

The corpse was fat and well developed; the face, excepting a scanty downy moustache, beardless; the larynx not prominent, completely cartilaginous; the costal cartilages unossified; the mammæ undeveloped; the pubic hair but moderately developed, limited above transversely.

The penis is present as a cylindrical-shaped body 1.5 cm. long, 12 mm. thick. Its anterior half is formed by a correspondingly small glans with exposed tip, but otherwise covered by the prepuce. The scrotum is a relaxed, shallow, wrinkled skin-pocket with distinct raphe. In it small testicles are to be felt, which, on more careful dissection, are found as soft, relaxed bodies the size of walnuts, situate in the anterior part of the inguinal canal, and revealing distinct testicle and epididymis. The seminal vesicles are very small and empty. Spermatozoa are demonstrable neither in the latter nor in the testicles.

We have therefore to do with a case of incomplete descent of the testicles, with their persistence in the inguinal canal and their consequent atrophy, and with an abnormal smallness of the penis. The congenital origin of this defective formation of the genitalia is indicated by the imperfect development of the masculine habitus—similarly as occurs in individuals castrated before puberty—by the abundant formation of fat, absent beard, non-prominent larynx, and the completely soft and readily cut laryngeal and costal cartilages, despite advanced age.

Under these circumstances, had the ability of the individual to beget been in question, one should have been obliged to assert that he possessed neither the power to copulate nor to impregnate.

## FIGURE 2.

### Cicatricial Deformity of the Penis.

The preparation is from a married man, aged 64 years, the father of a son aged 20 years. As he was dressing he died suddenly on the morning of November 14, 1880. To determine the cause of death, a necropsy was performed November 15th. This revealed hypertrophy of the heart, consequent upon a high grade of endarteritis deformans and nephritis.

In both inguinal regions, extensive white cutaneous cicatrices reaching to the inner surfaces of both thighs, and to the outer surface also of the right, with an undermined bridge of skin corresponding to the right Poupart's ligament; the scars on both sides extending also to the upper part of the scrotum. In addition, similar scars on the inner aspect of the left knee, on the entire posterior surface of the left, and on the upper third of that of the right thigh.

Of the **penis**, there remains but an irregular thick stump, the width of two fingers in length. The skin-covering is everywhere cicatricial; to the right it is movable; to the left, posterior to the still apparent groove of the glans penis, it is united with the deeper tissues, whereby the entire stump of the penis is curved toward the left. The glans is flat, fungiform, as though compressed anteroposteriorly, and at the same time twisted by a cicatrix toward the left. The urethral orifice is to the right and below, forming an open transverse fissure with plump edges.

Concerning the production of this deformity, there was unfortunately nothing to learn. It appears, however, to have been produced during childhood, as neither the wife nor the son of the deceased knew anything of it, and were unaware of any disease or injury having been sustained by the man during the past decennium. The scars and the deformity of the penis most probably originated in the healing of wounds produced by burns.

Despite the high grade of the deformity, it cannot be asserted that the deceased was incapable of *coitus*, as the stump of the penis was the breadth of two fingers in length and during erection was capable of elongating, so that the introduction of the organ into the entrance of the vagina at least was possible. In how far the scars, particularly the immovable ones of the left side, were capable of influencing erection cannot be determined.

As, in addition, the testicles of the man, despite his advanced age, were large and intact, and as the excretory passages for the semen showed no abnormalities, in a given case there would be no justification for an assertion that the aforementioned son could not have been begotten by the deceased.

Fig. 2.

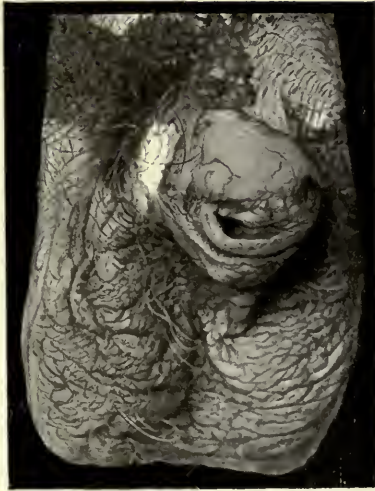

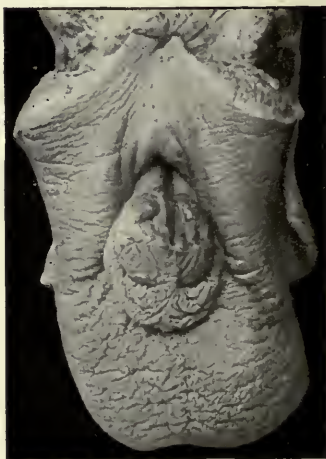




Fig. 3.

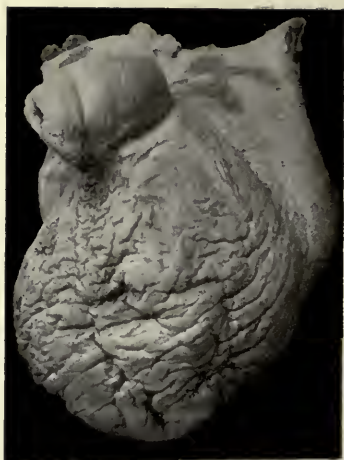

Fig. 4.



## FIGURES 3, 4.

### Fig. 3.—Union of the Under Surface of the Penis with the Scrotal Skin (Synechia).

This rare malformation befell a 4-year-old boy—otherwise normally developed. The skin of the penis is—from its root to the prepuce—united with the anterior surface of the scrotum, the skin of which along the anterior part of the scrotal raphe is directly continuous with the lateral surfaces of the penis. The genitalia are otherwise entirely normal.

As regards sexual intercourse in later life, this malformation would have been of importance, as it would probably have given rise to an impediment in the erection and insertion of the penis. The hindrance to erection would probably not have been great, as the corpora cavernosa are normally developed, and the relaxation and elasticity of the skin, both of the scrotum and the penis, permit of wide movement. On the other hand, however, an impediment to the insertion of the penis would probably have arisen; but this could hardly have been designated an essential obstacle to coition, as, firstly, an introduction into the vulva at least would have been possible, and, secondly, by a small operation the impediment could have been radically removed.

---

### Fig. 4.—Epispadias.

The genitalia of a 5-months-old boy. The scrotum is normally developed, and contains both testicles. The penis is somewhat shortened, and shows a club-shaped thickening of the extremity. This is dependent externally upon the prepuce split open by the strikingly wide, apparently anteroposteriorly flattened glans. The latter is split open from the meatus urinarius, and this slit extends as a furrow along the dorsum of the penis to beneath the symphysis ossium pubis, from which point the bladder may be entered. Under the symphysis the skin forms an arched elevation open below, beneath which the root of the penis is concealed.

As the genitalia are otherwise normally formed, and as the corpora cavernosa are well developed, coition later would not have been prejudicially affected. Nor could one entirely exclude the capability of impregnating, as an ejaculation of semen, if not into the vagina itself, would still have been possible into the *introitus* thereof, or at least into the vulva.

## FIGURES 5, 6.

### **Fig. 5.—Masculine Pseudohermaphrodisim.**

Female child, with normal internal and hermaphroditic external genitalia. Of the latter, the labia majora and minora are normally developed; the clitoris, however, is excessively large, resembling a penis with hypospadias. The latter is drawn markedly downward and reveals on its under surface an open, furrowed urethra, running backward from the tip of the glans, ending in the perineum, and leading into the bladder. The vaginal orifice is greatly contracted, scarcely the size of a lentil, but leads immediately into a vagina of normal caliber. A hymen is not present.

---

### **Fig. 6.—Unusual Development of the Clitoris.**

Female genitalia, with normal development of the labia majora and minora, but with marked contraction of the orifice of the vagina. The clitoris has a decidedly penis-like character, is 4.5 cm. long, 3 cm. thick, and possesses a much wrinkled prepuce and a strongly developed but not perforated glans. From the apex of the latter a furrowed groove runs along the under surface of the clitoris to the symphysis, and above the contracted orifice of the vagina enters the bladder.

During childhood the genitalia were thought to be those of a male, but after repeated careful examinations were recognized as those of a female.

Fig. 5.

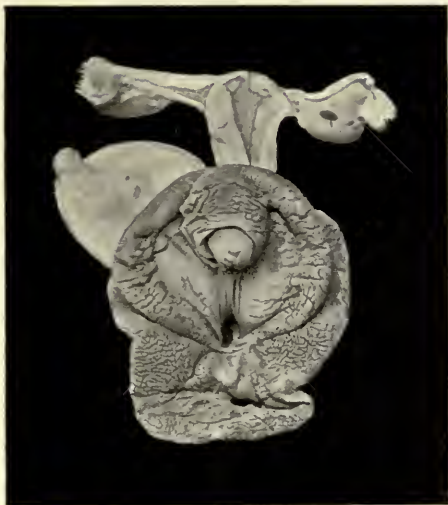

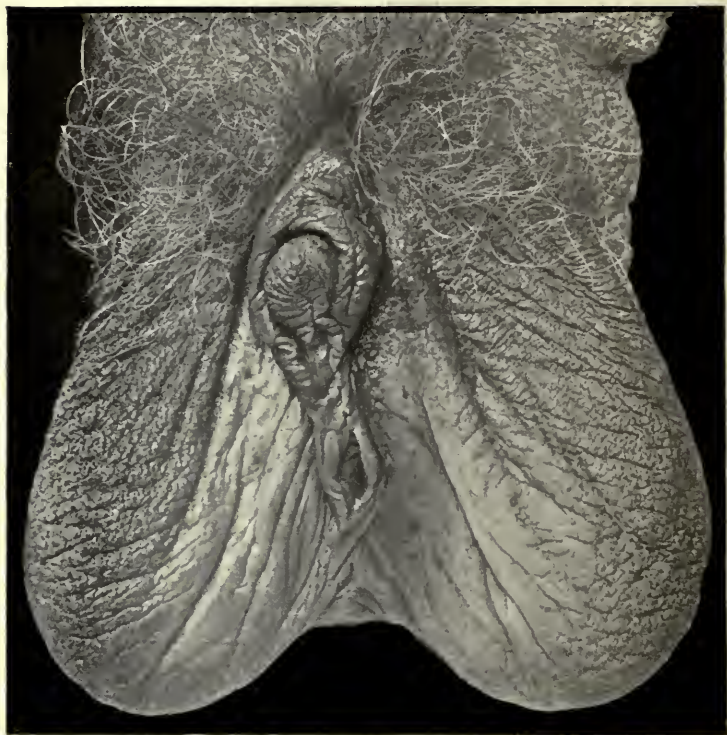
Fig. 6.

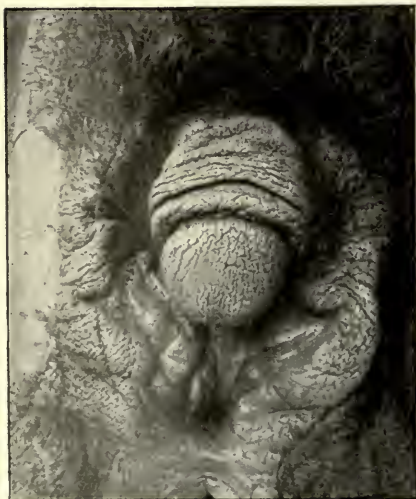





Fig. 7.



## FIGURE 7.

### External Masculine Pseudohermaphroditism.

The illustrative case was that of an unmarried, supposedly female peddler, aged 62 years, who was injured by falling from a wagon, and whose real sex was first determined by the official necropsy.

The body was 153 cm. long, bony, poor in muscle, thin, and somewhat marasmic. On the upper lip and on the chin were isolated, short, gray hairs. The rest of the senile face was beardless. The pubic hair was blond, moderately developed; the limitation of the hair above was arched.

The penis is as large as the terminal phalanx of the thumb; the glans is the size of a hazelnut and is partially covered by a short prepuce which at its lower part is split, and which, with the intervening thickened and likewise divided frenum, descends in the direction of the raphe a distance of 1.5 cm. It then unites with the latter to form a dense, tendinous, protruding elevation, which after a course of 1.3 cm. divides again and ends in a pointedly oval fissure, 1.5 cm. long, surrounded by prominent, dense, tendinous margins. This fissure deepens as a funnel inward and upward, whence one may enter the urethra and the bladder. The fissure, even when the thighs were separated, was concealed by the much dependent halves of the scrotum, between which there remained a large, penetrating, funnel-shaped space, within whose depths the aforementioned fissure was situated. It was apparently because of this and because of the smallness of the penis, a vulva was simulated and the mistake as to the sex produced.

The testicles, situated within the scrotum, were of ordinary size, but soft and, on section, cinnamon-brown. The vasa deferentia were patulous; the verumontanum in the posterior part of the urethra, with the utriculus and the ejaculatory ducts, was normally formed; the seminal vesicles were small, slightly sacculated, and contained a quantity of brownish fluid. Spermatozoa were nowhere demonstrable.

Of the relatives, no one supposed that the deceased had an abnormality of the genitalia, nor had the deceased herself ever made any declaration in this regard; still, she is said never to have menstruated and never to have manifested sexual desires, and in consequence remained unmarried.

### FIGURES 8-13.

#### **Hymen Annularis and Semilunaris (Circular and Semilunar Hymens).**

FIG. 8.—**Circular hymen**—hymen annularis—with wide opening and circular, smooth-edged margin, of equable height throughout, surrounding the entrance to the vagina.

FIG. 9.—**Circular hymen** with margin somewhat notched above, but otherwise with rather smooth edges; on the posterior surface the posterior columna rugarum directed to the left.

FIGS. 10-12.—**Transitions to semilunar hymens**—in that the orifice of the hymen is no longer centrally situated, but is shifted upward, whereby the lower margin of the hymen becomes wider than the upper. In Fig. 12 is an indication of the keel-shaped appearance which the folds of the hymen assume when the genitalia are closed.

FIG. 13.—**Semilunar hymen**—hymen semilunaris.—At the lower part of the entrance to the vagina is a falciform, sharp-edged fold of mucous membrane, the cornua of which terminate on both sides at the middle of the *introitus*.

Fig. 9.

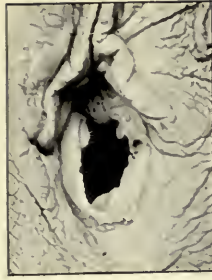


Fig. 8.



Fig. 11.

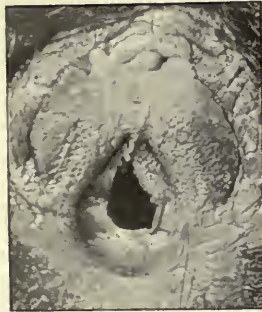

Fig. 10.

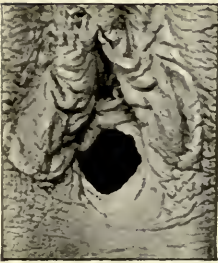

Fig. 13.

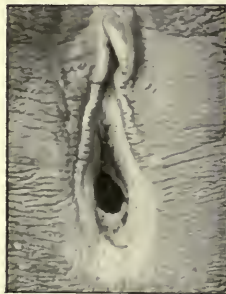


Fig. 12.

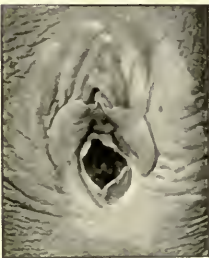





Fig. 14.

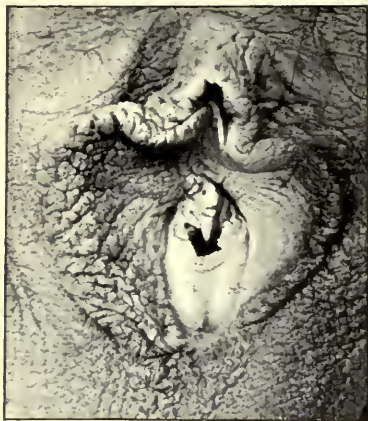


Fig. 15.

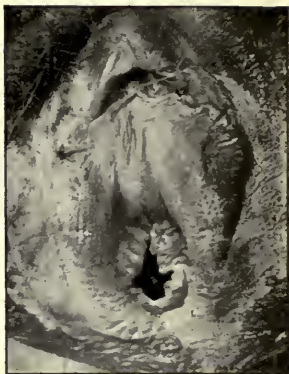

Fig. 16.

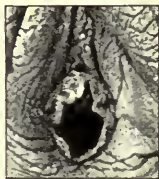

Fig. 17.

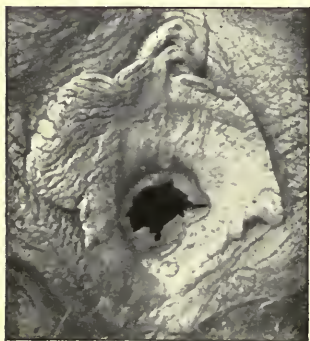
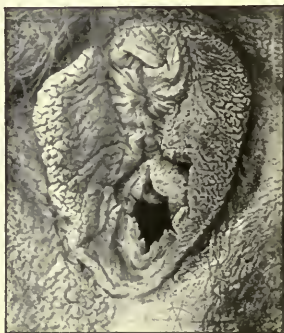
Fig. 18.



## FIGURES 14-18.

### Varieties of Hymens with Congenital Notches.

FIG. 14.—Hymen with excentric opening toward the upper part; in the left upper quadrant is a wide notch, with fimbriated edges reaching to the wall of the entrance to the vagina.

FIG. 15.—Circular hymen with various smooth projections of the free edge.

FIG. 16.—Hymen of a newly born child with deep notches to the right and below.

FIG. 17.—Circular hymen with a deep congenital notch both below and in the left upper part. All the edges smooth and rounded.

FIG. 18.—Hymen annularis of fleshy consistency with four deep notches, which, similarly to the intervening hymenal tissue, possess gradually thinning smooth edges.

## FIGURES 19-24.

### **Varieties of Hymens with Congenital Notches.**

FIG. 19.—Hymen with numerous shallow notches regularly arranged equidistant from each other, giving to the free edge a dentate appearance.

FIG. 20.—Hymen semilunaris with a notch situate in the middle of both lateral aspects.

FIGS. 21 and 22.—Deep irregular notching of the hymen of a newly born child, whereby it assumes a dentate appearance.

FIG. 23.—Serrated hymen of a virgin at puberty. It possesses a wide sinuous opening, does not form a tense diaphragm, and permits the introduction of a voluminous body (speculum) without rupturing,—the serrations simply receding.

FIG. 24.—Serrated hymen of an adult virgin. The hymen consists of several flaps which have rounded edges, and which in part show slight formation of fimbria and are readily displaced. As at the same time the lower margin is strikingly narrower than the others, this hymen represents a stage of transition to the so-called labial form of hymen.

Fig. 19.




Fig. 20.

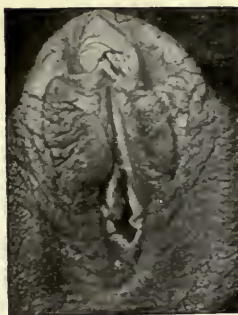


Fig. 21.

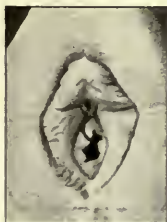

Fig. 22.




Fig. 24.

Fig. 23.








Fig. 25.

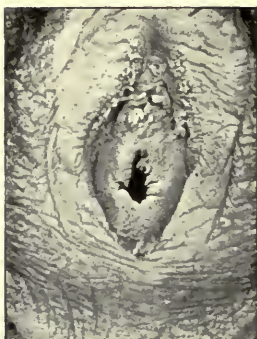

Fig. 26.

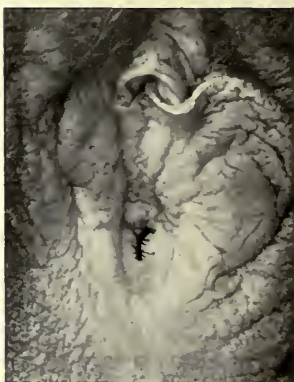

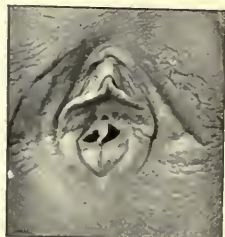
Fig. 27.

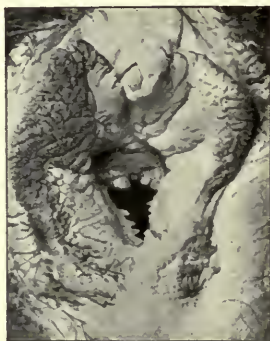

Fig. 28.



Fig. 29.



## FIGURES 25-29.

### Hymen Fimbriatus and Hymen Bipartitus or Septus.

In FIG. 25 we see at the middle of the right lateral aspect of the generally circular hymen of a 16-year-old virgin, a rather wide notch, and in the left side two fissure-like radiating notches, all of which continue on the posterior wall of the hymen between the adjoining folds of the vaginal mucous membrane. The free edge, both of these notches and of the rest of the hymen, possesses delicate fimbriated papillæ, which are also scattered over the anterior surface of the hymen, on the inner surface of the labia minora—especially at its upper part—and in the region of the clitoris. We have, therefore, to do with an apparently congenital papillary hyperplasia of the mucous membrane of the external genitalia, but especially with that variety of hymen-formation which, since Luschka, has been designated *hymen fimbriatus*.

FIGS. 26 and 27 show two similar but much more marked cases. In both the hymen is serrated, and the free edge of all the notches and projections possesses—in Fig. 26 cilia-like, and in Fig. 27 somewhat coarser, processes, whereby both hymens present a corolliform appearance.

FIGS. 28 and 29 furnish examples of so-called divided hymen—*hymen bipartitus* or *hymen septus*. Both affect circular hymens, each with an opening, situate toward the upper part, divided into two each of equal size by a narrow band of mucous membrane directed from above downward. This variety of hymen occurs frequently in varying combinations with other vestiges of the former bifurcation of the genital tube, so that there appears to exist a relationship between both of these formations. Fig. 28 is further of interest, as the septum appears constricted in the center.

## FIGURES 30-34.

### Varieties of Hymens with Divided Openings.

FIGS. 30, 31, and 32 show similar septum-formation with symmetrical openings of semilunar hymens. Especially interesting is the case illustrated in Fig. 31, as the septum is as a fine thread coursing from the center of the hymenal crescent to the superior periphery of the vaginal entrance, giving to the hymen the appearance of an unfurled sail.

FIG. 33.—This hymen was that of an unmarried woman, aged 24 years. It is of extraordinary dense almost tendinous consistency, and possesses two almost bean-sized, laterally situated openings, separated from each other by a dense, tendinous septum, 1 cm. wide and  $\frac{1}{2}$  cm. thick. There is no doubt that this hymen, because of its unusual solidity—increased by the septum-formation—would constitute a decided impediment to coition, and in case of marriage might possibly have given rise on the part of the husband to a suit-at-law for divorce or separation.

The medicolegal expert would have had to declare, 1, that a positive impediment to coition was present; 2, that it was present before marriage; but, 3, that it could be removed by an operation. The possibility of fecundation despite the impediment to coition could not be unconditionally denied, as even a coitus merely within the vulva may lead to the entrance of semen into the vagina and subsequent fecundation, the proof of which possibility is afforded by numerous actual occurrences.

FIG. 34.—Divided circular hymen of an adult woman, with a larger opening to the right, and to the left a much smaller round opening with smooth edges. In this case during coitus there would have been possible but a unilateral rupture of the hymen, as the penis would have more easily entered through the larger opening, probably leaving intact the left opening and the septum.

Fig. 30.

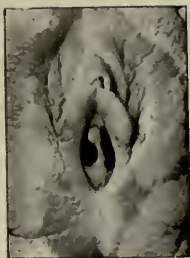


Fig. 31.

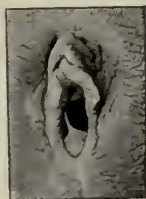


Fig. 32.

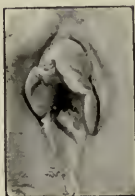

Fig. 34.

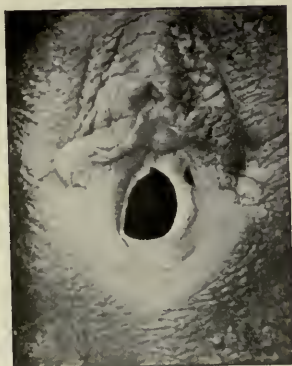


Fig. 33.

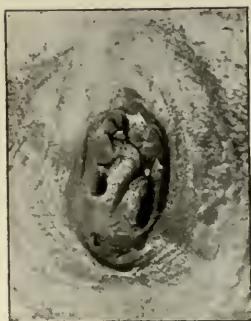





Fig. 35.

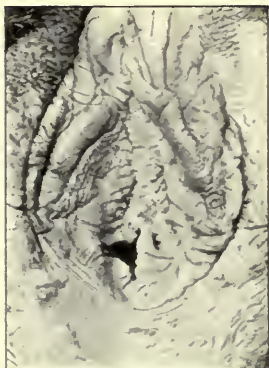

Fig. 36.

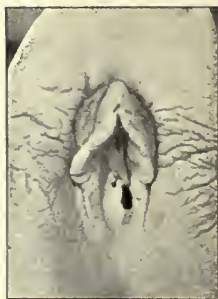

Fig. 37.

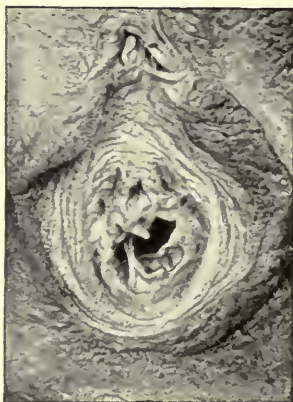
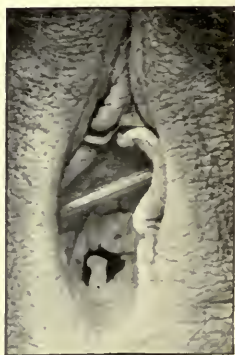
Fig. 38.



## FIGURES 35-38.

### Divided Hymens with Asymmetric Openings; Hymen with Partial Septum.

FIG. 35.—Divided hymen of a girl of marriageable age, with a large, irregular triangular opening to the right, the base of which corresponds to the septum and the apex to the wall of the right side of the vaginal entrance. The left opening is irregularly round, the size of a lentil. The hymen is entirely fleshy. In this case, also, the introduction of the penis would have been effected through the larger opening to the right, especially as this half of the hymen does not form a tense membrane, but consists in reality of two flaps which may be readily displaced.

FIG. 36.—Semilunar hymen of an infant with a large opening to the left and a smaller higher-situated opening to the right.

FIG. 37.—Hymen annularis of an adult woman with multiple pouch-like formations induced by the attachment of the vaginal rugæ to the posterior surface of the hymen, and with a narrow septum which proceeds from these rugæ posterior to the lower insertion of the hymen and courses somewhat diagonally to the right and above, where behind the hymen it likewise becomes again lost in a fold of mucous membrane. In addition from the upper edge of the hymen there arises a conical-shaped process projecting into its orifice.

FIG. 38.—Circular hymen of a girl aged 20 years. From the centre of the lower border of the hymen there arises, as a continuation of the more posteriorly situated support-pillars, a fleshy prominence, 1 cm. in length, projecting pointedly into the orifice of the hymen. This is an instance of the so-called **hymen partim septus**, in which only the lower portion of the septum persists.

## FIGURES 39-44.

### Varieties of Hymens with Rudimentary Septa.

FIG. 39.—Circular hymen with a very narrow margin, from whose lower periphery to the right there depends a fleshy flap about 1 cm. long and  $\frac{1}{2}$  cm. wide. This is to be looked upon as an instance of rudimentary septum-formation.

FIG. 40 shows an almost similar case with a somewhat wider dependent flap.

FIG. 41 is a divided hymen with two lateral, rather similar openings, whose fleshy septum projects as a wedge and below becomes a conical plug 1 cm. long, which hangs from the vulva.

FIG. 42.—Irregular circular hymen, with a round vermiform projection which arises from the support-pillars along the posterior wall of the hymen and hangs dependent over the edge of the latter.

FIG. 43.—The hymen of an infant, consisting of three narrow flaps, of which two are situated laterally, whereas the third, as a conical projection, is directed upward from the center of the posterior periphery of the vaginal entrance, and as a continuation of the posterior columna vaginalis.

FIG. 44.—Semilunar hymen of a newly born child with a conical protuberance, which, independently of the hymenal crescent, arises beneath the meatus urinarius and pointedly projects forward.

Fig. 39.

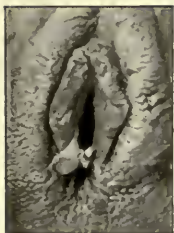

Fig. 40.

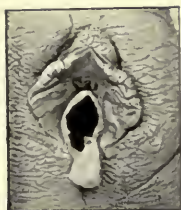

Fig. 41.




Fig. 42.

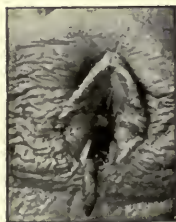


Fig. 43.

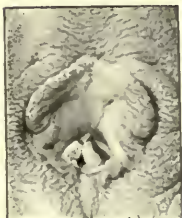

Fig. 44.







Fig. 45.

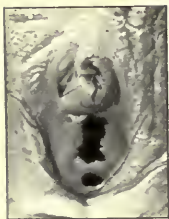

Fig. 46.




Fig. 47.

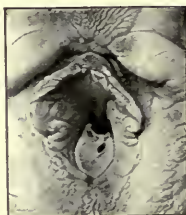

Fig. 48.

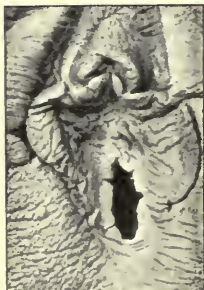


Fig. 49.



## FIGURES 45-49.

### Abnormal Openings in the Hymen. Deflorated Hymen.

FIG. 45.—Circular hymen of a 17-year-old girl, with perpendicular, almost rectangular opening with slightly serrated edges; beneath this and separated from it by a transverse, narrow septum is a second round opening, the size of a lentil. This at first sight might be deemed to have arisen through traumatism, but its congenital origin is demonstrated by the fine and symmetrically fimbriated condition of its edges.

FIG. 46.—Compact hymen of an infant, the opening of which is divided—by a transverse, almost tendinous septum—into an upper smaller, irregularly round, and a lower, larger, circular opening.

FIG. 47.—Wide semilunar hymen, in which, in addition to the ordinary opening, a second smaller one is situated in the left half; this shows attenuated translucent edges, corresponding to an attenuated, translucent, but non-perforated spot in the other half of the hymen.

FIG. 48.—Deflorated circular hymen of a girl, aged 12 years, who died of peritonitis as a sequence of virulent blennorrhoea. The hymen was congested, swollen, and showed four superficial radial tears—2 mm. deep—the free edges of which were besmeared with pus and revealed a distinctly lacerated appearance. The defloration occurred ten days before death, at which time the girl was infected by a man afflicted with gonorrhoea.

FIG. 49.—Wide semilunar hymen of a woman who died in the sixth month of her first pregnancy, of valvular disease of the heart. The anatomical lesion of the hymen ensued in a manner which can be designated as almost typical of semilunar hymens, that is, through—in the present instance deep—tears in both sides of the deepest excavation of the hymenal crescent, so that there result two lateral and a central posterior irregular triangular flap. The last is so frequently preserved because, as a rule, it possesses a special solidity.

## FIGURES 50-55.

### Deflorated Hymens. *Carunculæ Myrtiformes*.

FIG. 50.—Incomplete semilunar hymen with two symmetrical, healed, deep lacerations to either side of the lower part of the median line, giving rise to two lateral and a central flap.

FIG. 51.—Circular hymen with a wide, healed defloration-tear to the right, and a smaller, narrower, higher-situated one to the left, both of which reach to the vaginal wall.

FIG. 52.—Circular hymen with a wide laceration of the right lateral aspect reaching to the vaginal wall.

FIG. 53.—External genitalia of a woman who six months previously was delivered of a full-term child. The entrance to the vagina is much dilated; the posterior commissure cicatricial. Of the hymen there are present but partly triangular or conical-shaped, partly uneven or nodular vestiges. These have persisted after the laceration of the deflorated hymen which occurs during parturition, and are known as *carunculæ myrtiformes*.

FIG. 54.—External genitalia after several parturitions. The vaginal entrance is much dilated, its posterior part smooth, its anterior revealing certain uneven hymenal vestiges—*carunculæ myrtiformes*. The posterior commissure without cicatrices, but much relaxed.

FIG. 55.—Hymen after several parturitions. Originally circular. At present but partly uneven, partly notched, vestiges present. Along the posterior periphery of the entrance to the vagina, at the situation of the former support-pillars formed by the *columna rugarum*, is a plump, cone-shaped protuberance directed inward.

Fig. 50.

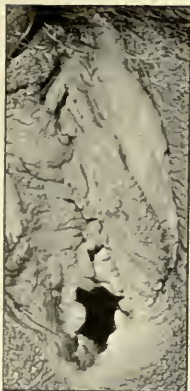


Fig. 51.

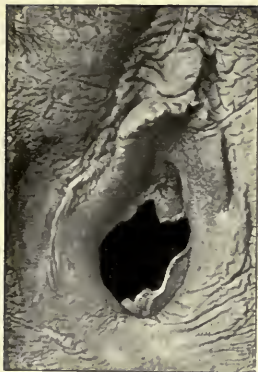


Fig. 52.

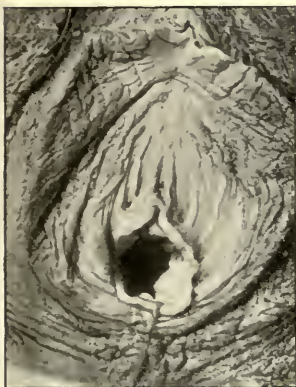

Fig. 53.

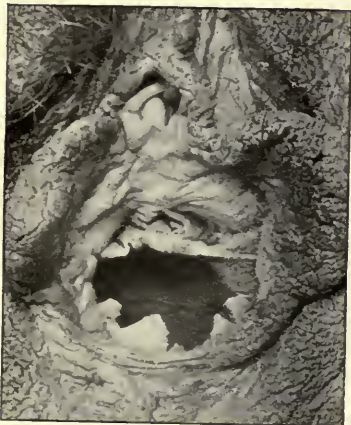

Fig. 54.

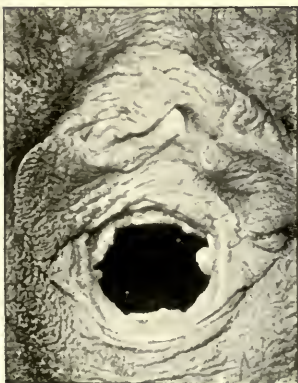

Fig. 55.







Fig. 56.

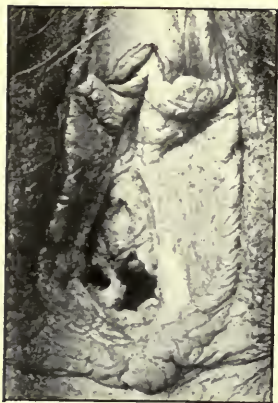

Fig. 57.

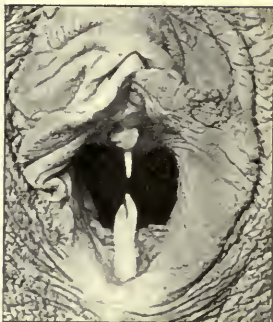
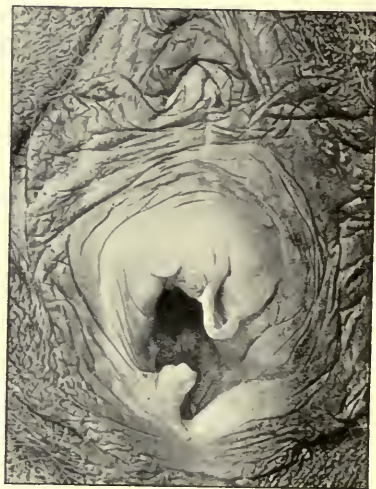
Fig. 59.

Fig. 58.



## FIGURES 56-59.

### Hymen Septus (Divided Hymen) after Defloration and after Parturition.

FIG. 56.—Deflorated hymen septus of an 18-year-old prostitute. The defloration and the subsequent coitions took place through the left, probably originally the larger, opening in the hymen, which shows below and internally a distinct cicatricially healed laceration. To the outer side one notices also two superficial, non-cicatricial depressions. The right opening in the hymen and the septum are intact.

FIG. 57.—Remains of a hymen septus persisting after defloration and after parturition. Of the septum there remain but a shorter upper and a longer lower, narrow, spindle-shaped, peripherally pointed vestige, whereas other parts of the hymen are entirely wanting. In consequence not even indications of *carunculæ myrtiformes* are to be seen on the smooth wall of the dilated vaginal entrance. The woman had probably frequently given birth to children.

FIG. 58.—Deflorated hymen of a woman aged 29 years, who in the fifth month of her pregnancy died of intermeningeal hemorrhage consequent upon rupture of a small aneurysm of the *arteria fossa Sylvii*. Originally the hymen was evidently circular, with a septum running diagonally from the left above to the right below. This at the time of defloration was either ruptured or rather partially torn from the rest of the hymen.

FIG. 59.—External genitalia of an elderly woman who had frequently had children. In the left upper part of the much dilated and smoothed entrance to the vagina one notices a perpendicularly hanging vermiform loop of dense mucous membrane, with a bean-sized perforation, and opposite thereto in the right lower part of the entrance a thick conical portion of similar tissue with wide base, 1 cm. high, projecting into the *ostium vaginæ*. Evidently this was originally a hymen septus with a larger opening to the right and a smaller and higher-situated opening to the left. Of these, the latter persists despite repeated parturitions, whereas the former, partly through the defloration partly through the labors, was irregularly lacerated, or rather torn away from the septum.

## FIGURES 60-62.

### Traumatic Injuries of the External Genitalia.

FIG. 60.—Transverse, fissure-like wound, 1.5 cm. long, of the fossa navicularis. The wound affects the mucous membrane directly in front of the hymen, and, decreasing in size funnel-shaped posterior to the posterior wall of the vagina, penetrates into the depths of the cellular tissue 1.5 cm. The injury befell a child almost 2 years of age, under whom an earthen chamber broke, whereby a fragment penetrated the genitalia. Death resulted from pyemia at the end of ten days.

FIG. 61.—The genitalia of a young married woman pregnant for the first time, who, while putting her room in order, fell, striking the genitalia against the angular edge of a bed. Immediately considerable hemorrhage, which it was attempted to stop by cold applications, but which could not be controlled. After an hour a physician was called, who, instead of immediately sewing the wound, had the woman removed to a hospital, which she entered as a corpse. The legal necropsy revealed a high grade of internal and external anemia, and marked soiling of the lower part of the body with dried blood. Beneath the clitoris a triangular wound with somewhat bruised sides 1 cm. long. It penetrates the mucous membrane and continues funnel-shaped in the submucous tissue a distance of 1 cm. toward the symphysis. The connective tissue of the wound and that in the vicinity are markedly suffused with blood; the injury of a large vessel was demonstrable.

Injuries to this region of the external genitalia are known as dangerous because of the richness of the tissue in large vessels. In the present case the injury was the more serious because of the pregnancy already in the sixth month, and the consequent excessive filling of the vessels. Interference in such cases is urgently indicated, and is most appropriately effected by suturing.

FIG. 62.—The preparation is from a 20-months-old girl who was run over by a tramcar. Various fractures of the ribs; laceration of the lung and the diaphragm; rupture of the liver; suffusion of the peritoneum in the pelvic region without fracture of the pelvis. The perineum torn throughout its length. The vagina with the circular hymen torn from the surrounding parts, lying free in the depths of the funnel-shaped wound of the genitalia. Hymen and vagina otherwise uninjured.

Fig. 60.

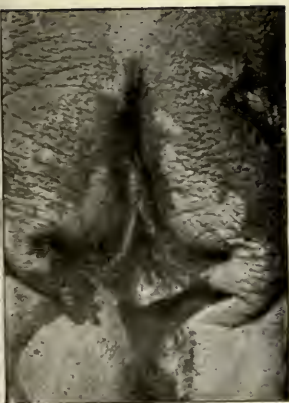

Fig. 61.

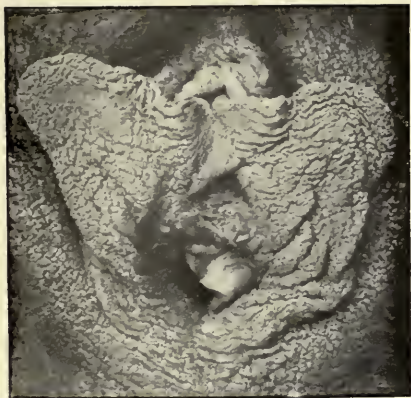

Fig. 62.

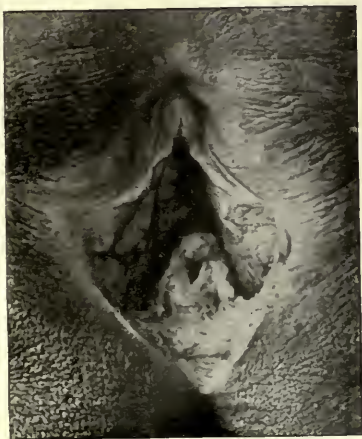






Fig. 63.

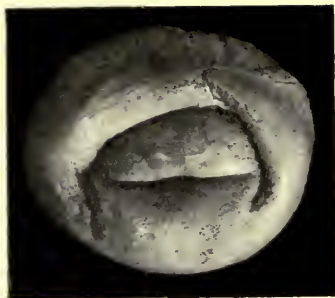


Fig. 64.

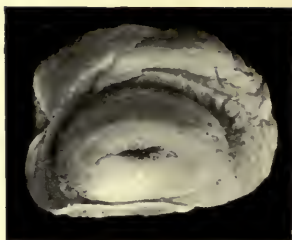


Fig. 66.

Fig. 65.

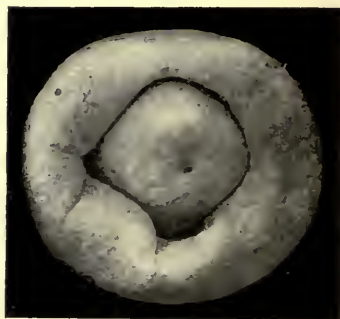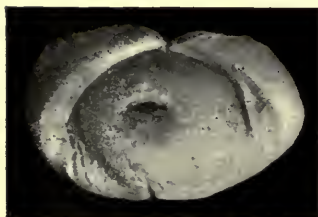
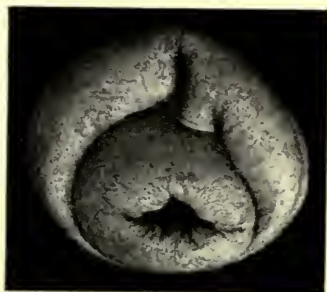


Fig. 67.



## FIGURES 63-67.

### **Condition of the Os Uteri of Virgins and of those who have given Birth to Children.**

The external os uteri of adolescent virgins is, as a rule, a transverse oval opening, or a transverse fissure which gapes but slightly or not at all, and whose edges, as also the cervix itself, are smooth (FIGS. 63, 64, and 65).

In advanced age the appearance frequently changes, in that one then finds a small round opening, whose edges and vicinity, however, likewise appear smooth (FIG. 66). The same condition can also arise through pathologic processes and abortion.

If the woman has already had children, the external os uteri presents itself either as a long, gaping, transverse fissure (FIG. 67), or as a gaping, round opening of such size that one may introduce, as a rule, the fingertip. In both instances the edges are no longer smooth, but more or less deeply and cicatricially notched. In the first-mentioned form these notches are found especially at the end of the transverse fissure; in the second-mentioned form, at other places also about the opening.

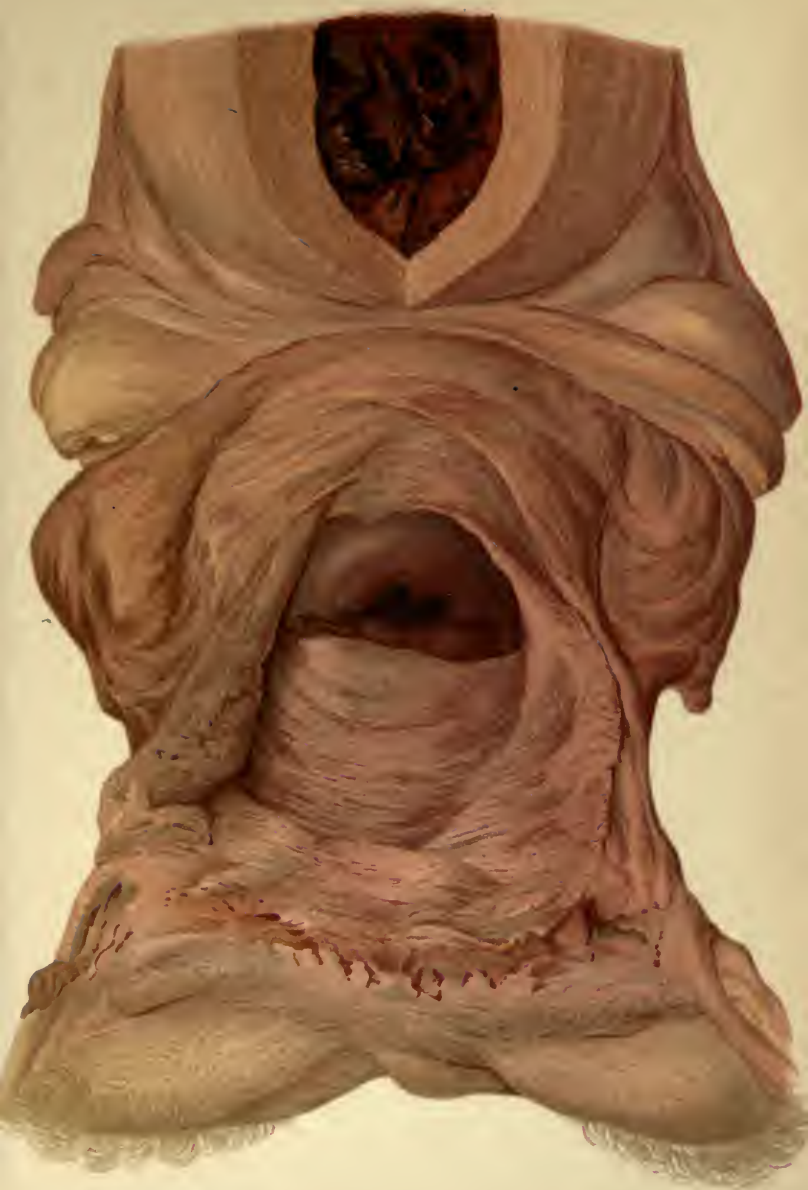## PLATE 1.

### **Cervix and Vagina directly after Parturition.**

M. V., aged 35 years, III-para, wife of a dairyman, was delivered by a midwife, December 11th, at 8 P. M., of a 7-months-old child, and died an hour later with symptoms of great dyspnea and violent coughing. She is said to have suffered for years from cardiac palpitation.

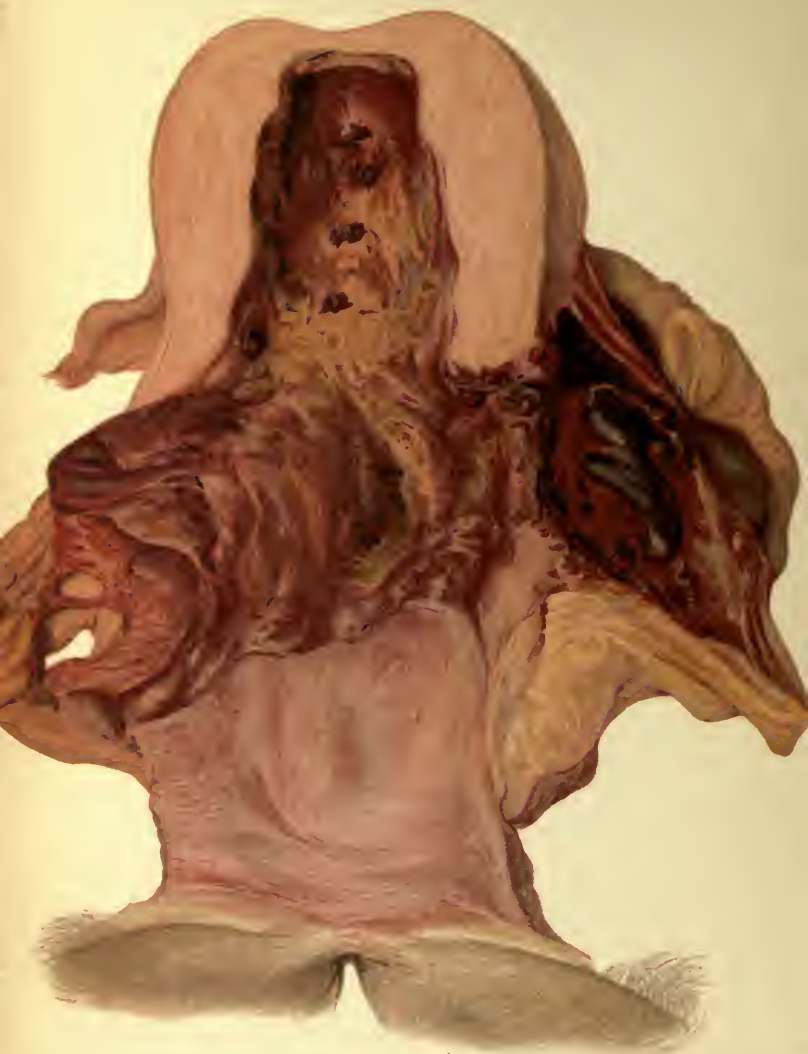The necropsy, performed December 12th, revealed the following: edema of the lungs; stenosis of the left auriculoventricular orifice; recrudescant verrucous endocarditis; and a slight grade of generalized edema. The uterus was as large as the head of a 4-year-old child, well contracted, externally smooth, and very pale. Its cavity was the size of a fist; its inner surface rough, and covered with decidua-shreds and blood-coagula of recent date. The placental site was on the posterior wall of the fundus. The wall of the uterus was 3.5 cm. thick, pale, with gaping vessels. The external os uteri and the cervical canal were patulous for four fingers, markedly swollen, as though edematous, with superficial and deeper fresh radial rents suffused with blood, and numerous older cicatricial depressions, the result of previous labors.

The vagina was wide, moderately wrinkled. The vaginal entrance with numerous superficial tears suffused with blood. The posterior commissure destroyed through cicatrices. Of the hymen, but vestiges of the *carunculæ myrtiformes* present.









## PLATE 2.

### Spontaneous Rupture of the Uterus.

A. H., wife of a house-owner, 38 years of age, took to bed on account of labor-pains on the morning of December 9th, and called a midwife, who declared the labor to be a difficult one and sent for a physician. The latter recognized nothing alarming. As the delivery of the woman, despite severe labor-pains, did not advance, and as her condition during the afternoon suddenly grew worse, the physician was called again. The latter, after consultation with another physician, declared the condition of the woman dangerous and ordered her removal to a maternity hospital. During transportation she died. In the receiving-ward a Cesarean section was performed, resulting in the delivery of a mature dead child, which is said to have presented in the ordinary vertex position.

The legal necropsy, on December 12th, showed that the body externally and internally was very anemic. The abdominal wall was divided by a sutured incision, without reaction, reaching from the umbilicus to the symphysis. In the abdominal cavity were blood-coagula the size of three fists, and in the lower part thereof a large quantity of fluid blood.

The uterus almost the size of a man's head, firm, pale, and smooth, covered with clots. On its anterior surface, an opening with sharp edges, united by interrupted sutures and showing no reaction, running from above downward and through the entire wall of the organ. The cavity of the uterus the size of a fist, filled with blood-clots; the wall of the uterus 4.5 cm. thick. The external os uteri readily patulous for three fingers; much contused. To the left a deep laceration, 12 cm. in length, continuing upward through the entire length of the cervix and completely through its wall, and leading to a large cavity situate between the layers of the uterine ligament. This cavity reaches below to the left internal inguinal ring and extends to the neighboring mesentery; its wall, as also the edges of the laceration of the cervix, appears irregularly shredded.

The vagina wide and uninjured.

The pelvis visibly flattened anteroposteriorly and to the left. The promontory of the sacrum distant 8 cm. from the symphysis. The transverse diameter of the pelvis 12 cm.; the left oblique 11 cm.; the right oblique 12 cm. Distinct funnel-shaped contraction of the pelvic cavity toward the outlet.

The accompanying child is a male, well developed, 52 cm. long, and weighs 3500 grams. The head relatively large, somewhat flattened to the right anteriorly. The anteroposterior diameter of the head 12 cm.; the transverse 9 cm.; the diagonal 13.5 cm.; the circumference 36 cm.

The scalp over the right frontal and parietal bones very prominent and with jelly-like infiltration.

The preliminary opinion ran as follows:

1. Mrs. A. H., in the first place, died of hemorrhage into the abdominal cavity.

2. The latter resulted from rupture of the uterus occurring during parturition at full term.

3. As an instrumental or important manual operation was performed neither by the physician in attendance nor by any one else, the case is evidently one of spontaneous rupture of the uterus.

4. The development of this was occasioned, on the one hand, by the large size of the child, and on the other, and especially, by the marked contraction of the pelvis (flat pelvis).

5. As nothing is known concerning the time of the commencement of the labor-pains and of their continuance prior to the rupture, nor concerning the condition of the woman at the time of the arrival of the first physician, nor of the symptoms developed during and after his presence (or of those recognized by him), preliminarily the question cannot be answered whether or not the difficulty in parturition could have been recognized at the proper time, nor in how far the occurrence of the rupture could have been prevented.

6. Cesarean section was performed on the deceased shortly after her death.

The case was not further investigated by the judicial authorities.



## PLATE 3.

### **Tubal Pregnancy. Rupture of the Sac. Internal Hemorrhage.**

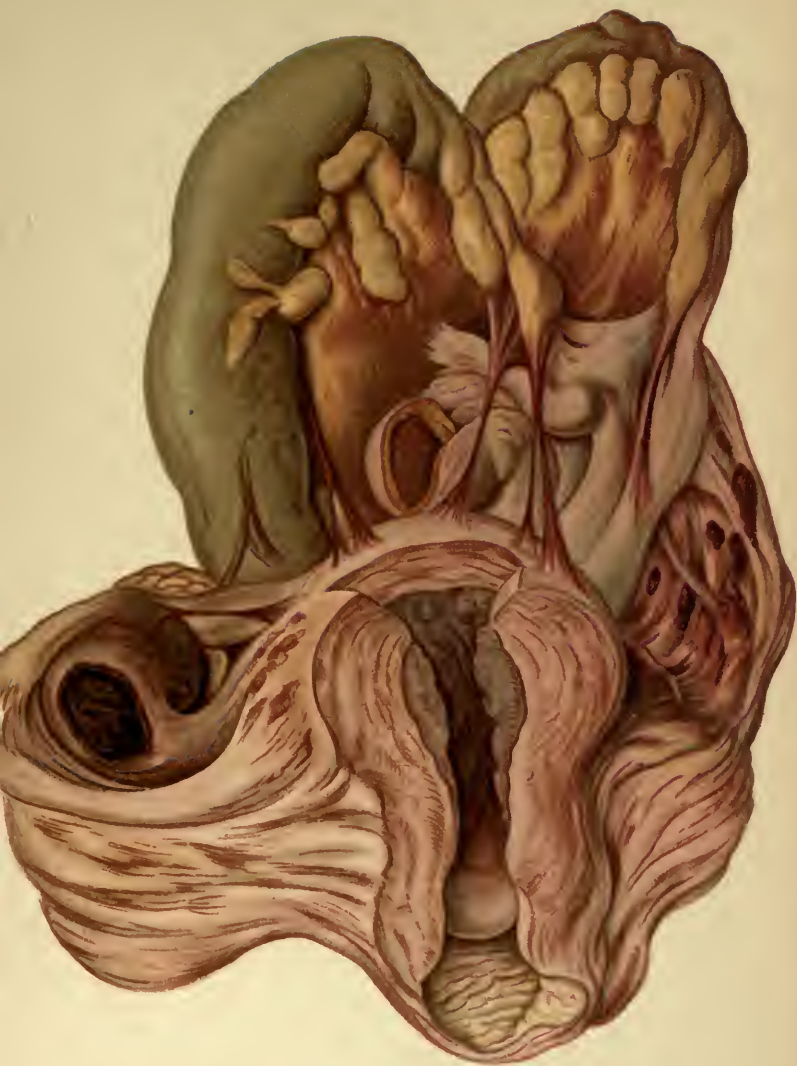Antonia M., aged 35 years, has suffered for the past two years with pain in the abdomen. She has had two children, the last five years ago. Recently menstruation is said to have been irregular. The occurrence of a new pregnancy had not been suspected.

On May 7th, at 8 P. M., the woman complained suddenly of severe pain in the abdomen, vomited five or six times during the night, and had marked rectal tenesmus. A neighboring physician being called recognized a high grade of anemia, cardiac weakness, and rapid loss of strength. At 8 o'clock in the morning the patient died. As there was a supposition of poisoning, a medicolegal autopsy was ordered.

By this there was found externally and internally marked anemia. The abdomen was moderately distended and soft. It contained 2½ liters of partly fluid, partly freshly coagulated blood, which occupied especially the lower abdominal and pelvic cavities. At about its middle the otherwise normal right Fallopian tube becomes dilated to form a sac the size of an apple, which on its anterior surface shows a wide perforating longitudinal rent almost 2 cm. in length, from which blood-coagula and ruptured chorionic villi project. The entire sac is surrounded by huge blood-clots, which are connected with those contained within the abdominal cavity, and in which, on careful examination, there is found directly above the point of rupture, in an unbroken amniotic sac, an embryo 2 cm. in length. The latter is bent in a scaphoid manner, and still shows vestiges of the germinal fissures and apparently of the abdominal cleft, but in addition already articulated extremities, on which we may recognize the still adherent fingers and toes. It belongs, therefore, to the middle of the second month.

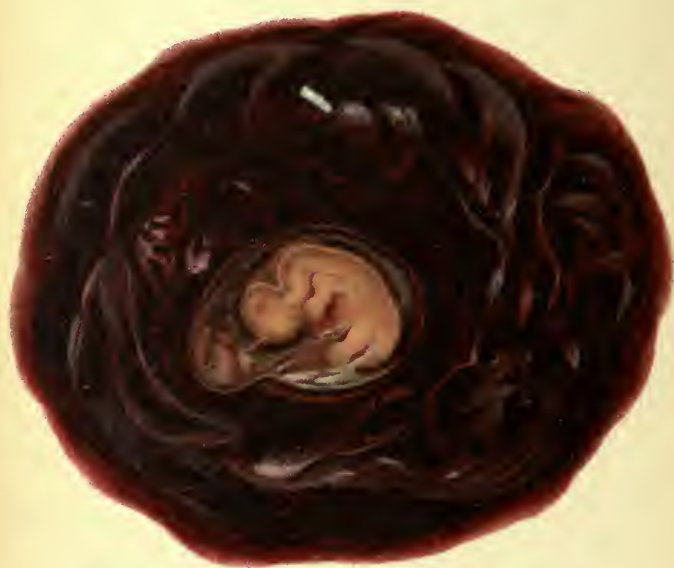The further investigation of the genitalia revealed numerous cord-like adhesions of the posteriorly displaced left tube with the posterior wall of the uterus and the neighboring intestines, and a large corpus luteum (corpus luteum verum) in the *left* ovary. There had, therefore, occurred a so-called "migration of the ovum" from the left to the right. This was induced by the adhesions and flexions of the left tube which retarded the entrance of the ovum into the (left) tube, and which, also preventing it reaching the uterus, caused it to remain in the tube, and there further develop.

Worthy of mention are further the visible enlargement of the uterus and the marked swelling and hyperemia of the uterine mucous membrane (decidua vera),—phenomena regularly observed in cases of extra-uterine pregnancy.









#### PLATE 4

represents the embryo about one and a half months old found within an uninjured amniotic sac among the blood-clots of the tubal pregnancy illustrated in Plate 3, where its peculiarities are described more in detail.

## FIGURE 68.

### Fatal Hemorrhage from Retention of a Portion of the Placenta.

W. M., aged 39 years, the wife of a locksmith, was delivered of her third child January 8th, at 12.30 o'clock at night. The labor was easy. The placenta was delivered by a midwife, who asserted that she examined but observed nothing unusual about it, and therefore laid it aside. The hemorrhage after delivery continued, but a physician was not sent for until noon. For a long time one was sought in vain, who, when he arrived, found the woman excessively anemic and already collapsed. He diagnosed atony of the uterus, introduced a tampon, and had the woman transferred to a maternity hospital, where immediately after her admission, before she could be examined, she died at 3.45 o'clock in the afternoon.

The body externally and internally was remarkably anemic; the external genitalia and the surrounding parts covered with fluid and coagulated blood.

The rather firm uterus, the size of a man's head, contained a large quantity of recent blood-coagula, which were especially firmly adherent to the fundus, and which when removed revealed the placental site. To the upper part of this there was firmly adherent a pear-shaped portion of the placenta with dependent apex, 6 cm. long and 3 cm. wide.

The other findings were such as were to be expected directly after parturition; the uterine vessels were, however, almost entirely empty and the wall of the uterus very pale but firm.

The opinion was deduced that the deceased died shortly after parturition of hemorrhage from the genitalia; that this was caused by the retention of a large portion of the placenta, and that the removal of this portion of placenta at the proper time, which the existing contraction of the uterus rendered difficult, would have prevented the hemorrhage.

The culpability of the midwife consisted: 1. In that she neglected to carefully examine the placenta, whereby the absence of such a large portion of it could not have escaped her attention; 2. In that she laid aside the placenta before the arrival of the physician, so that the latter could not inspect it; and, 3. In that medical aid was not summoned until the hemorrhage had persisted for hours and had assumed a critical character.

Through the portion of retained placenta in the accompanying illustration a sagittal section has been made.

Fig. 68.

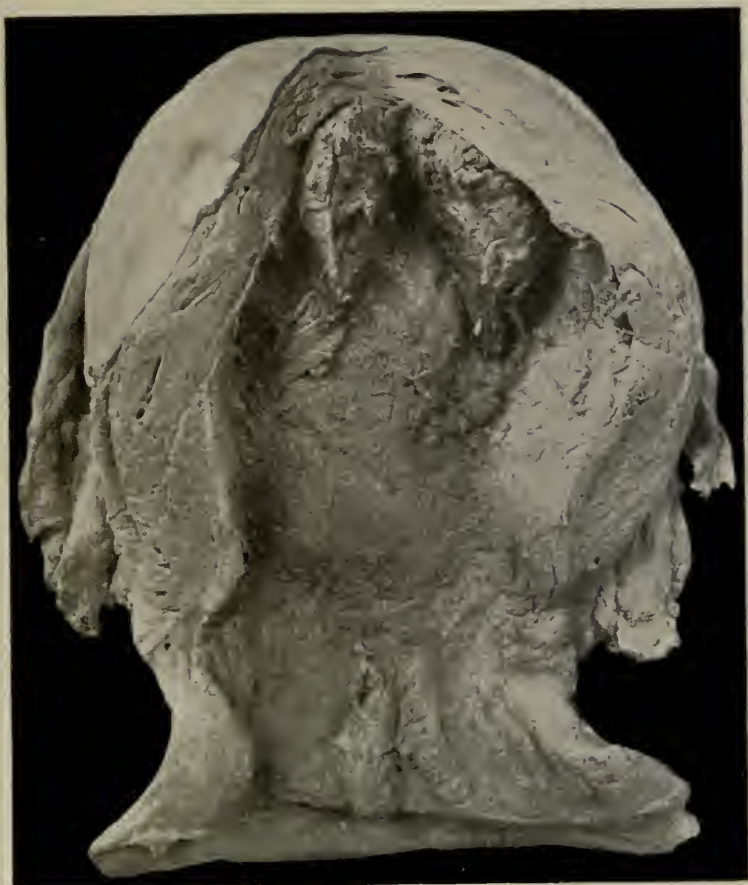
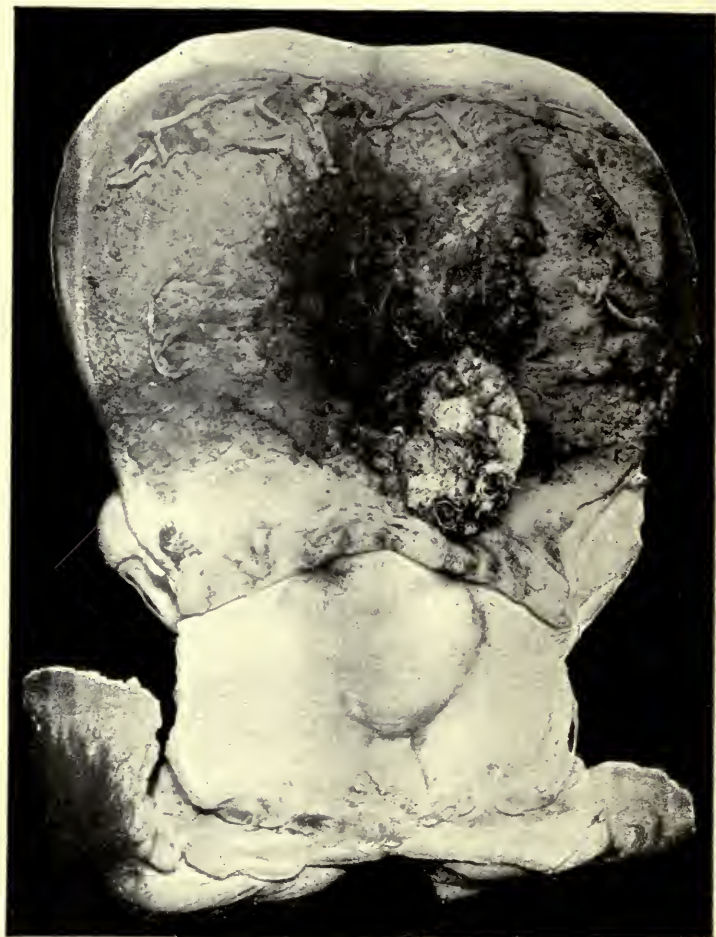




Fig. 69.



### FIGURE 69.

Another form of retention of a portion of the placenta with consecutive hemorrhage, occurring four hours after an otherwise normal labor, is illustrated in Fig. 69. The site of the placental insertion was on the posterior wall of the uterus, and its lower border was scarcely one finger's breadth above the internal os uteri. The retained portion of the placenta was covered with a large blood-clot reaching into the vagina. After the removal of the latter the portion of the placenta was found to be almost as large as a goose-egg, its lower third intimately adherent with the lower part of the placental site, its other two-thirds projecting flap-like into the dilated vagina, which had a width of four fingers.

In this case also the midwife had not properly inspected the placenta, and, in addition, had left the woman before the lapse of the prescribed four hours.

## FIGURES 70, 71.

### Two Uteri in the Very Earliest Stages of Pregnancy.

FIG. 70.—The preparation is from a married woman, aged 35 years, who killed herself by jumping from a second-story window. She had frequently had children, and thought herself again pregnant, as she had not menstruated at the last expected period.

There were found, as the cause of death, fractures of ribs and various ruptures of the abdominal organs, with internal hemorrhage. The uterus was uninjured, the size of an orange, thick-walled and contained in its slightly dilated cavity some freshly coagulated blood, demonstrable also in the cervix and in the vagina. The mucous membrane, after irrigation, was found irregularly swollen, pale violet, as a decidua vera, dilated—to the right and above—to form a sac the size of a bean. This latter was ruptured in the direction of the greatest convexity, filled with recent blood-clots, and revealed a finely rugose inner surface.

Despite careful examination of the blood-clot neither an ovum nor a part thereof could be discovered. There can, however, scarcely be a doubt that the sac was that of a decidua reflexa, which contained an ovum in the earliest period of development, and, further, that the violent concussion occasioned by the fall led to a rupture of the decidual sac and a consequent extrusion from it of the therein contained ovum either *in toto* or likewise injured, and that this latter was carried off with the blood-clots. The right ovum contained a bean-sized corpus luteum, with wide pale yellowish margin and violet jelly-like contents.

FIG. 71 is from a woman, aged 35 years, who died suddenly in consequence of mitral incompetency and pulmonary edema. Menstruation had been absent during the past two months.

The necropsy revealed a pregnancy at the end of the *first or the beginning of the second month*. The uterus is the size of an orange, rather thick-walled, and contains an uninjured ovum attached to its posterior wall. This, after opening of the decidua reflexa, is found the size of a walnut, completely covered externally with regularly and closely arranged chorionic villi. After slitting open the chorion and the amnion one sees the embryo, about 2 cm. in length, to the left in breech presentation. The latter is fastened to a short, relatively thick umbilical cord proceeding from the posterior wall of the ovum; it is markedly scaphoid in shape, shows as yet no ossification, and reveals, in addition to oral and nasal apertures already joined to form one cavity, the genital clefts of the neck, the abdominal cleft, the umbilical vesicle, and the as yet but articulate stumps suggestive of extremities,—findings which indicate that the embryo belongs to a very early period and that it has scarcely or but slightly passed the first month of pregnancy.

Fig. 70.



Fig. 71.

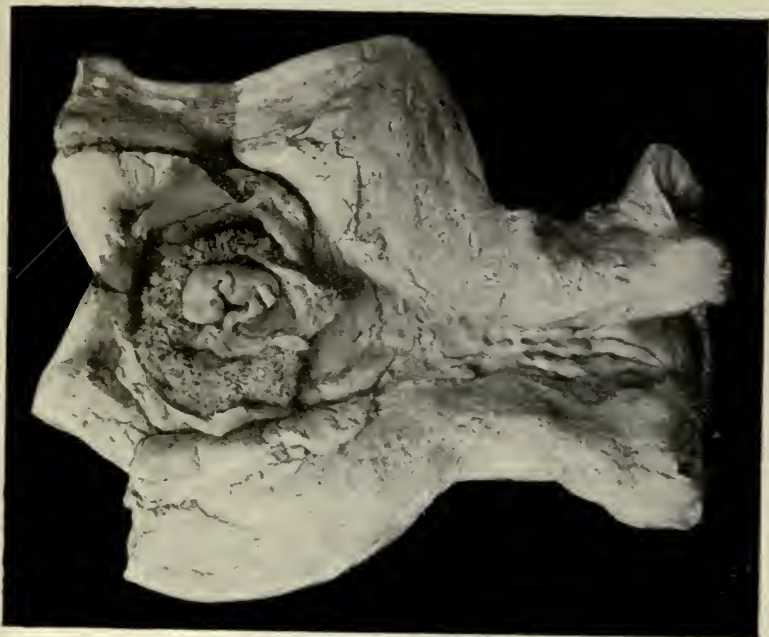





Fig. 72.

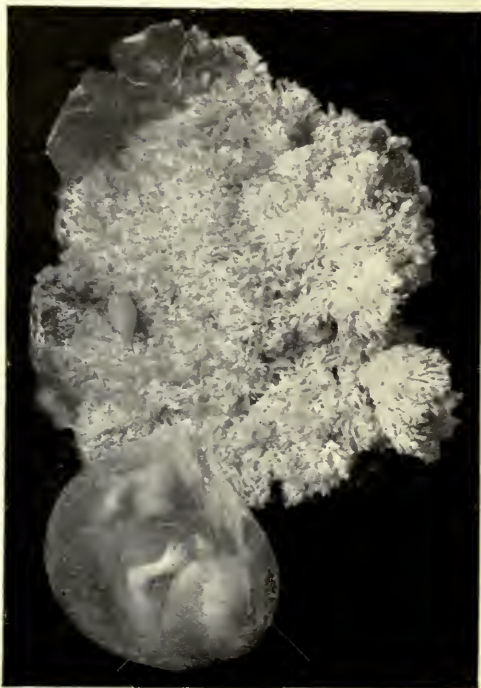
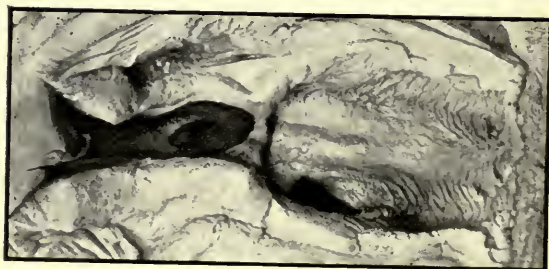


Fig. 73.



## FIGURES 72, 73.

### Fig. 72.—Human Ovum of the Eighth or Tenth Week.

The ovum, first separated from the blood-clots by continued irrigation and then opened, is *in toto* the size of a goose-egg, and shows above and to the left as its external covering vestiges of the decidua reflexa. The incised chorion situate beneath is externally completely symmetrically villous (chorion frondosum), and reveals as yet no placenta formation. From the smooth inner surface of the incised chorion the unopened diaphanous amniotic sac, containing the embryo in a clear, watery-looking fluid, protrudes. The embryo is about 5 cm. in length, and shows as yet no differentiation of the sex, but already separated fingers. The genital clefts and the abdominal fissure are already closed. The umbilical cord is thick, about 2 cm. in length; from its root on the inner surface of the chorion there proceeds, between the latter and the external surface of the amnion, a thin filament, about 3 cm. in length, which ends in an oval, pea-sized, watery-looking vesicle,—the umbilical vesicle. In the illustration this is represented as protruding through a rent in the chorion to the right and below.

---

### Fig. 73.—Rupture of the Vagina through Coitus or by the Finger.

A coachman had sexual intercourse with a 19-year-old servant, in a stable, after he had previously examined her with his finger. On the way home the girl became affected with pain in the genitalia and rather severe hemorrhage. The same day she betook herself to the general hospital, where a rupture of the vagina in its upper part was recognized and an iodoform tampon introduced. Death ensued six days after the injury, with the phenomena of sepsis.

The necropsy revealed general sepsis and septic pleuritis as the cause of death.

The uterus somewhat enlarged, smooth, with cicatricially notched os uteri. The uterine cavity slightly dilated, containing a brownish blood-coagula representing a cast thereof. The mucous membrane softened, injected, with isolated lentil-sized blood-extravasations; everywhere smooth.

In the vault of the vagina, beginning to the right posterior to the posterior lip of the cervix and coursing obliquely to the right and below, there is a slit-like tear of the mucous membrane, 4 cm. in length, reaching to the submucosa. It has rather sharp edges joining in an acute angle, and a flat, funnel-shaped, irregular base, deepening above and reaching to beneath the peritoneum, covered with discolored blood-

clots. The edges and base are infiltrated with blood; the mucous membrane in the inner part darkly congested and pervaded with small fading blood-extravasations. In the upper part of the left vaginal wall near to the fornix, affecting merely the upper layers of the mucous membrane, there is a semilunar tear 8 mm. long and 1 mm. wide, with its convexity to the front and above. Its edges are sharp, and approach to form an acute angle; its base discolored, and the immediate vicinity slate-colored.

Regarding the latter finding, which reveals distinctly the impression of a finger-nail, the opinion was expressed that the laceration of the vagina in all probability was not induced by the coitus, but rather by rough introduction of the finger.

---

### FIGURE 74.

#### **Acute Sepsis following Abortion. Punctured Wound in the Fornix of the Vagina.**

Having the day previously visited a midwife, A. Th., aged 30 years, became ill November 8th, with vomiting, diarrhea, and colic, and died the evening of the same day.

The necropsy revealed a high grade of puerperal sepsis and commencing peritonitis.

The uterus is the size of a child's head, and contains discolored fluid. The decidua vera is discolored, and shows abundant shred-like disintegration. Above the internal os uteri, attached to the posterior wall of the uterus with a placenta 5 cm. in diameter, there is a discolored, lacerated ovum, and from the middle of the placenta there hangs, as a loop, a discolored filamentous umbilical cord which leads to an excessively putrid and disintegrating embryo, about 6 cm. in length. The latter is situate in the dilated cervix, patulous for two fingers, and reaches to the externally cicatricially notched os uteri. One may recognize the disassociated cranial bones, and higher upward the ribs and the bones of the lower extremities.

In the apex of the right vault of the vagina, about 2.5 cm. from the external os uteri, there is a round opening about 2 mm. in width, with rather smooth edges, surrounded by an area of violet discoloration 3 mm. in width, whose base is suffused with blood. From this one may follow a hemorrhagic canal of the same width which runs from below upward and rather from without inward, through the mucous membrane to the submucous connective tissue, where it ends in a rather sharply defined suffusion larger than a lentil.

This injury is evidently a punctured wound produced with a wire or sound-like instrument, and this discovery, together with the circumstances of the case and the other findings of the necropsy, permit of no doubt that abortion by puncture of the membranes was attempted.

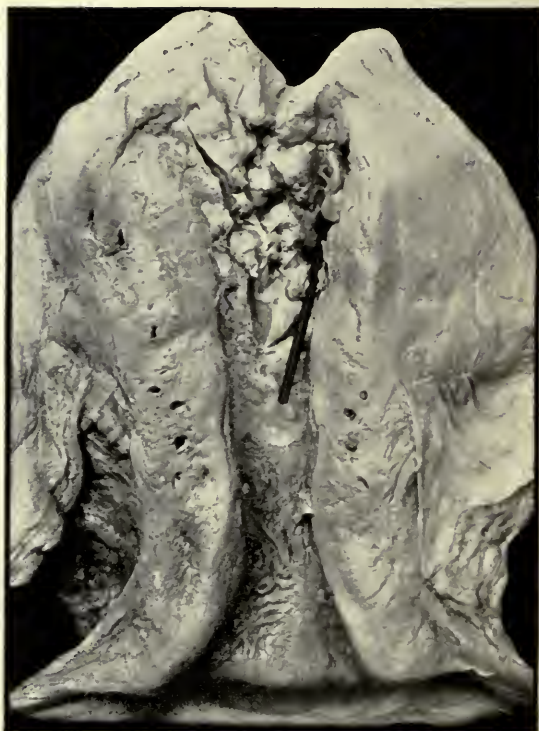
Fig. 74.

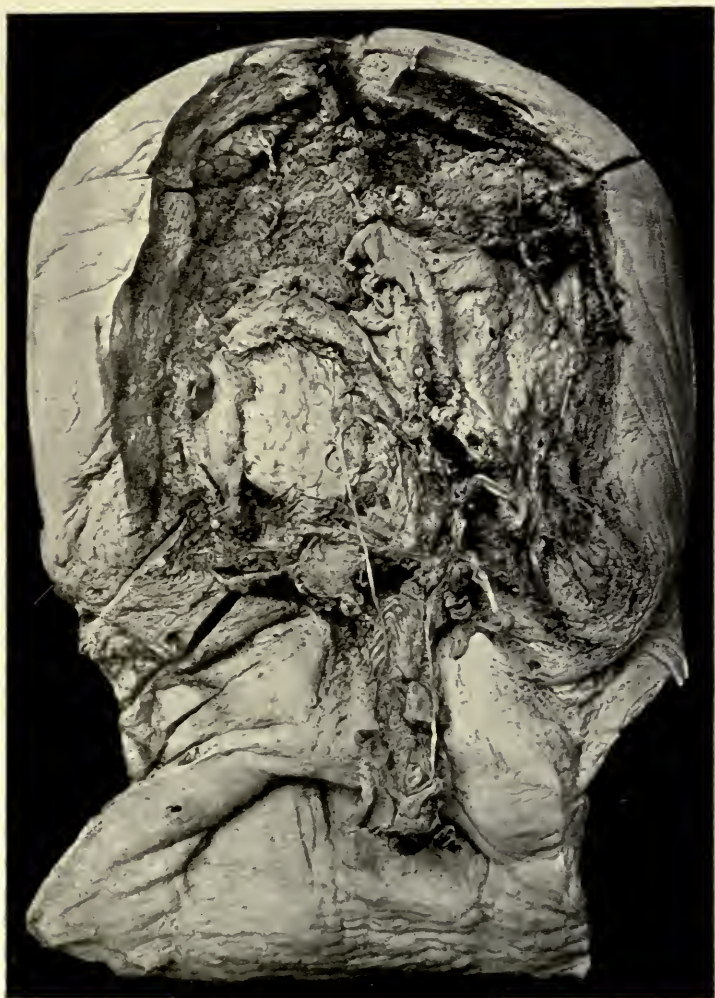





Fig. 75.



## FIGURE 75.

### **Abortion Induced by a Probe-like Instrument ; Perforation of the Posterior Wall of the Uterus.**

Uterus of a 29-year-old multipara, who died after fourteen days' illness, consisting of hemorrhage from the genitalia, fever, and abdominal pain.

The necropsy revealed endometritis and septic peritonitis.

The uterus larger than a fist, empty, with distinct placental site. The cervix patulous for the index finger, not lacerated, showing cicatricial notches of the external os uteri.

On the posterior wall of the uterus to the left and above there is a bean-sized irregular opening covered with pus, which leads into an equally wide canal with softened walls, likewise covered with pus. This penetrates the entire wall of the uterus anteroposteriorly from below upward, and ends on its posterior surface in an irregular, triradiate, foramen-like opening, with limbs 1.5-2 cm. in length, occluded with a fibrinopurulent exudate.

This is manifestly a case of abortion induced by the introduction into the uterus of, and the perforation of its walls by, a probe-like instrument.

## FIGURE 76.

### **Abortion Induced by Rupture of the Membranes of the Ovum. Slit-like Laceration above and below the Internal Os Uteri.**

K. M., aged 20 years, who had aborted once, for the purpose of producing another abortion was "operated" upon three times by a surgeon, who each time is said to have introduced a surgical instrument into the genitalia, which procedure each time, but especially the last—June 15th—caused pain. The abortion ensued during the night of the 15th–16th of June. A 2-months-old embryo was delivered, which was shown to and preserved by a midwife who was summoned to the case. On the 18th, because of fever and abdominal pain, the patient was brought to the hospital, where she died on the 23d.

The legal necropsy revealed puerperal sepsis as the cause of death, and in the uterus the three wounds illustrated in the cervical portion thereof. The first of these wounds is situate directly above the internal os uteri, the second to the left at the internal os uteri, the third on the posterior wall of the cervix to the right of the median line between the internal and external os uteri. All three wounds are irregular longitudinal slits 1–1.5 cm. in length, with somewhat jagged edges, and a wedge-shaped base—flat above—deepening 3–5 mm., discolored and covered with pus. From the lower end of the lowest-situated slit there projects a discolored shred of mucous membrane about 1 cm. square.

The physician denied the charge, but under the overwhelming weight of the proofs was nevertheless condemned. To all appearance a hook-like instrument was used, the employment of which would explain the recognized detachment of the mucous membrane hanging as a flap from the lowermost wound.

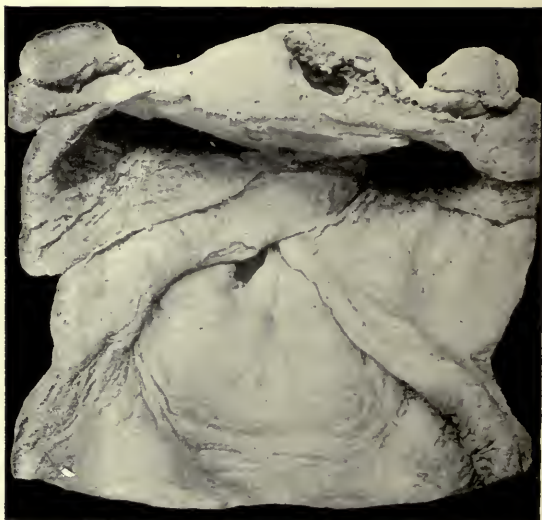
Fig. 76.

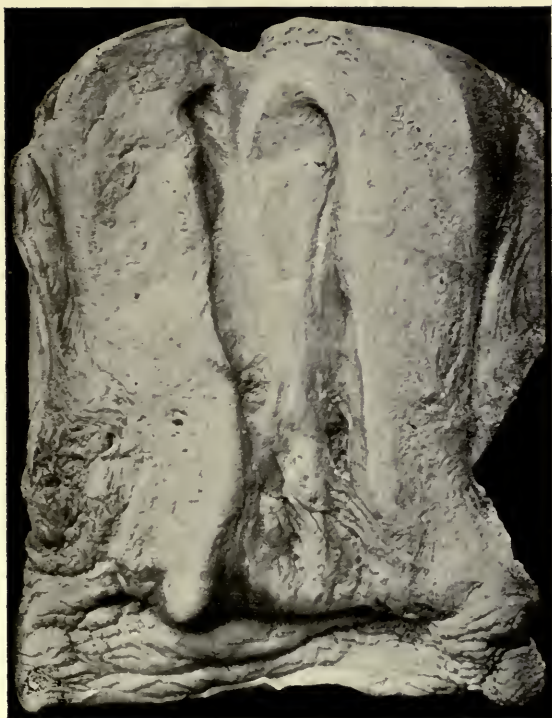





Fig. 77.



## FIGURE 77.

### **Abortion Induced by Injections. Perforation of the Fornix of the Vagina and the Fundus of the Uterus.**

The 39-year-old wife of an inn-keeper, who had already given birth to seven children, and who considered herself again pregnant in the second month, betook herself on September 23d to an advertised midwife to have an abortion performed. The latter had the woman lie down upon the floor and brought a glass enema-syringe filled with a clear fluid, to which was attached a long, thin bony nozzle. This she introduced so far into the genitalia of the woman that the latter suffered intense pain, it seeming to her that the syringe must have penetrated to the stomach, where she thought she felt the entering fluid. For this operation the midwife demanded 30 marks, but was content to receive 15 marks. With effort the woman dragged herself home; she vomited on the way, and was obliged to immediately take to bed and call a physician. From the latter she originally concealed the true condition of affairs, and only after violent symptoms of peritonitis developed, on October 3d, confessed all, among other things that during the night of the 24-25th she passed a blood-clot which was thrown into the closet. Death ensued October 11th, after the imprisoned midwife had acknowledged having given the woman merely *pro forma* an injection of warm water into the vagina.

In the posterior fornix of the much dilated, smoothed-out, and thin-walled vagina there was found a shredded, irregular, slit-like opening agglutinated by pyofibrinous exudate. This opening communicated with Douglas' cul-de-sac, where its edges were already rather firmly adherent to portions of the intestines. In addition, there was in the fundus of the uterus an opening the size of a half dollar, with discolored, softened, shredded edges, through which from the uterus one might enter the abdominal cavity, and the edges of which were likewise, by means of an inspissated layer of pyofibrinous exudate, adherent to the intestines. The opening in the vault of the vagina was without doubt caused by the perforation of it by the inserted instrument, and very probably also the perforation in the fundus of the uterus; but it must be acknowledged that the latter may have subsequently arisen or become enlarged through septic softening.

## FIGURE 78.

### Divulsion of the Cervix from the Uterus. Abortion.

Uterus of a servant, aged 26 years, who on May 11th, on account of pretended chills and fever lasting during the previous six days, was admitted to the hospital, where a whitlow on the distal phalanx of the index finger was recognized and in consequence pyemia diagnosed. There was no suspicion of pregnancy, as the girl asserted that her menses had always been regular—the last time April 25th. Death occurred on May 13th, and it was only at the pathological examination that septic peritonitis and injury of the uterus were discovered, and in consequence subsequently the legal necropsy resorted to.

The uterus, illustrated in full size, is as large as a fist, its cavity dilated to almost the size of an orange, empty, its inner wall covered with discolored decidual remains and blood-clots, uneven; in the upper part of the posterior wall the placental insertion— $3\frac{1}{2}$  cm. wide—demonstrable. The cervix, about 2 cm. in length, is, with the internal and external os uteri, torn away from the left part of the uterus and the left vault of the vagina, whereby a large opening patulous for two or three fingers is formed, through which from the vagina one may directly enter the cavity of the uterus. The edges of this opening are irregular, partly shredded, discolored, and somewhat softened; otherwise unaltered.

The divulsed cervix is displaced to the right, its canal patulous for a moderately stout sound, the external os uteri oval transverse, somewhat more than a half centimeter long, slightly open, and entirely smooth.

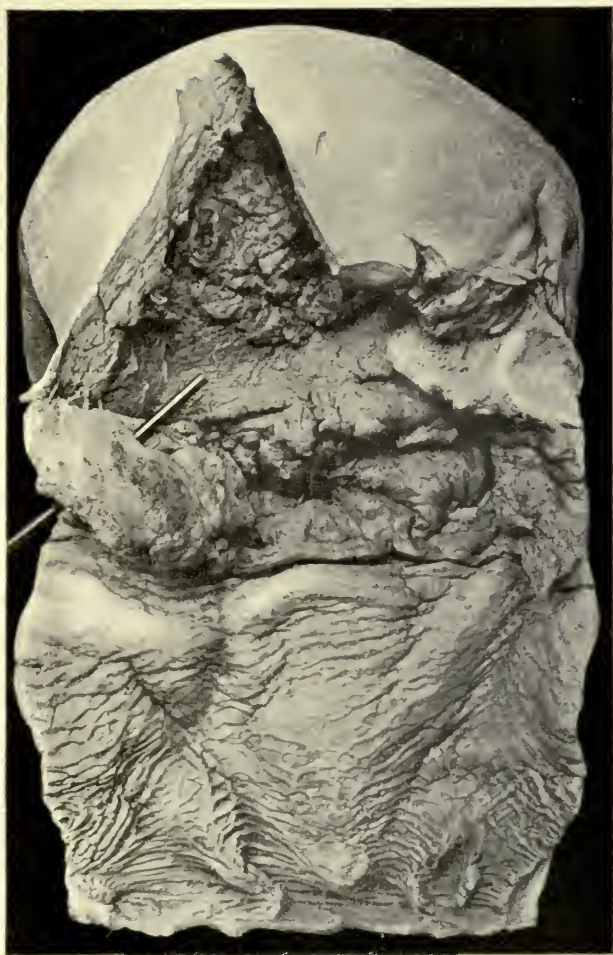The vagina is markedly wrinkled, its entrance without cicatrices. Of the hymen, still considerable remains present.

On the left index-finger a superficial cicatrizing whitlow, without suppuration.

The opinion was expressed that the deceased was in the third month of pregnancy (already distinct placental formation), and that a few days prior to her death she had given birth (aborted) through the large irregular opening in the left vault of the vagina. This opening, looking as though perforated, was produced by the forcible introduction of a blunt though rather narrow and long instrument, which may have been a violently inserted finger. To all appearances the introduction of the instrument—or of the finger—and the consequent laceration had as their object the production of an abortion, and the manner of its execution permits of the inference that it was performed by a lay-person.

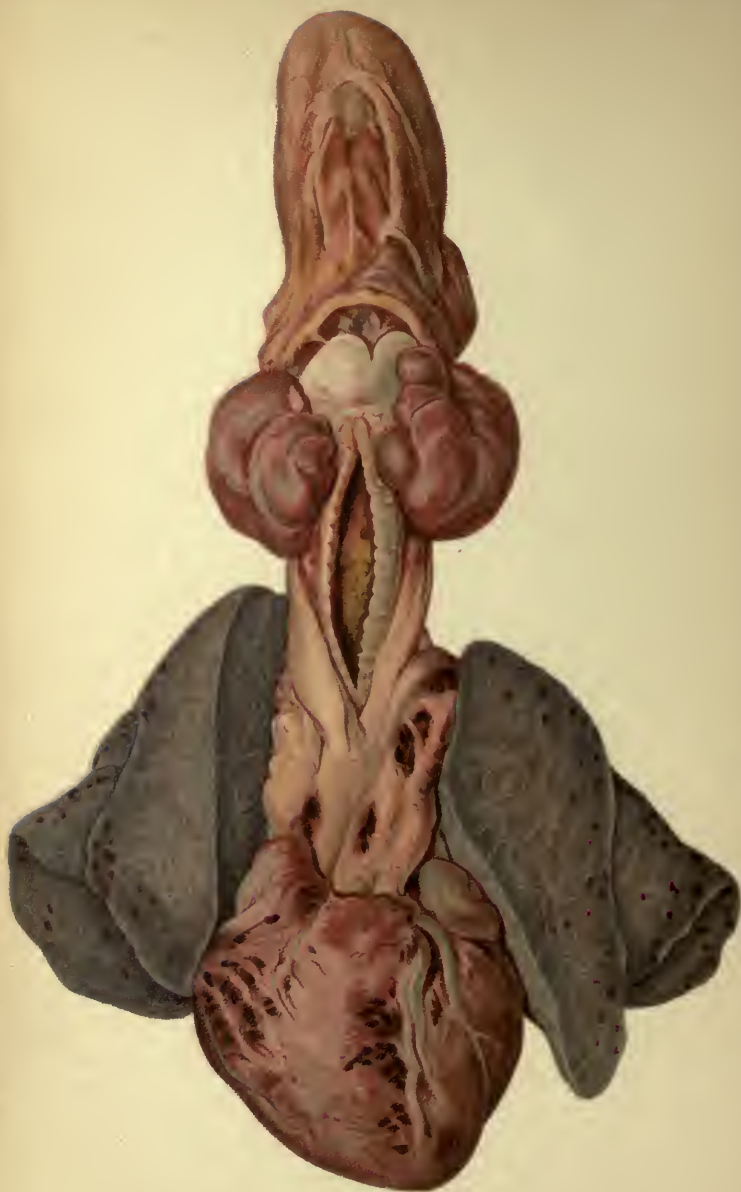The case remained unexplained.

Fig. 78.









## PLATE 5.

### **Respiratory Organs and Heart of a Full-term Child who died during Birth of "Fetal Suffocation" from Premature Respiration.**

Probable compression of the umbilical cord.

Aspired meconium in the respiratory passages.

In the heart and lungs numerous ecchymoses of suffocation.

The lungs themselves still situated in the posterior part of the thoracic cavity, but nevertheless somewhat enlarged, symmetrically very dark violet, contain much blood and are heavy, completely void of air, of fleshy consistency; aspirated meconium in the larger bronchi.

These are the usual findings after fetal suffocation, and permit, as a rule, the diagnosis of such a process. Extra-uterine such a complex of signs can only occur when the child—immediately from the maternal genitalia—is deposited within the birth-fluids (as may occur after delivery over a vessel), but otherwise only when the child immediately after birth comes to lie with its face in a layer of meconium or other of the birth-fluids.

## FIGURE 79.

### **The Epiphyses of the Lower Extremity and of the Humerus of a Mature, Newly Born Child.**

In determining whether or not a newly born child brought to necropsy is to be looked upon as mature, in addition to ascertaining the weight, length, and general development, it is of importance to determine the condition of the centers of ossification in the epiphyses of the bones forming the knee-joint, as also those in the tarsal bones.

The accompanying illustration of a longitudinal section through the leg of a mature, well-developed child, who died during birth of asphyxia, shows the conditions referred to in half size.

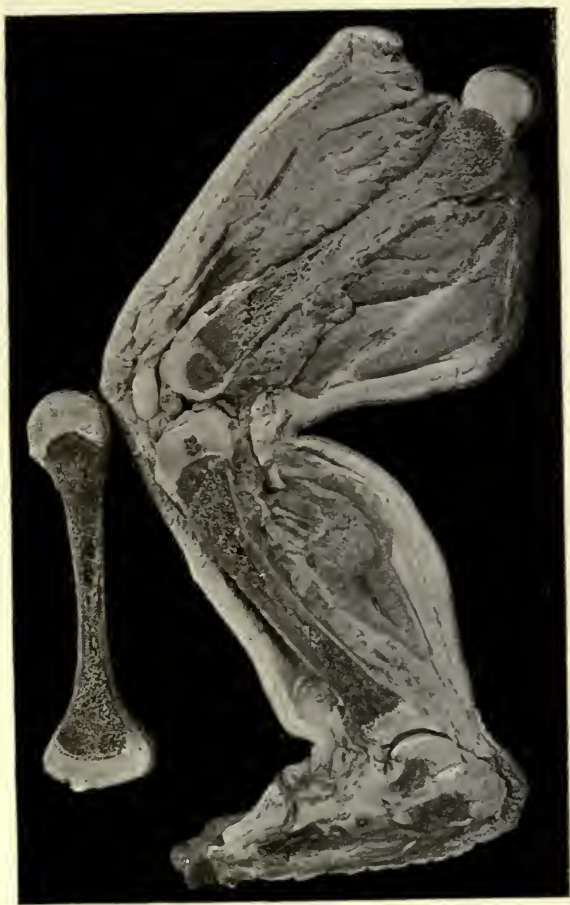The upper epiphysis of the femur is still completely cartilaginous; the lower, on the other hand, reveals within the epiphyseal cartilage a pea-shaped center of ossification, which on section is seen as an almost spherical disk, 6 mm. in width, sharply circumscribed by white cartilage.

The upper epiphysis of the tibia shows a center of ossification one-half the size of this, whilst the lower epiphysis as yet possesses none. The earliest indication of the first-mentioned center appears during the ninth, that of the second not before the beginning of the tenth lunar month.

In the os calcis one notices an oval center of ossification 16 mm. from before backward, 8 mm. from above downward; in the astragalus a semi-lunar center with the concavity upward, 12 mm. long and 6 mm. high; and in the os cuboideum a round center with a diameter of 3 mm. The last-mentioned develops, as a rule, not until the second half of the tenth lunar month; the first before the seventh lunar month; so that at the time of viability (28th to 30th week) the center in the os calcis is already the size of a pea, while that in the astragalus is half as large as a pea.

In the upper end of the humerus, at the end of normal pregnancy, there is only exceptionally, and in strong children, a center the size of a hempseed, as is indicated in the accompanying case.

Fig. 79.







## FIGURE 80.

### **Epiphyses and Posterior Tarsal Bones of a Premature, and of a Full-term Newly Born, and of a 3½-Months-old Child.**

I. Vertical Row. An eighth-month premature female child, 44 cm. in length, weighing 1760 grams. The upper epiphysis of the humerus, the upper and lower epiphyses of the femur, and the upper epiphysis of the tibia show as yet no indication of centers of ossification. In the astragalus, however, a pea-sized, and in the os calcis a bean-sized, center.

II. Vertical Row. A full-term female child, 50 cm. in length, weighing 3030 grams. Of the first-mentioned epiphyses none but that of the lower end of the femur possesses a center of ossification, and this is about the size of a pea and has a diameter of 5 mm. The bony nucleus in the astragalus is already the size of a bean; that in the os calcis has the size and shape of a sagittally placed almond.

III. Vertical Row. 3½-months-old child, 59 cm. in length. All the epiphyses contain centers of ossification; that of the upper end of the humerus contains a pea-sized one in the head and an indication of a second in the greater tuberosity; that of the upper end of the humerus, one the size of a poppy-seed in the head; that of the lower end of the femur, an oval one 11 mm. long and 8 mm. wide; that of the upper end of the tibia, a transverse one with a longitudinal diameter of 1.3 cm. and a vertical diameter of 0.6 cm. The nucleus in the astragalus is 1.4 cm. in length and 0.6 cm. in width (height); that in the os calcis, 1.6 cm. in length and 0.8 cm. in width.

Fig. 80.

I

II

III

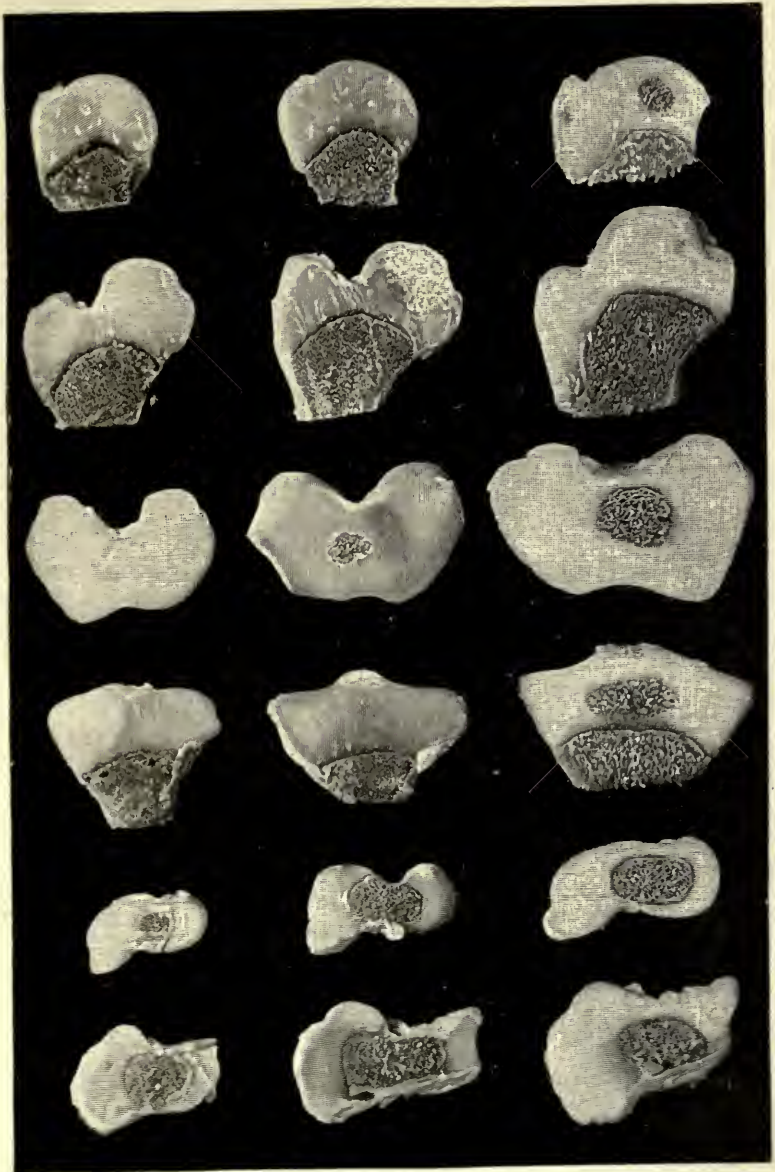






Fig. 82.

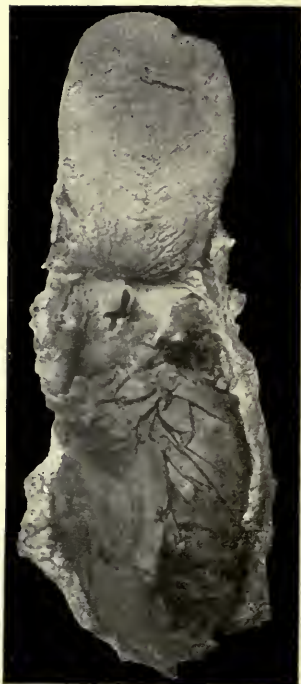
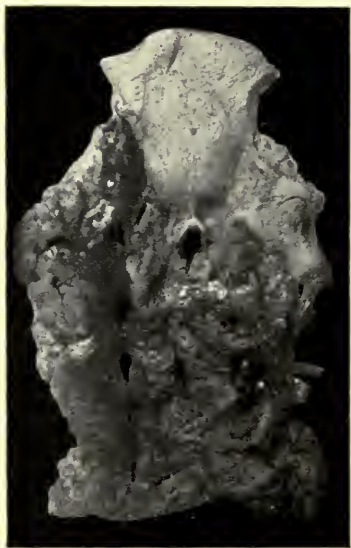


Fig. 81.



## FIGURES 81, 82.

### Suffocation of the Newly Born by Intentional Obstruction of the Pharynx.

The killing of newly born children by the introduction through the mouth of a finger and the plugging by it of the fauces or the pharynx, or by their obstruction with other objects, such as bits of cloth, earth, and the like, is one of the not uncommon methods of infanticide. Externally such killings are not always recognizable, but internally we may distinguish them by the laceration of the fauces or the pharynx which is almost always present, or by the discovery of the obstructing object, or by both of these together.

Figs. 81 and 82 illustrate two instances of the latter kind.

FIG. 81.—P. G., a maid, asserted that she gave birth to her full-term child in a closet. It is said to have fallen into the basin, from which she immediately withdrew it, but it gave no indication of life. She then placed it in a chest in a closet containing ashes and coal-dust and covered it with these substances.

The child, found the same day, was 50.5 cm. in length, and much soiled by the ashes and coal-dust, which substances were also found in the mouth and nose. The face was markedly cyanotic, the conjunctivæ ecchymotic. To the outer side of the right angle of the mouth a linear abrasion 5 mm. in length; on the left cheek several lentil-sized, irregular, non-hemorrhagic excoriations. Beneath the angle of the right lower jaw two such places, swollen and surrounded by an area of violet discoloration. The skin of the anterior part of the neck, from the upper edge of the larynx to the clavicles, of greenish, dirty-violet color, swollen, revealing small scattered scratches.

The mouth, even to the recesses of the pharynx, almost completely filled with ashes and small particles of coal-dust. After careful removal of these foreign bodies the mucous membrane is found very much excoriated; the pillars of both fauces, as likewise the pharynx on both sides, irregularly lacerated. These lacerations to either side of the esophagus penetrate deeply into the connective tissue and form cavity-like spaces filled with blood-clots, ashes, and particles of coal.

The lungs crepitant, here and there containing aspired blood and isolated particles of coal-dust. The stomach distended with air and bloody mucus, but containing no foreign body. Punctiform ecchymoses of the heart.

FIG. 82.—Likewise a child born in secret of a maid. The mother asserted that the child was dead-born, and that she had hidden it in an ash-chest until an opportunity afforded itself of her conveying it to the graveyard.

The body was 50 cm. long *in toto*, soiled with blood and ashes.

After careful cleansing of the body the face was cyanotic and showed various punctiform ecchymoses of the conjunctivæ. In the region of the right angle of the mouth and on the right cheek several short, linear, non-hemorrhagic scratches.

The pharynx obstructed by a firm plug the size of an apple, consisting of crumpled white paper. In either side of the pharynx a longitudinal laceration—1.5 cm. long, revealing the pharyngeal muscles—with slightly ragged edges, showing bloody infiltration and punctiform ecchymoses.

The lungs are crepitant throughout, with isolated ecchymoses the size of hempseeds. The heart likewise ecchymotic. The stomach distended; likewise the duodenum and the adjoining part of the jejunum.

## PLATE 6.

### Lungs of Newly Born Infants.

**a. Lung after the Occurrence of Full Respiration.**—The left lung of a mature child, born living and crying, which immediately after its birth was killed by its mother by blows upon the head with a block of wood.

The lung is completely distended, in consequence of the fractures of the skull somewhat anemic, everywhere bright red, marbled, with isolated punctiform ecchymoses on the diaphragmatic surface. The edges are rounded, the interstitial vessels moderately injected. With unaided eye the pulmonary vesicles are to be seen, but indistinctly: distinctly, however, with a weak lens (smaller illustration), whereby they appear symmetrically distended with air. The entire organ feels as an air-cushion, crepitates on section, and the section-surface when passed over by the knife gives everywhere fine frothy fluid and a moderate quantity of dark blood. The bronchi contain fine froth. The lungs float on water both in their entirety, as in individual lobes, even when cut into small, bean-sized pieces.

**b. Air in a Lung in Consequence of Putrefaction.**—The right lung of an excessively putrid mature child found in the open air wrapped in paper, behind a plank.

The body weighs 3320 grams, is 52 cm. in length, everywhere markedly turgid, the skin putrid green, with epidermis that readily strips off. Injuries are nowhere demonstrable. The brain a malodorous semi-fluid mass; the meninges with hemorrhagic imbibition. In the thoracic and peritoneal cavities a moderate quantity of bloody transudate.

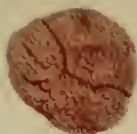
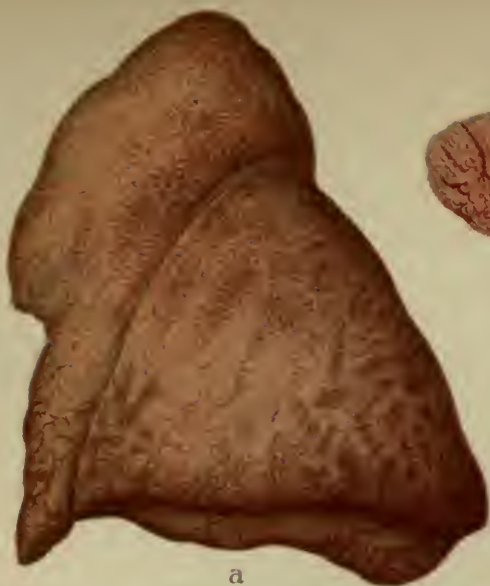The lungs dirty brown-red, very soft, after removal collapsing. The pleura covering elevated by isolated gas-vesicles the size of poppy-seeds to beans, partly displaceable. The remainder of the pulmonary surface smooth, the pulmonary acini in consequence of the fulness and hemorrhagic imbibition of the interstitial vessel-network distinctly demarcated. Alveoli containing air are not demonstrable. *The lungs in toto float.* On section the lung is a discolored, brownish-red, almost semisolid mass, in which one may recognize isolated smaller and larger gas-vesicles, which are readily expressed, after which the corresponding part of the lung immediately sinks in water. Foreign substances are demonstrable neither in the pulmonary parenchyma nor in the air-passages.

The stomach and intestine discolored, everywhere distended with gas, floating upon water. The meconium pervaded by numerous air-bubbles; the intestinal mucous membrane likewise abundantly elevated by gas-vesicles.


The liver, spleen, and kidney, softened and discolored, pervaded by numerous gas-vesicles, and floating upon water. We have therefore apparently to deal either with an already dead-born—possibly even macerated—child, or with a child which, although it may have been born alive, never respired.

The presence of air in the individual organs and their consequent floating were doubtless dependent upon the advanced putrefaction and the coincident formation of putrefactive gases. We see here that lungs devoid of air putrefy relatively slower than other organs, as the lungs contained relatively few gas-vesicles, whereas the liver, spleen, etc., as likewise the subcutaneous and other connective tissues, were richly supplied.

The child must have died several weeks before its discovery. Internally no indications of violence were found.



a



b





## PLATE 7.

### Newly Born Child. Suffocation by a Portion of the Membranes.

Among the causes which may hinder the respiration of a newly born child, and thus, even without the co-operation of its mother, lead to its death, must be counted its birth within unruptured membranes, or with a portion thereof situate over its face or entire head.

Plate 7 refers to a medicolegal case of the latter variety.

The child—a female—was found November 30th, wrapped in white linen, under a refuse-box in a gateway.

It was 46 cm. long, weighed 1820 grams, of a pale fleshy color, with slight panniculus adiposus, uninjured. The entire head was covered with a serous, transparent, in part dried membrane, which, leaving the region about the left lower jaw exposed, covered the rest of the face, being everywhere in close apposition to the skin, partly smoothly, partly in small folds, closing both the eyes and the orifices of the respiratory organs. Under the chin and running almost horizontally with the upper part of the neck the membrane was irregularly torn, the torn edge being much dried.

The necropsy revealed some air in the slightly ecchymotic lungs; some air in the stomach. The latter, as also the upper 4-5 cm. of the duodenum, floats upon water. Otherwise no noteworthy discoveries. In the lower epiphysis of the femur no center of ossification demonstrable.

The opinion was expressed that the premature child was born alive, and that it died of suffocation, manifestly due to closure of the orifices of the respiratory organs by a portion of the membranes covering the face. It is scarcely to be supposed that this portion of the membranes was intentionally placed over the face of the child, as such a procedure presupposes a certain special knowledge and much dexterity. It is most probable that this portion of the membranes was torn away during the process of birth by the advancing head, and that the child was born with the head covered therewith, which occurrence has frequently been observed, and is sometimes—however, without justification—designated as “birth with a caul.” The fact that air was found in the lungs and in the stomach does not invalidate this assumption, as the region about the left lower jaw was uncovered, whence some air might reach the respiratory orifices. As the portion of membrane was transparent and very thin, and while moist became closely applied to the skin, it is not certain that this impediment to respiration was observed by the mother, and in consequence it cannot be unconditionally asserted that she intentionally permitted it to remain, and thus killed the child by withholding the requisites of life.

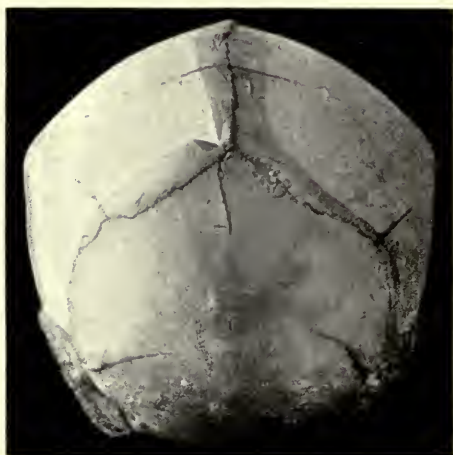
As there was no caput succedaneum demonstrable, the labor must have been rapid.

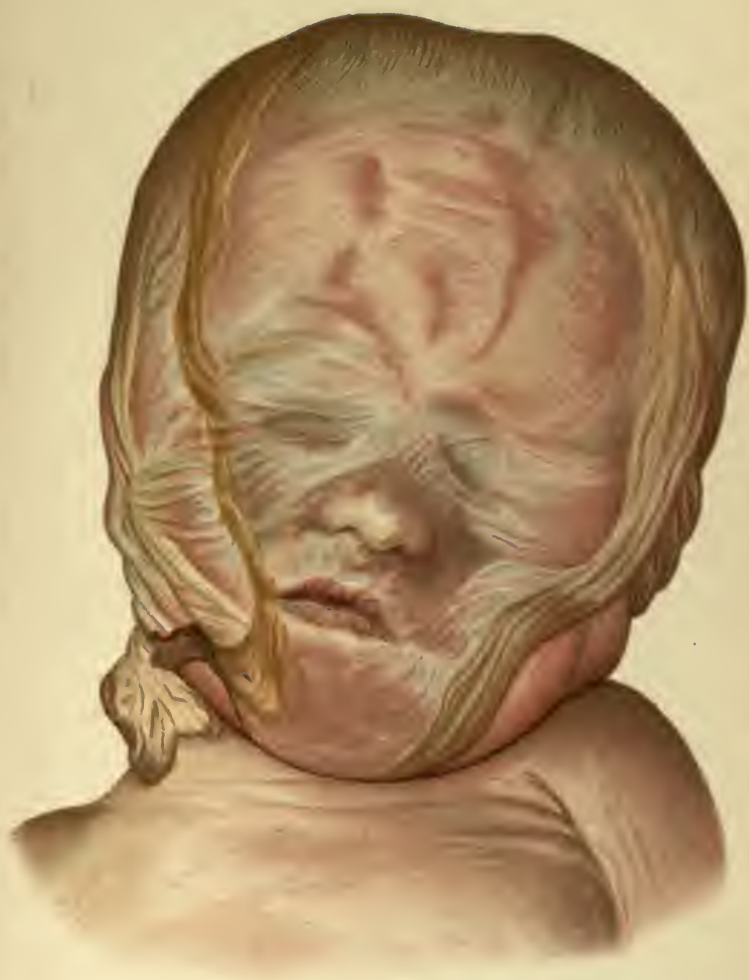





Fig. 83.



### FIGURE 83.

#### **Congenital Fissure-formation of the Skull of the Newly Born.**

Certain congenital fissures of the skull of the newly born belong to the ordinary findings. The most constant are those of the occipital bone, of which there are three. Of these, one proceeds from each lateral angle of the pentagon which the tabular portion of the bone forms, and ascends in the direction of the protuberance, while the third descends from the apex of the tabular portion. They are usually 1-1.5 cm. in length, but may exceptionally reach to the protuberance and thus divide the tabular portion of the bone into two or three parts, which when there are an upper and a lower half may simulate a transverse fracture.

In the parietal bone also one meets with congenital fissures in constant situations, especially at the posterior third of the interparietal suture. Here we find in each bone opposite to each other a fine or coarse fissure which runs in the direction of the parietal eminence, a distance of 1 to 2 cm. Not infrequently the inner ends of these fissures by the separation of their edges form a rhombic or oval space—the so-called accessory fontanelle.

A second situation is above the middle of the edge of the parietal bone which forms the parieto-occipital suture, where on either side there is usually a short fissure, sometimes 2-3 cm. in length, in the parietal bone, which in very rare cases continues through the tuberosity to the coronary suture, and thus causes a division of the bone into two parts, which in the newly born and also in older individuals may simulate a fracture.

In the skull illustrated one notices all three varieties of congenital fissures. In doubtful cases, in addition to the typical situation of the fissures, the differential diagnosis may be made in the fresh skull by the filling up of the fissure by a membrane, in skulls from which the soft parts have been removed by the sharp or rounded condition of the edges.

## FIGURES 84, 85.

### Fig. 84.—Defects of Ossification in the Skull of a Newly Born Child.

To either side of the interparietal suture, between this and its eminence, there are in the parietal bone various perforations varying in size from that of a lentil to that of a bean. They have irregular edges, toward which the bone becomes remarkably thin, a fact which is especially evident upon transmitted light. The portions of the parietal bone between these openings are also as thin as paper and often translucent. Similar but smaller perforations are also present in the posterior part of the frontal bones.

These are defects of ossification which occur frequently, but in varying intensity, in the skulls of the newly born. They possess a forensic importance in the first place, as *locus minoris resistentiæ*, in that through them blows are more readily transmitted to the brain and fractures of the intervening portions of bone more readily occur than otherwise,—as, for instance, through the compression of the skull during birth; and further, because such places—when examined through the scalp—as a result of their flexibility and crepitation, simulate fractures of the skull and may be considered such; but after the removal of the scalp the findings are so characteristic, especially when the skull is held toward the light, that confusion with traumatic changes is scarcely possible.

---

### Fig. 85.—Pretended Precipitate Birth in a Closet. Spoon-shaped Depression of the Left, Compression-fracture of the Right Parietal Bone.

The mother asserted that she had been taken unawares with parturition in a closet, whereby the child fell from the second story to the closet-well below. Here it was found still alive and taken to a foundling-hospital, where it died at the end of twenty-four hours.

The necropsy revealed externally a linear abrasion of the skin over the left frontal protuberance, 1.5 cm. long, and a transverse trough-like depression over the left parietal bone. After the removal of the scalp there was found at the latter situation a so-called “spoon-shaped depression,” whose point corresponded to the parietal eminence and whose wider part reached almost to the interparietal suture. This depression in the direction of its long axis is wedge-shaped and corresponds in part on the inner surface of the skull with a fine fracture of the inner table. The deepest part of this depression is situate near the

Fig. 84.

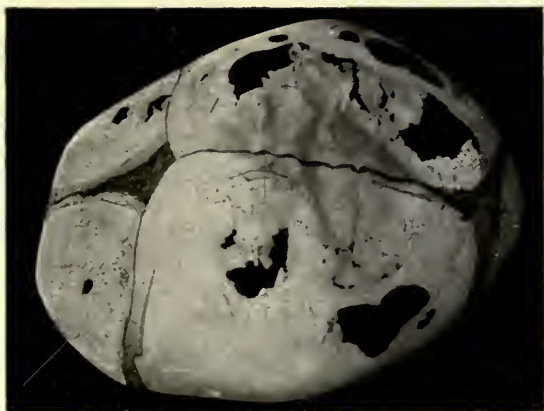
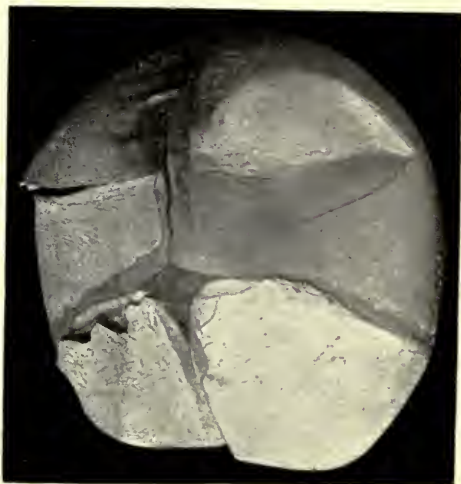





Fig. 85.



eminence, from which along the posterior edge of the spoon there runs a fracture 2 cm. in length, toward the median line. In addition, there was found a gaping fracture of the right parietal bone, which, beginning at the middle of the interparietal suture, gradually grows wider in the direction of the parietal eminence, then forming a very obtuse angle runs backward and below to the base of the skull. The further examination revealed an extensive intermeningeal hemorrhage, which was distributed over almost the entire brain, and circumscribed pneumonic foci in the lower lobes of both lungs.

The opinion was expressed that the child died of intermeningeal hemorrhage consequent upon the injuries to the skull. In regard to the spoon-shaped depression, there was, of course, the distant possibility that it arose through the fall down the closet, and at the same time as the fracture of the right parietal bone,—conceding in such case that the child fell against a blunt and prominent object, striking that part of the parietal bone between the eminence and the interparietal suture; but at the same time we must remark the infrequency of such an occurrence, and that we know from experience that such depressions result rather from less sudden blows against the skull. They may be produced during birth by the pressure of the skull against the promontory of the sacrum over which it passes or is drawn under great pressure, or after birth by compression of that part of the skull by a blunt instrument.

As the parturition was easy, and as there existed no disproportion between the size of the child's head and that of the mother's pelvis, the supposition that the spoon-shaped depression occurred during labor is not justified; we must therefore conclude that the depression occurred between the time of the completion of parturition and that of the fall down the closet. It might have been produced by pressure exerted by the hand on the head, but also by stepping thereon, or by the knee. As, however, the accused later withdrew her earlier assertion that the child without any co-operation on her part fell down the closet, and acknowledged that she had pushed it down the closet-well, through a funnel-shaped opening but 10 cm. in diameter, the most reasonable inference is that the depression was produced by this latter manipulation, and that the fracture of the right parietal bone was caused by the fall down the closet-well.

## FIGURE 86.

### Fracture of the Skull from a Fall on the Vertex.

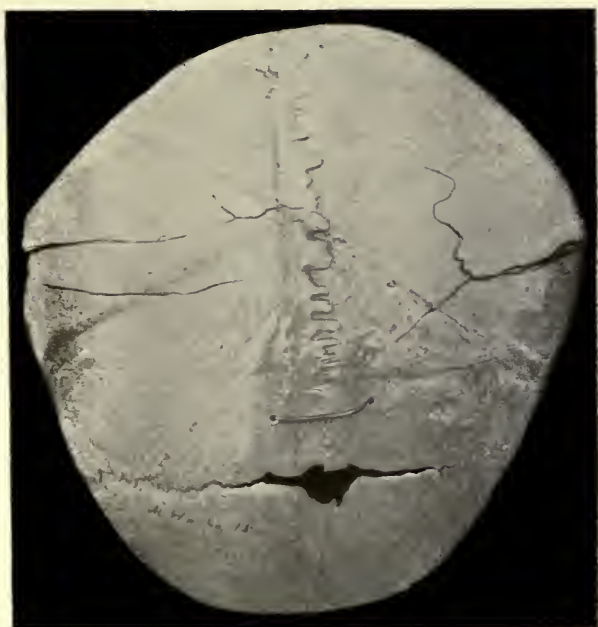A child, aged 18 months, during a moment when unguarded fell from a first-story window to the courtyard below, striking, as witnesses assert, upon the vertex, and died in a short time.

Externally no injuries were discovered. Under the scalp, however, there was an extravasation of blood which extended from the vertex to the temporal region of each side, where it attained its maximum size. After its removal there were found to the right a double, to the left a single, gaping fracture of the parietal bone. The upper parts of the fractures of the right bone run parallel with the former radiations of ossification almost to the middle of the interparietal suture, whereas that in the left—originally pursuing the same course—divides between the parietal eminence and the interparietal suture into two finer fractures.

Below, the fractures in each bone continue as an irregular shattering of the posterior part of the squamous portion of the temporal and the underlying portion of the parietal bones. Both fractures gape mostly at the parietal eminences, and open still more by pressure upon the vertex—after removal of the pressure returning to their former condition. The dura mater and the more internal meninges were torn along these fractures, and through these lacerations on both sides there protruded disintegrated brain-substance. The latter was also deeply lacerated, and the cortex both in the immediate vicinity and also in more distant situations much contused. Everywhere extensive intermeningeal hemorrhage.

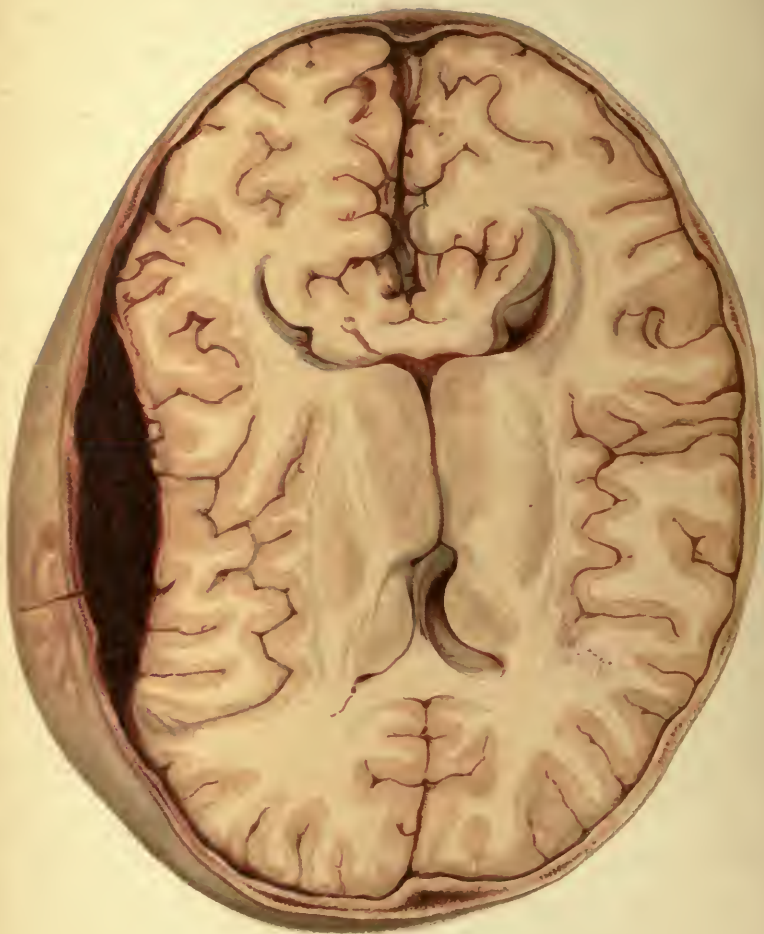The method of the production of these fractures is easily understood. By the fall on the vertex the vault of the cranium was suddenly much compressed in the direction of the base of the skull, and much distended in the direction of a line at right angles thereto. This had, as its result, the fracturing of the parts the most distended—the parietal eminences, from which situation, as the point of original fracture, the breaks continue on the one hand in the direction of the vertex, and on the other of the temporal regions. The non-occurrence of a fracture of the base of the skull in this case is due to the infantile age of the individual, during which time of life the base of the skull, as a result of the still defective ossification and the abundant cartilaginous symphyses, does not yet possess that compact and at the same time brittle condition as is the case in later life.

Fig. 86.









## PLATE 8.

### Fracture of the Base of the Skull with Extradural Hematoma.

The upper half of the skull and brain of a boy aged 9 years, upon whom a necropsy was performed October 25, 1895. He had returned home from a gymnasium the evening of October 22d, vomited, was carried to bed, became immediately unconscious, and died the next day. It was subsequently learned that he had fallen in the gymnasium, striking upon his head, and was in consequence sent home.

The necropsy revealed no external injury. Under the left temporal muscle, however, there was an extensive suffusion of blood, and under this a fine fracture of the bone, which began in the parietal bone, 2.5 cm. above its serrated edge and extended below to the inner part of the left middle fossa of the skull. Here it gave off several branches and, continuing into a slight diastasis of the adjoining sutures, ended in the foramen spinosum.

The dura mater was as though dissected away from this fracture and the vicinity, by a large lentil-shaped blood-coagulum, which occupied the entire left temporal region, extending into the middle fossa of the skull, pressing the dura inward, flattening the corresponding portion of the brain-cortex, and displacing inward the latter with the lateral ventricle. The extravasated blood came from a rupture of the principal anterior branch of the middle meningeal artery, produced by the aforementioned fracture of the skull which affected the sulcus in which the artery runs.

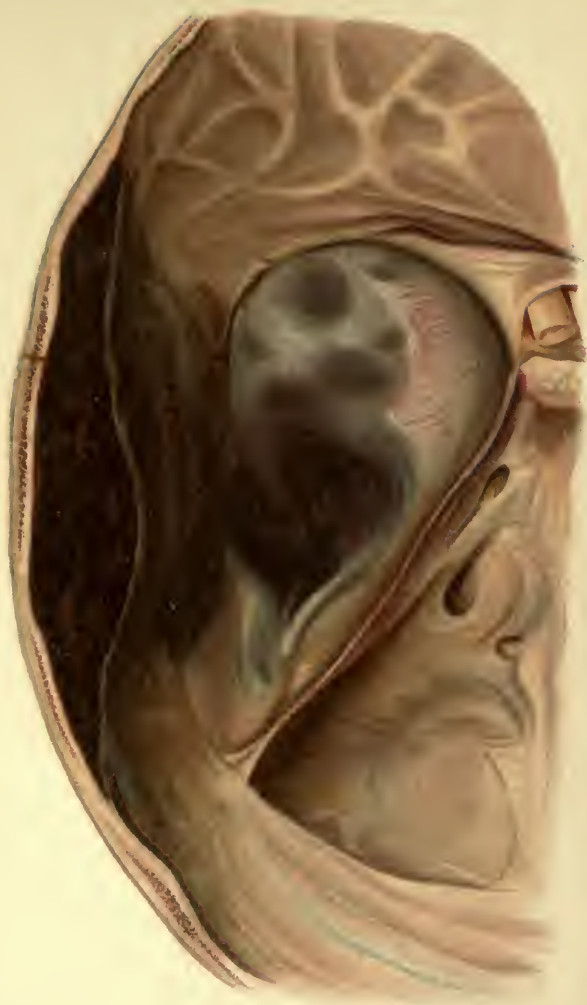We have, therefore, a typical external hematoma of the dura mater, such as relatively frequently tends to develop, particularly after fractures of the temporal region.

The fact that the boy was able to return home after the occurrence of the injury is explicable, on the one hand, because there occurred no marked concussion of the brain, and, on the other, because the hemorrhage did not take place suddenly, but rather gradually. The extravasating blood had first to dissect up the dura mater from the bone, and then overcome the resistance offered by the brain, before it attained a size sufficient to give rise to symptoms of severe compression of the brain.

## PLATE 9.

### **Traumatic Extradural Hematoma.**

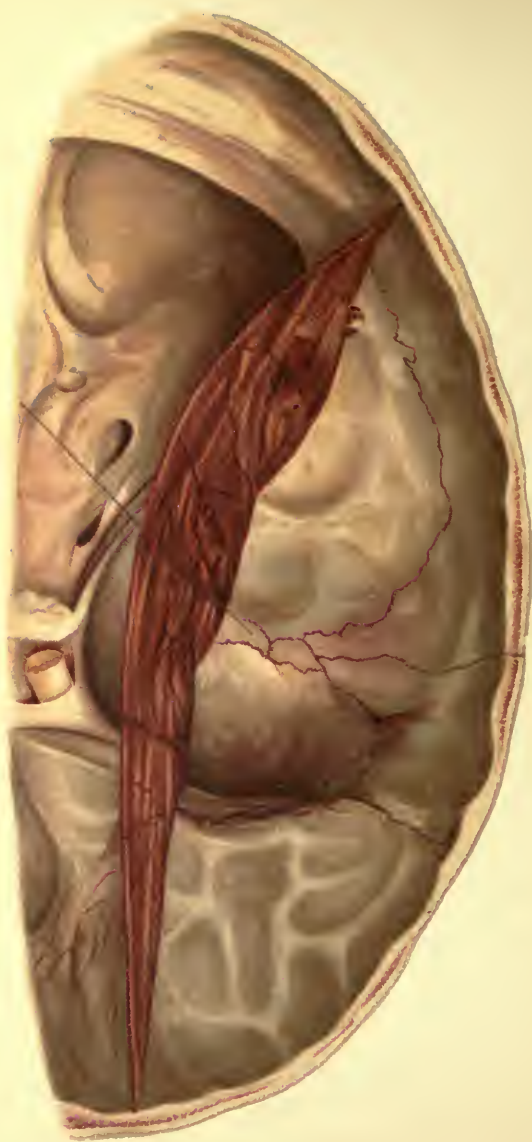The figure shows the lower half of the skull of the case illustrated in Plate 8, and reveals the lower part of the entire hematoma, with the characteristic elevation of the dura mater, through which the extravasated blood glimmers.







Tab. 10.



## PLATE 10.

### **Fracture of the Base of the Skull, with Rupture of the Middle Meningeal Artery—after Removal of the Extradural Hematoma.**

The plate shows the base of the skull of the case illustrated in Plates 8 and 9 after removal of the blood-clot and further dissection of the dura mater. On the one hand, there are noticeable the branchings of the fracture in the middle fossa of the skull and the slight diastasis of the adjoining sutures, and, on the other, the ramifications of the middle meningeal artery entering the cranial cavity through the foramen spinosum, and distributing itself over the external surface of the dura mater. A bristle is introduced into the branch of the artery ruptured by the fracture.

## FIGURE 87.

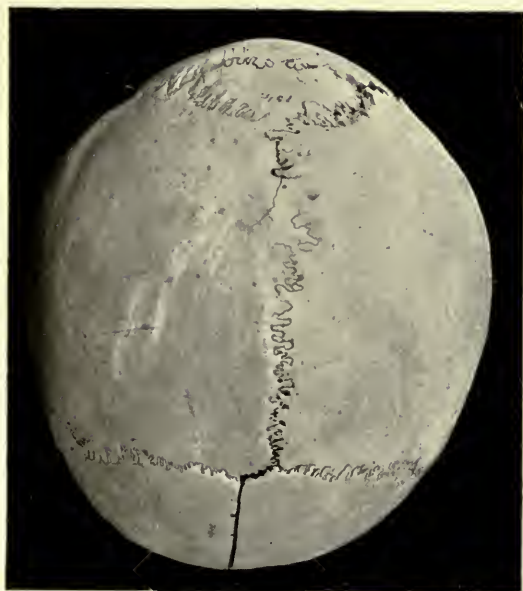
### Fracture of the Skull due to Compression.

FIG. 87 furnishes an instructive example of fracture of the skull due to compression. The skull is that of a laborer, aged 32 years, who, while building, was struck on the head by a mortar-shaft, and who died a few hours later.

In the middle of the vertex there was an irregular wound 2.3 cm. in length, markedly suffused with blood, and extending to the cranial aponeurosis. After removal of the scalp there were found two isolated fractures of the skull. The first begins at the posterior extremity of the anterior third of the interparietal suture as a diastasis of the latter. It then continues to the right of, and in the direction of, the former frontal suture to the right upper orbital ridge, into the orbital fossa, and ends in the os planum of the ethmoid bone. The second begins to the right of the anterior extremity of the posterior third of the interparietal suture as a fine, hair-like fracture. Posteriorly it becomes wider and runs into a diastasis of the posterior part of the interparietal suture, continues as a diastasis of the left parieto-occipital suture, then into the left posterior fossa of the skull, in the deepest part of which it ends as it began, hair-like. The base of the skull is otherwise uninjured, as is also the vault of the skull. Particularly is that part of the vault above which the scalp-wound was situated, and which corresponds with the middle third of the interparietal suture, both internally and externally uninjured.

We have, therefore, to deal with an instance of double fracture of the skull, which in a certain measure represents a type of fractures dependent upon compression. These are caused by a sudden force striking the skull, and causing a compression of it in the direction of the force and a distention in the direction of a line at right angles thereto. Thus the skull, similarly as a compressed hazelnut, fractures at the point of greatest distention situated equatorially to the point of impact of the force. On the one hand, then, the fracture ascends meridianly toward the point of impact, and, on the other, continues toward a point situated oppositely. Thus is explained why the fractures gape mostly at a situation most distant from the point of impact and toward the latter become hair-like, and why, as is particularly evident in the present case, the fractures do not necessarily reach the point of impact nor the opposite point of the skull.

Fig. 87.







## PLATE 11.

### Recent Contusions of the Brain.

A. G., aged 40 years, while at work April 11th, fell from a second-story scaffolding, and died within a half hour.

The necropsy revealed two lacerated wounds of the occipital region and a gaping fracture of the skull extending from the posterior end of the interparietal suture through the squamous portion of the right temporal bone to the base of the skull, where at the base of the petrous portion of the right temporal bone it bifurcated. One limb of the bifurcation extended through the anterior surface of the pyramidal portion of the bone to its apex,—opening the tympanic cavity, whereas the other ended in the occipital foramen.

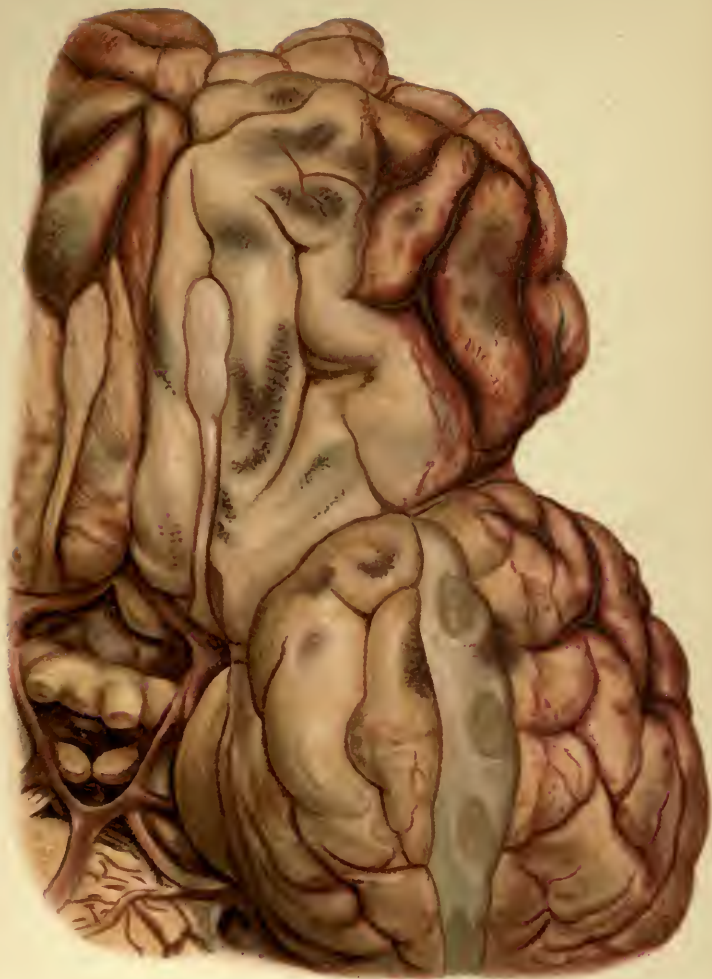Between the dura mater and the inner meninges throughout the entire base and lateral aspects of the brain freshly coagulated blood in thick, irregular layers.

After partial removal of the internal meninges and washing away of the blood-coagula beneath, one notices on the base of both frontal and temporal lobes—as also to a less degree on other portions of the surface of the brain—isolated, dark-violet spots as large as a bean or larger. They affect mostly the brain-cortex, but here and there also the adjoining area of medullary substance. On more careful examination they are found to be made up of small—some very small—extravasations of blood. Between them and about their periphery the brain-substance—through imbibition—has assumed a diffuse and pale-violet color, and is somewhat softened.

On section of these spots, but more frequently on the surface, one notices punctiform or larger-sized disintegrations of the brain-substance.

These changes are designated contusions of the brain. They are common after great shocks or agitations of the head, and affect either the part of the brain nearest the seat of injury or—and, indeed, much more frequently and extensively—the opposite part of the brain through *contrecoup*.

They are supposed to be caused by the impact of the brain-cortex against the inner surface of the skull, or to be due to localized destruction of the cortex induced by the disturbed and agitated cerebrospinal fluid. But a part in their production may also be played by the disturbing and agitation of the blood circulating in the numerous and very fine blood-vessels of the cortex. Further, all three causes may be simultaneously operative.







## FIGURE 89.

### Healed Hole-fractures (Lochbrüche) Produced by a Blackjack.

F. P., aged 44 years, had killed his mistress, June 14, 1892, with numerous stabs of the broken blade of a sword, which he had fastened in a wooden hilt, and a few hours thereafter had killed himself by shooting with a revolver through his right temporal region. The shot produced a simple opening above the right wing of the sphenoid bone, and the channel of the wound penetrated transversely the bases of both frontal lobes of the brain and ended blindly on the inner surface of the squamous portion of the left temporal bone. On the uninjured inner surface of this latter bone a slightly misshapen conoidal bullet, 6 mm. in width on the base, was found.

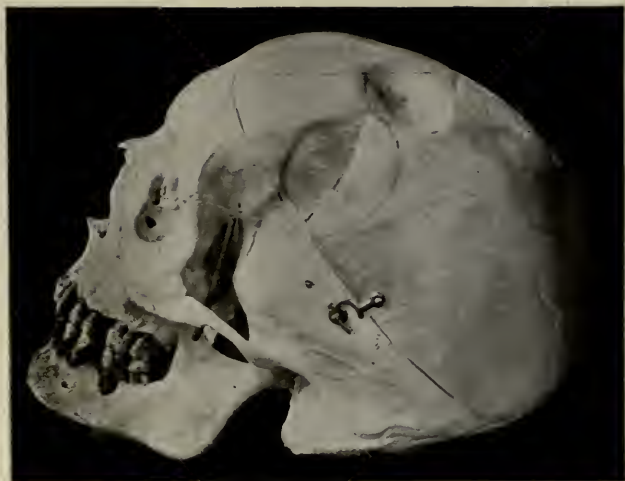In addition, there were discovered two almost circular depressions of the left frontal bone, situated one above the other, and having a diameter of 3.5–4 cm. Of these, the lower, somewhat larger, is situated directly over, and is bisected by, the outer part of the coronary suture; whereas of the upper, but its posterior part includes the suture. The almost circular edges of these depressions are rounded throughout, and toward the inner side show a circumvallate excavation. The enclosed plate of bone is flat, with a funnel-shaped depression, and shows several healed fractures. The vitreous table corresponding to the lower depression is slightly prominent to the inner side, revealing three scarcely discernible healed fractures extending from the middle of the depression to the edge; whereas that corresponding to the upper depression—about 3.5 cm. in extent—projects as a blunt cone 6–8 mm. in height, from the apex of which five healed fractures radiate. The dura mater is adherent to this cone, and here and there reveals rusty-brown pigment—otherwise uninjured. In the brain no indication of a healed injury.

Anamnestic, it was learned that eight years previously F. P., during a quarrel, had received two blows upon the head with a blackjack, in consequence of which he was sick for a long time, and that since then there had been a depression on his head which he was wont to exhibit. Since this injury he is said to have been of a changed nature; to have been irritable and passionate, in consequence of which his wife secured a divorce. On account of excesses he was frequently arrested. It is asserted that after indulgence in alcoholics he was much more excited and violent than usually.

Before the killing of his mistress and himself he is said to have been very much excited, and to have complained of his head. Among his effects there was found a letter addressed to the authorities, in which he informed them that his mistress had already caused much misfortune to many, but that he would be the last.

From the above, therefore, it follows that, as a consequence of the injury received eight years previously, the man had been for a long time mentally unsound, and that both the homicide and the suicide were committed during a period of insanity.

Fig. 89.

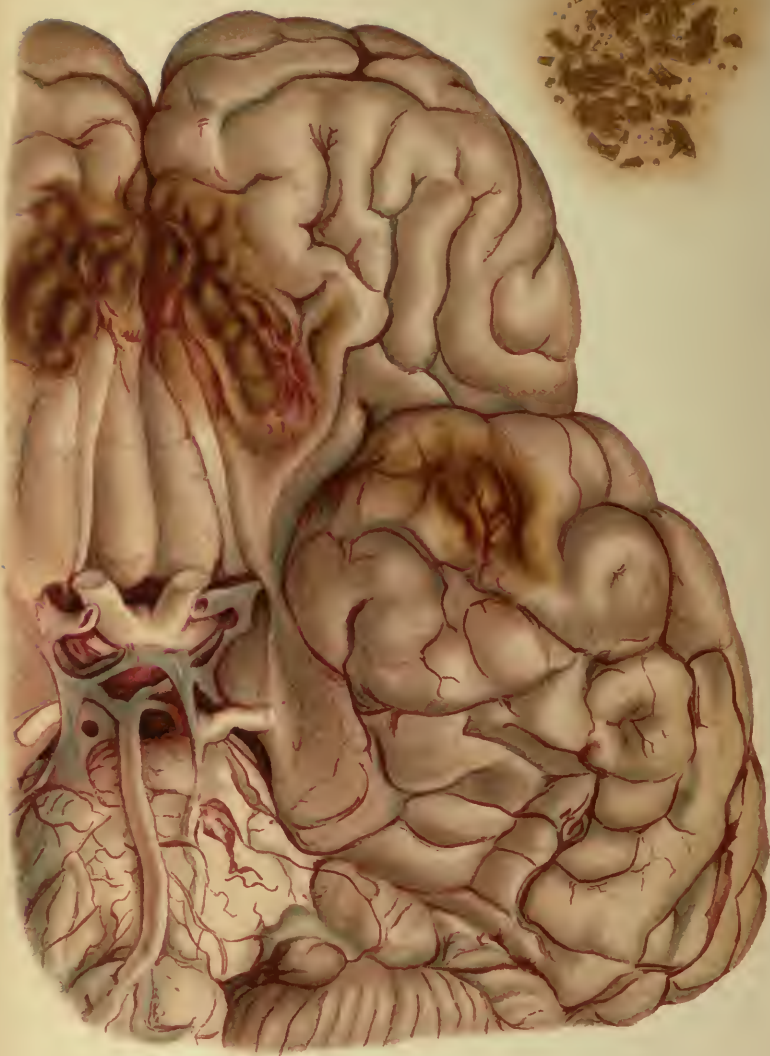











## PLATE 12.

### Healed Contusions of the Brain.

Having become acquainted—in Plate 11—with the appearances of recent contusions of the surface of the brain, the present plate will serve to illustrate the appearances of such contusions after healing.

The preparation is from a woman, aged 56 years—for years addicted to intemperance—who, in the beginning of August, 1896, while intoxicated, fell down four of a steep flight of steps to a stone pavement below, where she remained prostrate and unconscious. She did not return to consciousness for two days, and was obliged to remain in bed for two weeks. Since then she is said to have been feeble-minded and forgetful, and to have been more addicted to intemperance than previously.

November 18, 1896, she was found dead.

The necropsy revealed chronic alcoholism as the cause of death, and in addition the following conditions of the head:

The scalp uninjured. The skull thick-walled, showing a completely healed penetrating fracture of the left parietal bone, running from the posterior part of the interparietal suture to the parietal eminence, there forming an obtuse angle and coursing directly forward almost to the coronal suture; from about the parietal eminence it gives off a limb which is directed downward. The inner surface of the dura mater—to the left in part, to the right throughout—reveals rusty-brown spots, and, in addition, to the right the dura mater is covered with an extensive, very thin membrane which strips readily. The latter is pervaded in part with rusty-brown pigment-spots, in part with brownish, inspissated blood-extravasations, and shows here and there fine vascularization (healed intermeningeal hemorrhage).

On the base of the brain on both sides, in front of the olfactory bulbs, there are found brownish-yellow, irregularly depressed areas, the size of a quarter-dollar piece. They affect only the brain-cortex, and are united with the inner meninges. They consist in part of brownish cicatricial tissue, in part of a rusty-brown, jelly-like mass, in which microscopically numerous, rhombic, reddish-brown crystals (hematoidin-crystals) are demonstrable, as in the smaller illustration of Plate 12. There are also similar areas on the forward part of the bases of both temporal lobes. Of these, however, only that of the left could be figured.

These areas are the residua of contusions of these parts of the brain received a long time previously. Their traumatic nature is indicated by the remains of the intermeningeal hemorrhage, and especially by the healed fracture of the skull, in addition to their typical situation, their multiplicity, and their symmetric location.

It was evidently the fall sustained while intoxicated three months previously that gave rise to these injuries, a fact proved not only by their nature and the symptoms that developed subsequently, but also by the present findings. In addition to remains of inspissated blood in the membrane attached to the dura mater, there was found still an active congestion of that part of the brain posterior to the area in the left frontal lobe—conditions which preclude the possibility of the injuries having been sustained many months or years previously.

---

## FIGURE 92.

### -- Hole-fractures (Lochfracturen).

A hole-fracture (lochfractur)—in process of repair—of the left parietal bone, produced with a four-cornered locksmith's hammer. The fracture is almost circular, and has a diameter on the external surface of the skull of 4 cm. and on the internal surface of 4.5 cm. It surrounds a disk-shaped, depressed piece of bone, which gave rise to no laceration of the dura mater, but which shows partly radiate, partly semicircular fractures, most of which are already in process of healing. The circular form of the fracture, despite the four-cornered shape of the hammer, is accounted for by the fact that long use caused a rounding of the edges and corners of the hammer, but especially because of the thick growth of hair of the deceased, and by the fact that at the time of injury the head was covered with a cap.

Fig. 92.








Fig. 93.

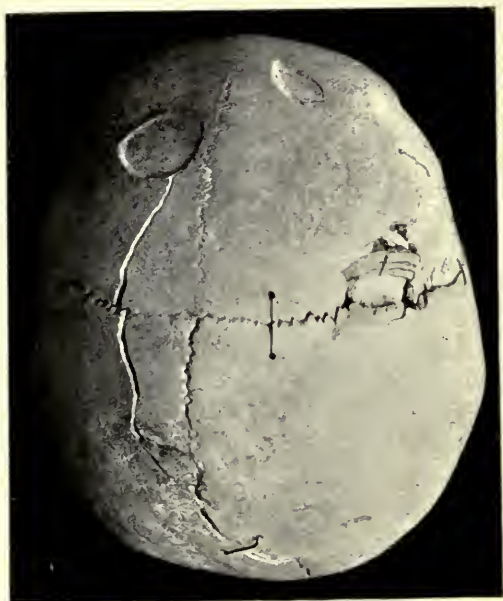

FIGURE 93.

**Murder Produced by Blows with a Round Hammer.**

There are noticeable, in the first place, in the vault of the skull illustrated in the figure, two injuries of the anterior frontal region, both of which resemble each other in form, that in the left half of the frontal bone, however, being larger than that in the right. Both are incomplete hole-fractures (*lochbrüche*), oval in shape, with their long axes running diagonally. The posterior edges of both are more arched and also sharper than the anterior. The portion of bone enclosed in these arched fissures is, in both instances, depressed at its posterior part, so that its edge is 1 mm. lower than the posterior edge of the fracture. From the middle of the posterior edge of the left-sided fracture there commences a gaping fracture of the bone which courses through the frontoparietal suture to the middle of the interparietal suture, thence to the right posterior fossa of the skull, where it ends.

Still within, and in advance of the middle of the separated right frontoparietal suture, there is a fracture the size of a dollar, irregularly circular in shape, with edges partly serrated, partly irregularly broken. The enclosed portion of bone is shattered and the fragments driven deeply into the cranial cavity, lacerating the meninges and bruising the upper layers of the brain-cortex.

After replacement of these fragments one notices, as shown in the illustration, that the fracture in question consists of arched, terrace-like fragments, with their concavity directed backward, and that between the individual fragments bits of hair of the head are interposed.

From the form and other conditions of these fractures one may conclude that they were produced by a tool or implement which must have had a circumscribed striking-surface with circular edges; and we recall the fact that blows with a round hammer (shoemaker's hammer, etc.) are particularly likely to produce such injuries. And, in addition, from the distinct depression of the posterior part of the plate of bone of the first two fractures, and the sharper and more marked convexity of their posterior edge, as likewise from the terrace-like, arched fissures with concavity posterior of the third fracture, one may say that all the blows were produced from behind and by the edge (lower) of the implement directed toward the perpetrator.

The perpetrator was not discovered for some days, and then acknowledged that he caused the murder with a so-called French hammer, which had a circular, rather sharp-edged striking-surface, 2.5 cm. in diameter.

## FIGURE 94.

### **Skull of a Man who was Murdered and Remained Buried in a Manure-mound for Four Years.**


A peasant, much addicted to intemperance, disappeared suddenly four years ago. As his absence became remarked, his wife asserted that he had probably gone to America. The case appeared suspicious; all the more so as the couple had lived in continuous discord. The investigations, however, and excavations in the garden of the house were without result. Finally, at the end of four years a skeleton was found under a manure-mound, and the wife then acknowledged that she had violently killed her husband and buried the corpse to escape discovery. The husband is said to have returned home very much intoxicated, to have abused and threatened his wife, whereat she struck him. As a consequence of this he is said to have lost his balance, to have fallen striking his forehead against a bedpost, to have remained prostrate breathing stertorously, and to have died in a few moments. His wife is said to have then dragged the corpse through the door to the courtyard and to have buried it in the manure.

On the skull there was in reality found—as the illustration shows—an injury to the left frontal bone, which reveals an almost equilateral triangular perforation, 1.5 cm. in width. This may have been produced by a triangular-shaped object,—possibly by heavily falling against the triangular corner of the bedpost. There was found, however, posterior to this perforation in the frontal bone, a second likewise triangular fracture affecting only the outer table of the skull; and in addition a destruction of both malar bones and an incomplete fracture—almost the size of the palm of the hand—of the left temporal region, the latter of which was surrounded by an irregular circular fissure. It follows, therefore, that there must have occurred at least two violent blows with an angular, and at least additional blows with a more blunt instrument. These facts positively disprove the assertions of the woman that all the injuries occurred at one time, and clearly demonstrate that the deceased was killed by several—at least four—injuries to the head; and, further, that these occurred not simultaneously, but in direct sequence, and that one and the same implement, if it possessed both varieties of edges, may have been employed. The most likely supposition was that the triangular fractures had been produced with the cutting-edge, the others with the flat surface of the back of a hatchet. The truth of these suppositions was proved by the subsequent confession of the accused.

Fig. 94.

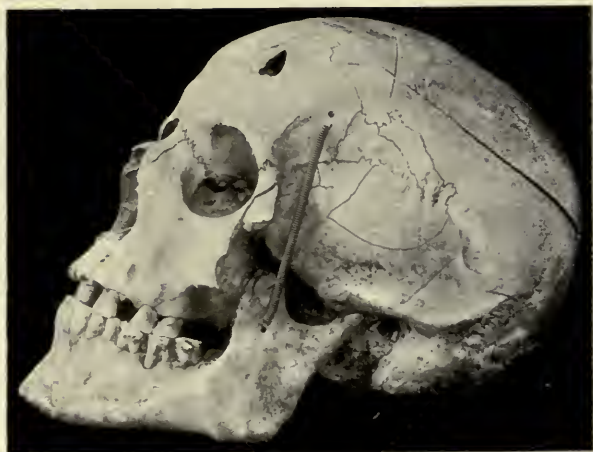

Fig. 95.







## FIGURES 98, 99.

### **Fig. 98.—Hole-fracture (Lochbruch) Produced by a Fragment of Glass.**

The hole-fracture in the left frontal bone—remarkable because of its regular rectangular form—was produced by a fall from an upper story of a house to a skylight below. The panes of glass, which were 1 cm. in thickness, were broken through by the falling body. The fragment of glass which was found firmly wedged in the fracture had with its inner end lacerated the meninges and the brain-cortex, and had given rise to a considerable intermeningeal hemorrhage.

---

### **Fig. 99.—Manslaughter by means of a Long, Angular Bar of Iron.**

The fracture, directed anteroposteriorly, affects the left frontal bone and has an irregular oval form, 5.5 cm. in length and 3 cm. in width. The fractured and depressed portion of bone is scaphoid in shape. This is caused by a keel-like depression which runs through the long axis of the oval, and which corresponds with a fracture both of the outer and of the inner table of the skull—findings which indicate the influence of the longitudinal edge of the instrument employed.

Fig. 98.

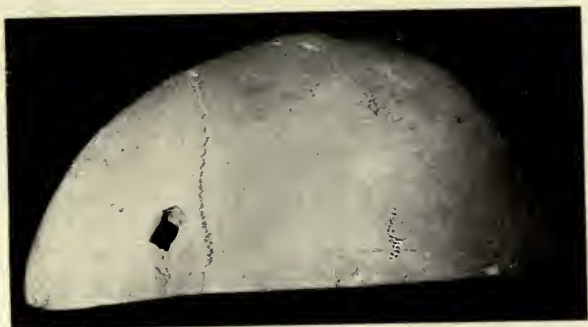
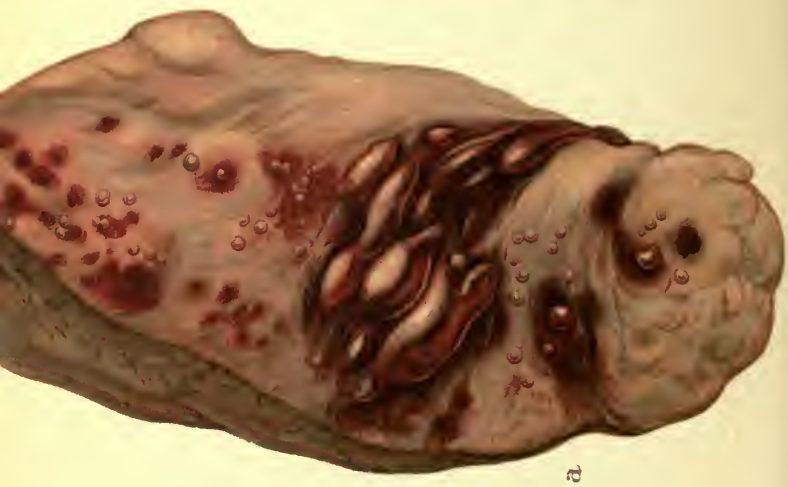


Fig. 99.

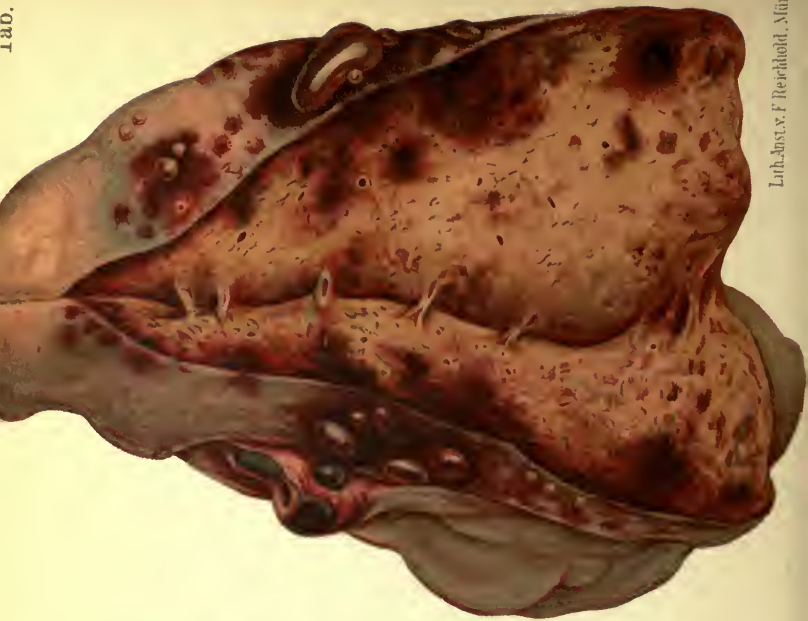








a



b

## PLATE 13.

### Contusio Pulmonum. Contusion of the Lung.

FIGS. *a* and *b*.—Upper and lower lobes of the left lung of a woman, aged 24 years, who killed herself during the night by jumping from the fourth story of a house to the street below, and who died immediately in consequence of extensive fracturing of the bones of the skull.

In addition, all the ribs of the left side and the sixth to the eighth of the right side were found broken. There were further partial laceration of the right lung at the hilus, and various ruptures of the capsule of the liver, but only slight hemorrhage into the thoracic and abdominal cavities.

The left lung revealed the peculiar conditions here depicted. Both lobes are visibly inflated and do not collapse after their removal from the body. The surface of both lobes, especially the external surface of the upper lobe (Fig. *a*) and the interlobar surface of the lower lobe (Fig. *b*), are rendered marmorate by subserous extravasations of bright-red blood the size of a half-dollar or smaller. Over the latter the pleura is elevated in vesicles in part the size of beans or larger, in part smaller. The subpleural extravasations are rather larger than walnuts, penetrate the pulmonary parenchyma in an irregular wedge-shaped manner, and, as is especially evident in Fig. *a*, are likewise pervaded by air-bubbles. In the deeper parts of the lung on section one notices also isolated, hemorrhagic, bean-sized spots, in which here and there minute air-bubbles are to be found.

Such lesions may develop in one of three ways: 1, through simple aspiration of blood; 2, through direct, or, 3, indirect contusion of the lung.

Aspiration of blood into the lungs is not uncommon in death either from natural causes (hemoptysis) or from violence (cutting of the throat, fracture of the base of the skull, etc.). In such cases the lungs, both their external surface as well as the surface of section, are rendered marmorate by the aspirated blood, and the bronchi are more or less filled with it. Rupture of certain alveoli, and consecutive interstitial emphysema, may also develop, but occur rarely, similarly as in the analogous death from drowning. In this form of death I have never yet seen air-bubbles as large as those observed in the case under discussion.

A direct contusion of the lung occurs especially in cases of fracture of the ribs, but is usually accompanied by laceration of the pleura, and even extensive laceration of the pulmonary parenchyma, but may take place without such associate lesions.

Most frequently, however, such lesions appear to develop indirectly—that is, not at the place where the force was applied, but at some distant point, thus: from that part of the lung which becomes suddenly compressed by the external force the air and the blood contained within the

vessels are suddenly driven toward the peripheral parts of the lung. There thus results a more or less extensive laceration of the lung-tissue, with hemorrhage and interstitial emphysema.

In the present case the lesions described probably developed indirectly. The fall from a great height directly upon the head, the resultant extensive fracturing of the skull, and the numerous fractures of the ribs led to a sudden compression of the thorax and a simultaneous displacement of the intrathoracic organs, especially the contents of the lungs, which in turn gave rise to the above-mentioned effects.

---

## PLATE 14.

### **Peritonitis from Traumatic Rupture of the Jejunum.**

M. H., aged 40 years, was taken to the general hospital the evening of January 12, 1896, where he died the same night. According to his own declarations, a large block of ice fell upon his abdomen two days previously.

The necropsy revealed no external injury. Internally within the abdominal cavity extensive fibropurulent exudate, uniting the various intra-abdominal viscera, especially the intestines, with each other and with the abdominal walls. The peritoneum throughout spotted, injected, and lusterless. At about the middle of the jejunum opposite the vertebral column a transverse laceration through the entire wall and about the entire periphery of the intestine, even to a small portion of the mesenteric attachment. The edges of the laceration with the mucous membrane are everted, swollen, congested, and covered with discolored extravasated blood, which latter is also found under the neighboring peritoneum. The area of laceration is adherent to the surrounding parts by means of exudate, which is here accumulated in large amount.

The causation of the rupture is explained upon the assumption that the affected area of the intestine was suddenly compressed against the vertebral column—a hard base—by the heavy falling block of ice, and thus brought to rupture.

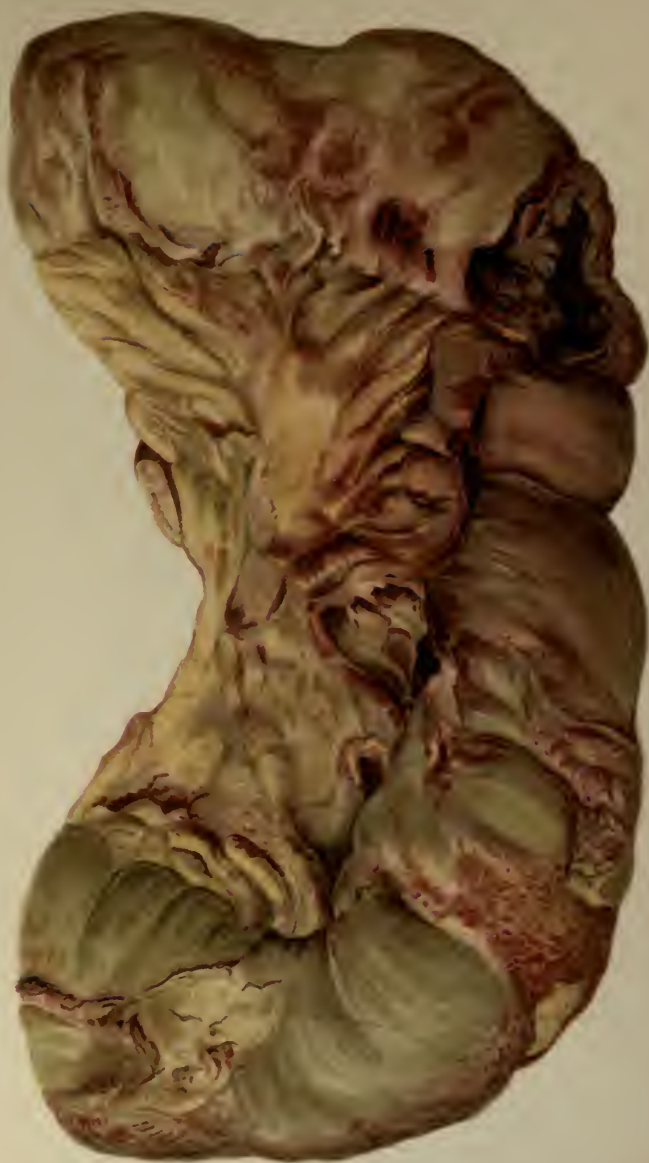
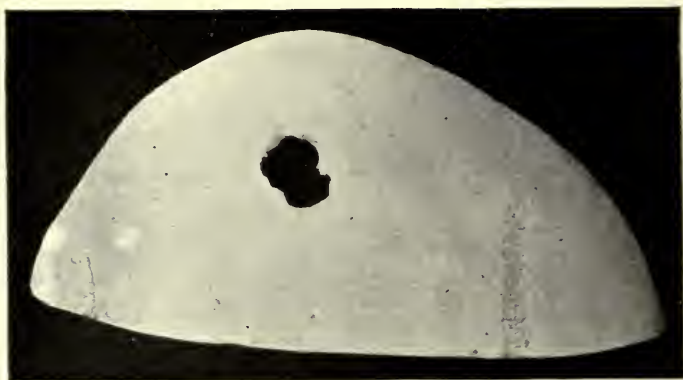




Fig. 100.



## FIGURE 100.

### Healed Hole-fracture (Lochbruch) of the Right Parietal Region.

G. W., aged 18 years, on July 8th, in sport, was struck a blow with the open hand by a companion, in the right parietal region. He became immediately vertiginous, vomited frequently, and began to have epileptic attacks, which, in the course of the following days, recurred at irregular intervals in increasing intensity and severity, and led to death on the tenth day.

The medicolegal necropsy revealed externally in the right parietal region a bean-sized, shining, somewhat retracted, adherent cicatrix. Beneath this a rather circular opening in the bone 18-20 mm. in diameter, with rounded, non-reactive edges. The aperture occupied by a firm cicatrix united, on the one hand, with the scalp, and, on the other, with the inner edge of the opening, the inner meninges, and the area of brain-cortex beneath. At the forward part of the inner side of this opening there are two almost bean-sized elevations of the vitreous table, one of which projects into the lumen of the opening and is depressed inward. The fragments are firmly united, and reveal no indication of recent fracturing. The portion of the brain-cortex immediately beneath and united with the opening is of roundish form, with a diameter upward of 20 mm., and includes almost the entire extent of the right parietal lobe. Otherwise there are no changes either of the brain or of the skull.

The other lesions at the necropsy were markedly hyperemic and edematous lungs, with extensive aspiration-pneumonia.

Inquiries revealed the fact that the healed fracture had been produced by a blow with a potato-trowel, which the deceased had received when a schoolboy. At that time he is said to have been sick for a long time, and a physician is said to have removed several fragments of bone. Since then the boy suffered from epileptic attacks, which, however, during recent years are said to have occurred infrequently.

Between the death of G. and the blow on the right parietal region suffered ten days previously, or the defect of bone at that situation, there existed doubtless a causative connection, as the blow induced severe and unusually frequent epileptic seizures, which in turn led to the extensive aspiration-pneumonia, the recognized direct cause of death. It must, however, be remarked that this blow caused the death of the deceased, not because of its general character, but because of the pre-existent defect of the bone at that situation, consequently because of a morbid condition of the body unknown to the perpetrator of the blow.

## PLATE 15, FIGURE 101.

### Murder the Result of Various Injuries Inflicted with Different Instruments.

On January 5th, at midday, B. K., aged 38 years, after having been heard screaming, was found in her room lying in a pool of blood and dying. Beside her stood her lover, with a bloody carving-knife in his hand. On the floor beside the body was a freshly broken tailor's flat-iron, completely besmeared with blood. The immediately imprisoned culprit acknowledged that he threw the flat-iron at his mistress' head because she would give him no money and insulted him, and then, as she lay dying on the floor, that he cut her throat with the knife.

The necropsy revealed:—

1. On the hairy part of the head a large number (upward of twenty) of partly irregularly star-shaped, partly irregularly slit-like wounds, which crossed each other frequently, affected especially the occipital region, and most of which penetrated to the bones of the skull. In two situations over the parietal vault there are rectangular fractures, with terrace-like gradations directed to the left and forward. Their limbs are 1-1.5 cm. in length, and have a form as depicted in Fig. 101. Beneath them the inner table of the skull reveals rectangular fractures.

2. Three parallel, rather sharp-edged, slit-like lacerations of the scalp over the frontal bone. They have the length of a finger, and are directed anteroposteriorly. Of them the middle is noticeable because of its length and because its edges are loosened from the underlying tissues, particularly at its posterior part. Corresponding to this wound there is found a pointedly oval fracture, 4 cm. in length, and in the middle upward of 1 cm. in width. Its edges are arched and directed apart. It has a scaphoid depression in the direction of its long axis which corresponds to a somewhat longer, finely dentate fracture of the inner table pursuing the same course (Fig. 101).

3. A large number of irregular, slit-like wounds of varying length on the upper part of the face, with bases composed of irregular, uncovered soft parts. One of them, situate in advance of the left ear, continues as a dried linear abrasion transversely across the malar bone. In addition diffuse suffusion and scratches.

4. A destruction of the left external ear, the posterior border of which is almost completely separated from the remainder of the ear.

5. On the neck a transverse, widely gaping, sharp-edged wound, reaching from one sterno-cleido-mastoid muscle to the other, dividing the skin and various soft parts of the neck, and exposing the vertebral column. It runs parallel with the hyoid bone through the upper part of the larynx, sharply cutting the upper border of the thyroid cartilage, so that the larynx and the pharynx divided at the same height, are situate in the lower, and the epiglottis, the hyoid bone, and the upper anterior border of the thyroid cartilage in the upper part of the wound. At the level of the wound both thyroid arteries, and the left carotid with the vagus below the bifurcation, are transversely and completely divided, and the jugular vein of each side incised.

On the anterior surface of the vertebral column, corresponding to the bodies or the intervertebral cartilages of the second and third cer-





vical vertebræ, there are six deep, sharp-edged incisions, affecting the entire width of the bodies of the vertebræ, and distant from each other 2-3 mm. At the edge of the wound near the end on both sides there are notches as though incised, and from the angle of the wound on both sides one may follow—in the same direction externally as these—long, superficial breaks in the skin, looking like incisions.

6. On the anterior surface of the chest and on both upper extremities numerous ecchymoses, upward of the size of a dollar.

7. Contusion of the cortex of the outer surface of the temporal lobe, and also—and associated with rather marked intermeningeal hemorrhage—of the base of the right occipital lobe and of the under surface of both halves of the cerebellum.

8. On both sides, especially the left, various fractures of the ribs. Of these, one penetrated the pleura, lacerated the left lung, and gave rise to an extravasation of blood—about 100 c.c.—into the left pleural cavity. Circumscribed contusion of the right lung. A contusion the size of a half-dollar, of the upper external part of the left ventricle of the heart, with rupture of the epicardium. On the anterior wall of the stomach, directly under the cardia, a ragged rupture of the mucous membrane with a suffusion of coagulated blood half the size of the palm of the hand.

The body was almost completely, but especially the head and the upper part of the body, besmeared, and the clothes thoroughly saturated with blood. Everywhere marked anemia; the lungs rendered marmorate by aspired blood.

The opinion was expressed that the process of killing was by no means so simple as the accused asserted, but that the deceased had been killed by a large number of brutal injuries produced with different instruments, and that, in general, three varieties of injuries could be distinguished: those of the head, those of the neck, and those of the trunk and upper extremities.

Those of the head were evidently produced by the flat-iron—not by a single throwing of it, but by repeated violent blows with it. Of these, at least three—that is, those causing the rectangular terrace-like fractures of the skull—were made with a corner, the others probably with the edge of the implement. It was doubtless with the latter that the long sagittal injury over the hairy part of the frontal region was produced, as it is only thus that the elongated scaphoid fracture of the frontal bone can be explained, and not through a possible blow with the carving-knife.

The intermeningeal hemorrhages and the contusions of the brain-cortex were the results of these numerous blows.

The injuries to the neck were produced by a cutting-instrument, which was employed at least six times and always in the same direction—transversely across the anterior part of the neck. The carving-knife found on the accused was appropriate for this purpose. As, however, the knife was heavy, unwieldy, and not especially sharp (it was used in the house for splitting wood), it is not to be assumed that it was employed as another knife would be, by drawing it across the throat. It is much more probable that the injuries were produced by various blows made with the cutting-edge of the knife. This latter assumption was confirmed by experiments upon a body, which showed that it was impossible, with the knife in question, to cut through the throat, but that the latter could be readily divided by blows with the cutting-edge of the knife; and further, that—similarly as was the case with the deceased woman—one was able in cutting through the skin and soft

parts to produce a sharp-edged wound and precisely similar parallel incisions into the cervical vertebræ.

The various fractures of the ribs and the contusions of the internal organs (the lungs, the heart, and the stomach) permit the conclusion that in their production a third form of violence was used. They are readily accounted for by the supposition that the accused knelt upon the already prostrate woman, or, what is more probable, that he maltreated by kicking her.

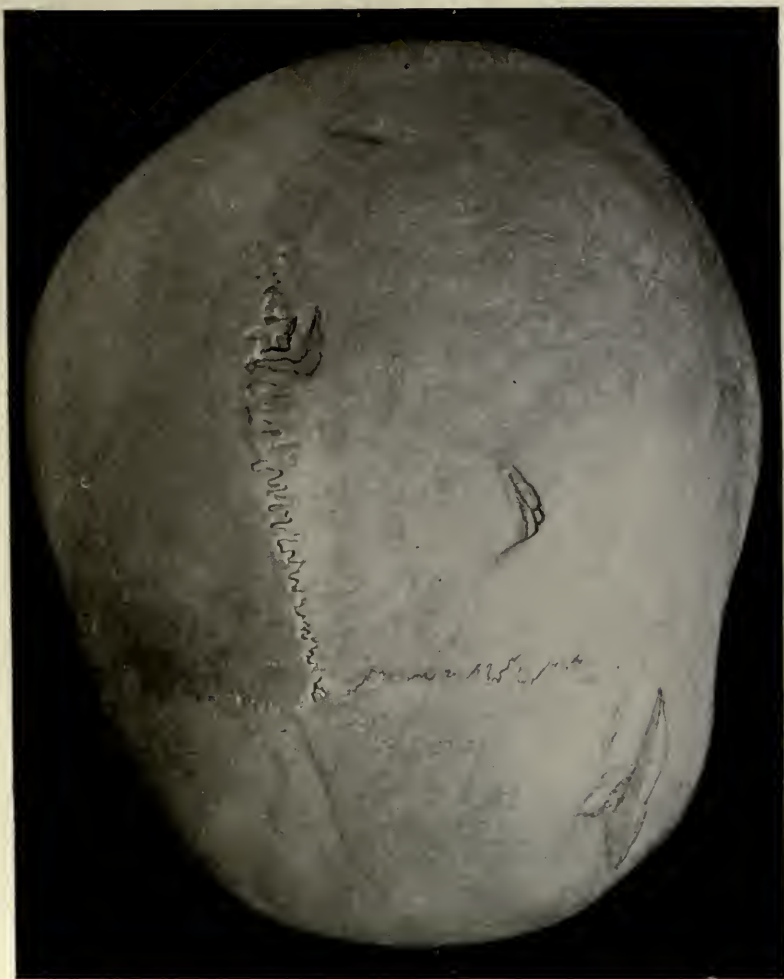The nature of these latter injuries, the multiplicity of the others, and the numerous contusions of the face and the upper extremities, demonstrate that without doubt the murder was performed with great rage and brutality.

As regards the sequence of the injuries, one can conclude from the marked hemorrhage and suffusion of the injuries of the head, in conjunction with the associated intermeningeal hemorrhage, that they were produced before the cutting of the throat. Were the contrary the case, the rapidly fatal hemorrhage from the cervical vessels would either have prevented their development or permitted of their development to a much less marked degree. The production during life of the wounds of the neck is indicated by the great amount of blood found externally and in the vicinity of the corpse, the marked external and internal anemia, and the marmorate appearance of the lungs caused by the aspiration of blood. As, in addition, the fractures of the ribs and the associated contusions of the internal organs were suffused with blood, and as the left pleural cavity contained 100 c.c. of blood, these injuries were produced either before, or simultaneously with, the cutting of the throat.

The evidence collectively considered justifies the assumption that the deceased was first felled with a flat-iron, and that as she lay prostrate upon the floor she was struck numerous additional blows with it; that at the same time her ribs were fractured by her chest being knelt upon or by her being kicked; that directly thereafter the injuries to the neck were produced by blows with the carving-knife; and that death resulted from hemorrhage.

The culprit was condemned to death by hanging, but his sentence was commuted to imprisonment for life.

Fig. 101.







## FIGURES 102, 103.

### Injury of the Lung the Result of Various Fractures of the Ribs.

A man, aged 44 years, with suicidal intent, jumped from the second-story of a house to the street and died immediately of internal hemorrhage.

At the necropsy there was found over a half liter of extravasated slightly coagulated blood in the left pleural cavity; a fracture of the sternum and of the pelvis; fractures of various ribs of the left side in the scapular line (FIG. 103); corresponding with this latter a deep longitudinal, almost slit-like laceration of the posterior surface of the lower lobe of the left lung (FIG. 102); an irregular laceration of the pericardium; a rupture of the left auricle; and numerous ruptures of both ventricles affecting only the endocardium and the adjoining layers of the muscular substance—one of which, however, extended to the epicardium.

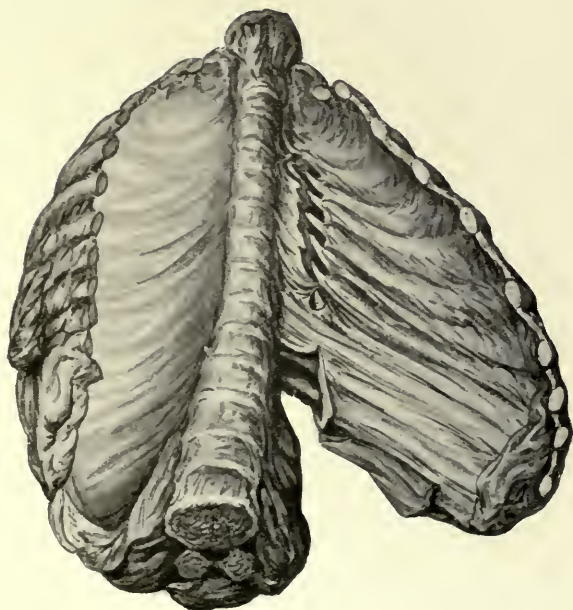
The man evidently fell upon the anterior surface of the left side of his chest, whereby, on the one hand, the heart was compressed between the sternum and the thoracic vertebræ and thus ruptured, and, on the other, the already mentioned fractures of the ribs—all in one line—were produced. The outer pointed ends of the fractured ribs—as is visible in the illustration—perforated the pleura as the teeth of a giant-comb and penetrated deeply into the posterior surface of the lower lobe of the left lung, giving rise to the large slit-like laceration.

Developed to a less degree one sees injuries of the lungs—generally punctured wounds—produced by penetration of the broken ends of fractured ribs. These may sometimes be of very great depth.

Fig. 102.

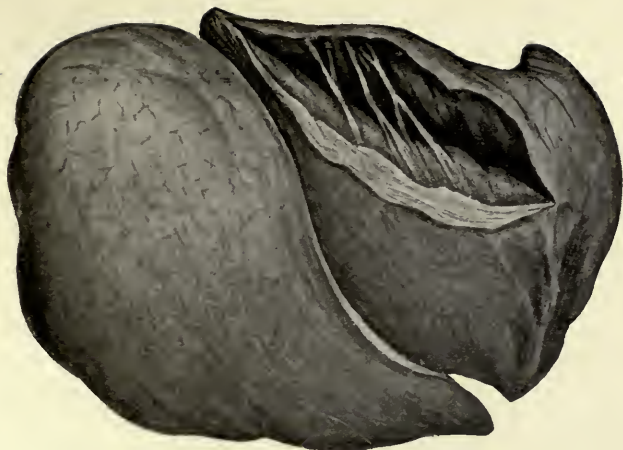

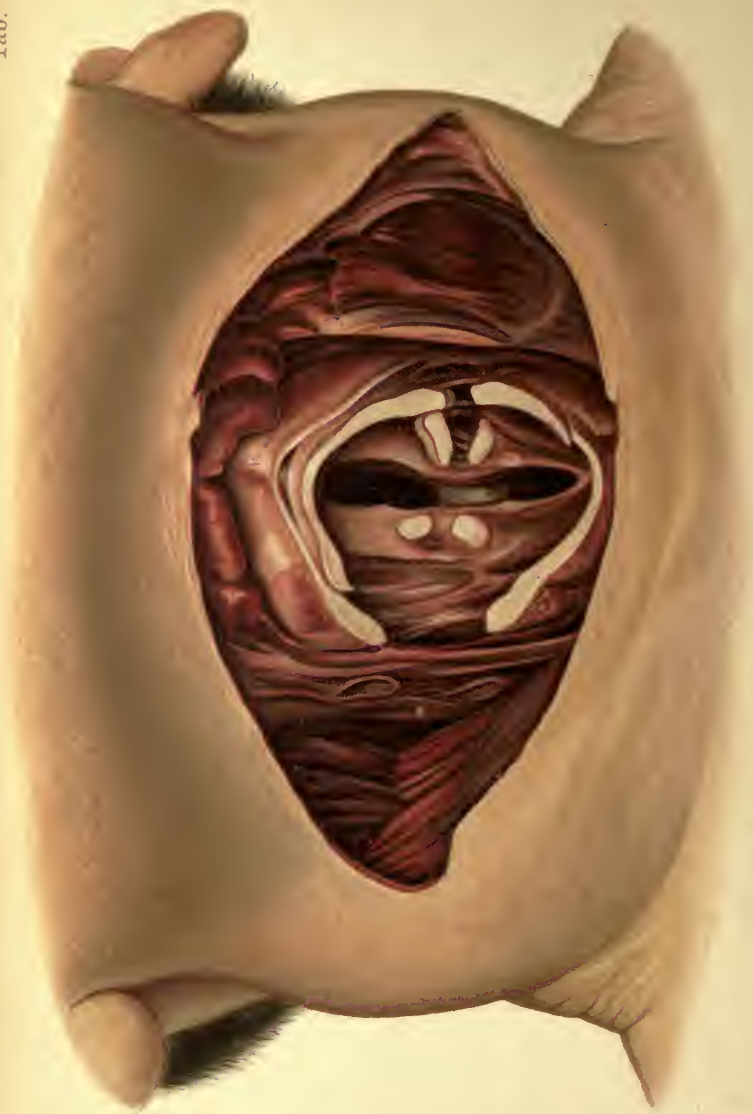Fig. 103.









## PLATE 16.

### Suicide by Cutting the Throat.

The case was that of a young man in his twentieth year, who cut his throat in his room with a sharpened pocket-knife. He was found dead, on his back, in a moderate-sized pool of blood, his right hand covered with blood, and beside this a bloody pocket-knife.

After cleansing the body the skin was not especially anemic, the post-mortem lividity fairly well developed, the visible mucous membranes not particularly pale, the wound of the neck running transversely from the middle of one sterno-cleido-mastoid muscle to the other. The edges of the skin-wound were sharp and joined on both sides to form an acute angle. In the upper, as well as in the lower edge, one notices near the median line a shallow notch—an indication that at least two incisions must have been made. The entire cartilaginous larynx in the direction of the longitudinal axis of the wound is cut through twice above the middle of the thyroid cartilage, the upper incision being transverse, the lower somewhat depressed to the left. The section (evidently the lower) then runs transversely between the upper and lower vocal cords, and divides the arytenoid cartilages of both sides, behind which it opens the pharynx.

Of the arteries, only a branch of the poorly developed thyroid artery of the right side and the right internal jugular vein are divided. The throat, the esophagus, the larynx, and the trachea are filled with a considerable quantity of recent blood-coagula, which extend on both sides deep into the bronchi. Both lungs are turgid, and on section reveal numerous marmorate areas due to aspirated blood.

From the preceding it follows that in the present case death was not due to a fatal hemorrhage, but resulted from suffocation consequent upon entrance of the blood from the wound into the larynx and the lower respiratory passages.

Worthy of note is the distinct prominence of the lateral portions of the neck about the ends of the large wound. These were produced *intra vitam* by the retraction and the consecutive thickening of the stumps of the sterno-cleido-mastoid muscles, which were in great part divided.

## FIGURES 104, 105.

### Suicide by Cutting the Throat.

FIG. 104.—One can distinguish on this suicide, aged 43 years, four transverse wounds which are situate closely together and parallel, in the region of the larynx. Two incisions are superficial, scratch-like; the third, evidently due to the union of two, gaping and deep. The section of skin in question, in order to render visible the deeper injuries, is displaced upward and there fastened. The larynx thus exposed shows, about the angle of the ossified thyroid cartilage, four transverse incisions close together, penetrating into the lumen of the larynx. Of these, the lowest to the right goes through the entire thyroid cartilage, and divides the deep cervical vessels with the vagus nerve. Six incisions were therefore made; of these, two affected only the skin, and four the larynx; and of the latter, the lowest the deep vessels of the neck.

The body revealed the characteristic signs of death from hemorrhage. The instrument employed was a rather sharp, strong pocket-knife.

FIG. 105.—Larynx of a man, aged 50 years, who had cut his throat. Three parallel incisions, symmetrically arranged, transversely above the thyroid cartilage. Of these, the highest penetrates between the larynx and the hyoid bone, partly dividing the epiglottis; the second extends into the upper vocal cords; while the third, and lowermost, does not open the larynx at all. The band of tissue, but  $\frac{1}{2}$  cm. wide between the uppermost and the second incision, is divided irregularly and obliquely in the middle. This may have been due to a fracture produced by excessive pressure of the not especially sharp blade.

The deep vessels of the neck were uninjured; but, on the other hand, on both sides the external jugular vein and the superior thyroid artery were divided and there was blood in the larynx and trachea.

Fig. 104.

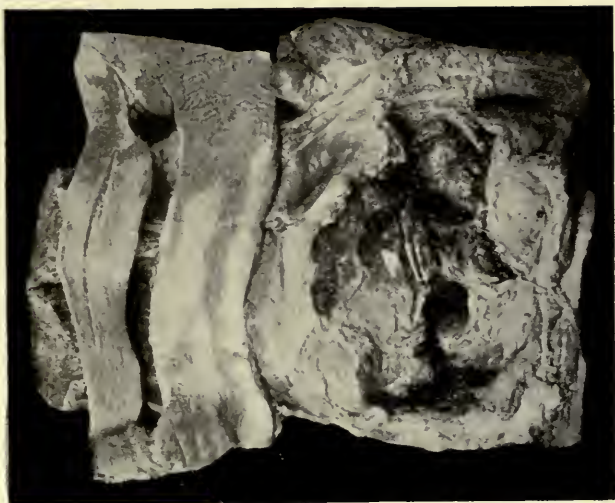


Fig. 105.

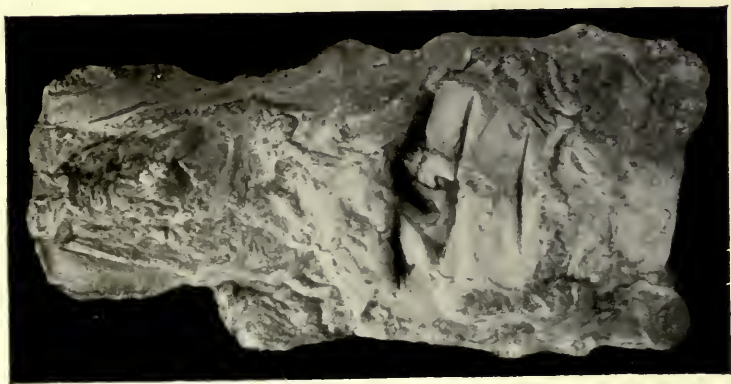
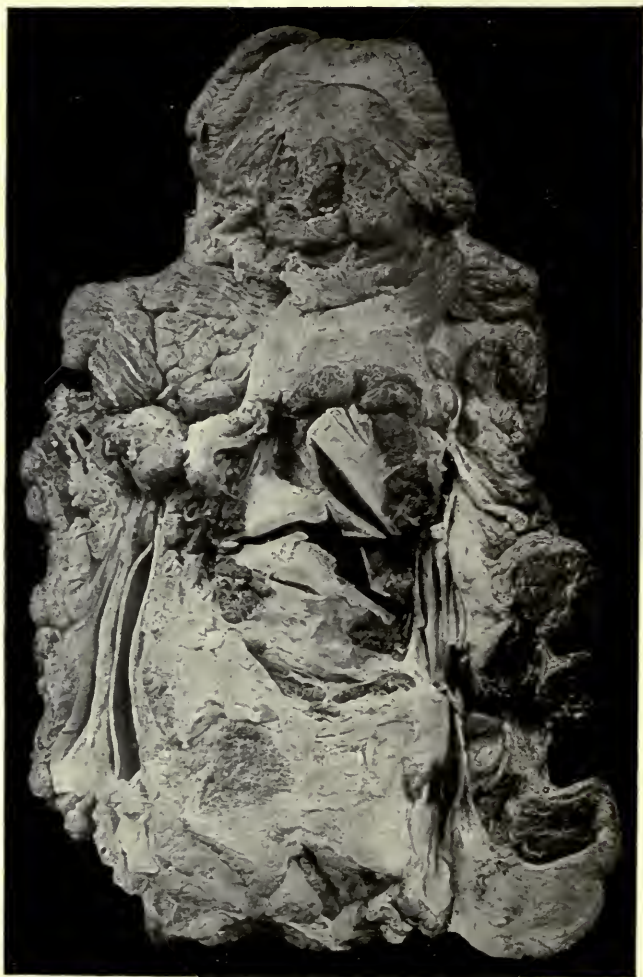





Fig. 106.



## FIGURE 106.

### **Suicide by Cutting the Throat.**

J. E., aged 28 years, a medical student, was found dead in a restaurant in a room closed from within, with his throat cut. The body lay in a large pool of blood and was already rigid.

In the neck there was found a transverse, sharp-edged wound, which extended from one sterno-cleido-mastoid muscle to the other, and the upper edge of which, to the left, revealed an incision 3 cm. in length. The larynx, situate in the bottom of the wound, shows immediately above the vocal cords a sharp-edged, transverse incision extending to the mucous membrane of the posterior wall, and in addition six partly transverse, but mostly oblique incisions running from the left below to the right above. They have sharp edges and penetrate into the lumen of the larynx.

Both sterno-cleido-mastoid muscles are divided—the left completely, the right all but a small portion. To the right the superior thyroid artery, to the left the large deep veins of the neck, and on both sides the jugular veins are cut. The entire body is markedly anemic, the larynx and the bronchi contain some coagulated blood, and the lungs are here and there rendered marmorate by aspirated blood.

The case is of interest, because, had the circumstances been suspicious, the numerous incisions into the larynx and their varying direction might have led to a supposition of murder.

## FIGURE 107.

The figure shows the body of a 4-months-old, vigorous child, which was experimentally pierced with a pointed conical instrument having a width of  $\frac{1}{2}$  cm. at its base. The wounds were made, in the first place, to show the regular cleavage of the skin; and, in the second place, to demonstrate the important fact that a conical instrument does not—as one might suppose, and was formerly taught—produce round punctures, but slit-like openings. These latter are distinguished from those produced by knives only by their determinate direction—corresponding to the local cleavage of the skin—and by their limited extent.

The regular cleavage of the skin is recognized in the regularity of the curves in which the wounds encircle the body and its extremities. To the second rule there is an exception only inasmuch as at those places where the curves join to form parabolic triangles the openings have not a slit-like form, but rather a shape like an arrow-point or a triradiate, star-like form.

---

## FIGURE 108.

### **Numerous Punctured Wounds of the Stomach Produced with a Conical-shaped Instrument.**

The figure in question is intended to demonstrate that—similarly as the skin—other organs, especially the stomach and the intestines, possess a regularity of cleavage. This becomes manifest upon puncturing the organs with conical or blunt-edged instruments, and indicates that the wounds were caused by such, and not by a cutting-instrument (knife). This latter, without regard to the local cleavage, divides the tissues only in a line with its cutting-edge.

The stomach was filled with liquid tallow, and, after this had become stiff, was pierced with a conical instrument 5.5 cm. in length and 5 mm. in width at its base. No choice whatever of the points of puncture was made. It was found that the punctures produced had arranged themselves into regular curves, and that each puncture was made up of three slit-like openings corresponding with the coats of the wall of the stomach. Of these, the most external—that appertaining to the peritoneum—assumed a direction parallel with the course of the curvatures of the stomach; that beneath—in the muscular coat—a direction at right angles to this, and that in the mucous membrane still another direction. Hence it follows that a regular cleavage is possessed by each coat of the stomach, and that when a non-cutting instrument penetrates the wall of the organ the division of each coat follows in a different but constant direction.

Fig. 107.

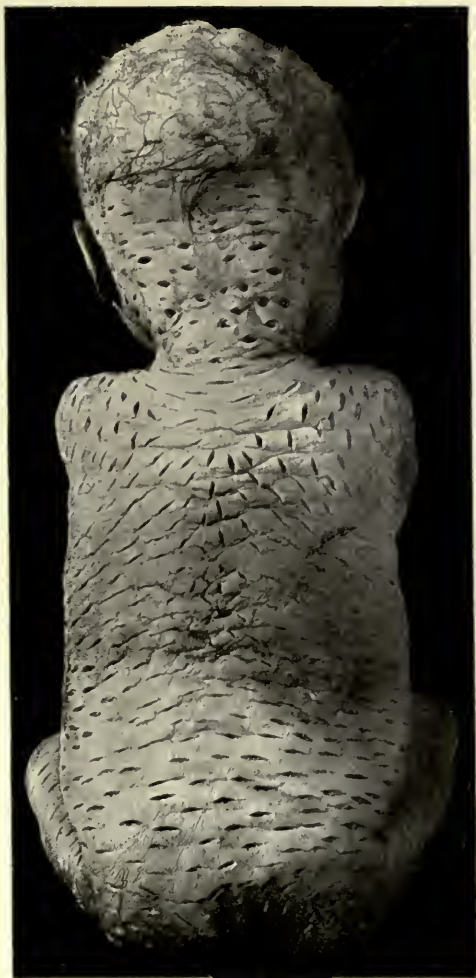
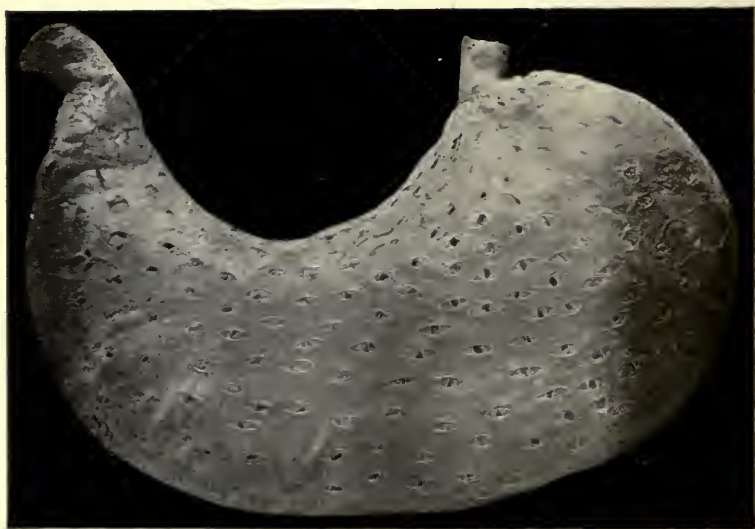




Fig. 108.



## PLATE 17.

### Suicide through Stabbing.

This case is that of a physician who had taken his life in a hotel. His body was found lying upon the left side, behind and across the doorway of the room, so that at first it was not possible to open the barred door. The body was almost entirely covered with freshly coagulated blood, and clothed only with a shirt, which was saturated with blood, opened from the front, and thrown backward. Extensive blood-marks reached from the body to the bed, the covering of which latter was likewise saturated with blood, and beside which a large, open pocket-knife lay.

The position of the arms and hands is evident from the illustration.

After cleansing the body six stab-wounds were recognized. Of these, one was situated in the right side of the neck, the other five on the anterior surface of the chest. All of the wounds had a slit-like form, and showed throughout sharp, arched, separated edges, which on both sides joined to form acute angles and between which there was a collection of coagulated blood. This latter was continued to the left beyond the wound as a dried streak, in which direction the blood had probably flowed at the first turning of the body.

The wound of the right side of the neck was transverse, 3 cm. in length, with its edges apposed. It continued into the depths of the neck as a wedge-shaped canal gradually decreasing in size, which, beginning at the middle of the inner edge of the sterno-cleido-mastoid muscle, continued from before backward and somewhat from within outward directly to the transverse processes of the middle cervical vertebra. It opened in its course the outer wall of the right carotid artery, and cut the jugular vein transversely, without injuring the vagus nerve.

Of the wounds of the chest, the uppermost one was situated three fingers' breadth below the middle of the left clavicle. It penetrated directly anteroposteriorly the second intercostal space and ended in the lung, which was tuberculous and, at this point, partly adherent to the pleura.

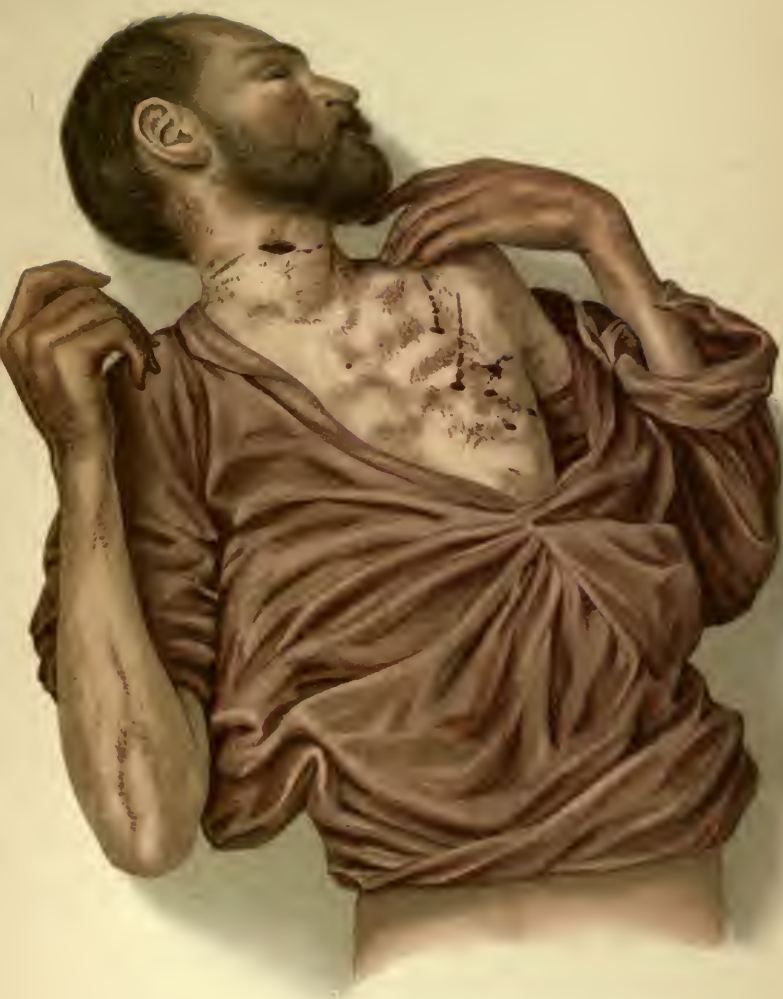The other four wounds were confined to an area of the chest half the size of the palm of the hand in the region of the left nipple, and corresponded with the previously mentioned one in that they were almost transverse. They also penetrated in the direction from before backward, partly with injuries to the ribs, the chest-wall, or the intercostal spaces, and ended in the antero-external part of the upper lobe of the left lung, into which, as six slit-like openings 4-7 mm. in length, they penetrated a distance of 1-3 cm. In the left pleural cavity there were about 300 c.c. of partly fluid, partly coagulated blood. Closer investigation revealed that the external openings of two of the wounds showed notches in

their edges, and that one of them corresponded with a double slit-like opening in the pleura. It follows therefore that these openings were punctured twice; and, further, that with five punctured openings in the skin, seven were found in the lung.

That it was a case of suicide was demonstrated by the external circumstances and all the postmortem findings. It was clear that the deceased had produced the wounds while in bed, and that he had then attempted to arise and go to the door, where he fell. Excluding these facts, the opened and uninjured shirt, the symmetric disposition of the openings of the stab-wounds and of the course of the canal of the wounds, and the proximity of the wounds of the chest, as likewise the fact that into two of the wounds punctures were made twice, were more indicative of suicide than of murder.

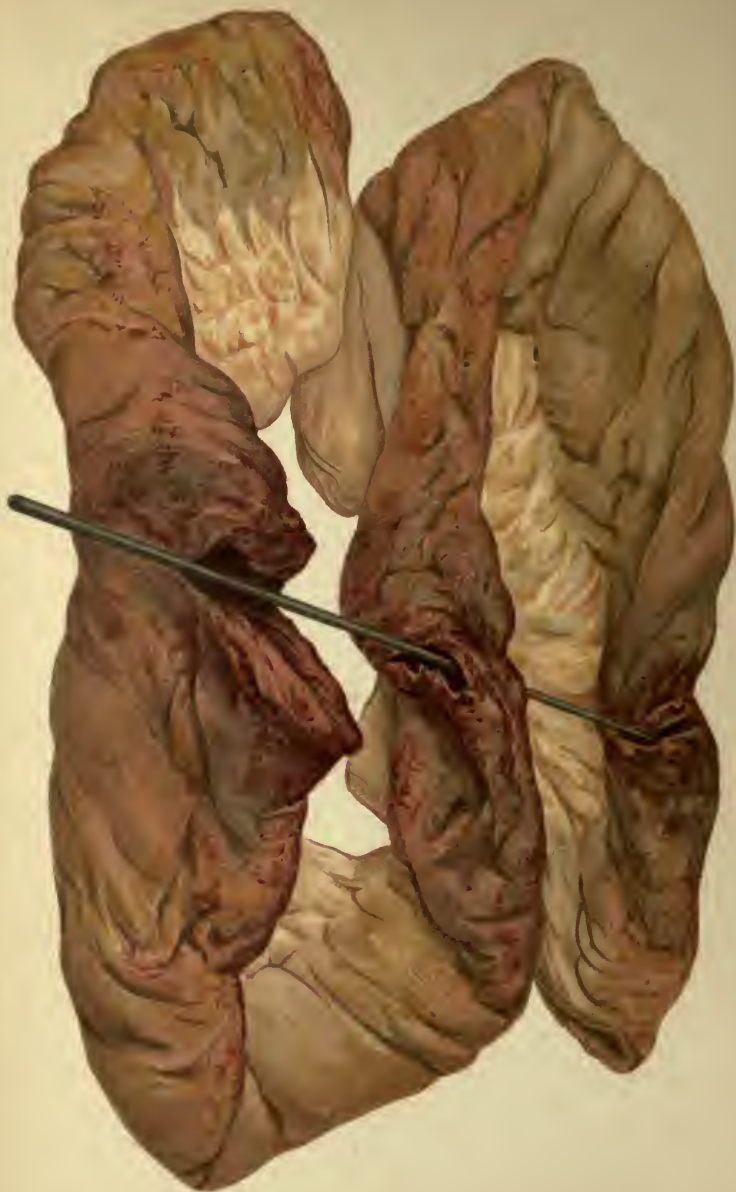The course of the puncture-canals, especially that of the neck, permit the supposition that the stabs were done with the left hand, and inquiries revealed that in reality the deceased was left-handed.

The motive for committing the deed may have been the tuberculous disease.









## PLATE 18.

### Triple Injury to the Small Intestine Produced by a Stab. Peritonitis.

Sch. J., aged 49 years, the evening of October 21st, during a quarrel before a brandy-shop, was stabbed with a pocket-knife in the abdomen, and died two days later, having declined an operation.

The necropsy, performed October 25th, revealed externally, one finger's breadth to the inner side of the right anterior iliac spine and three fingers' breadth above Poupart's ligament, running parallel with the latter, a slit-like, gaping, sharp-edged wound, 3.5 cm. long and 11 mm. wide. Its outer end is pointed, its inner rather blunt. Its upper edge is rather straight, its lower arched outward. The base of the wound is formed by somewhat discolored musculature, and the wound itself grows deeper beneath its inner edge. Following in this latter direction, one discovers that the wound penetrates the entire abdominal wall, and that—corresponding with the external wound—there is in the peritoneum a sharp-edged, acute-angled slit, 17 mm. in length.

In the abdominal cavity there is a large quantity of discolored, opaque fluid containing flocculi; the peritoneum throughout, but especially in the lower portion, markedly injected in spots; and the viscera—particularly those in the right lower quadrant—united with each other and with the peritoneum by means of pyofibrinous exudate.

Opposite the wound in the abdominal wall there is a coil of small intestine about 1 m. from the cecum, which is sharply and transversely divided on its convexity, so that there remains but a bridge of intestine—2.5 cm. in width—posteriorly, corresponding with the insertion of the mesentery. About 15 cm. above this point the intestine is pierced by two likewise transverse, sharp-edged slits, situate opposite to each other. Of these the lower measures 2 cm., the upper 1.5 cm. Again, 15 cm. above the latter point there is a longitudinal opening in the lower wall of the intestine, 1.5 cm. in length. The wounds—from all of which the intestinal contents escape—are situate in one direction, and show edges covered with exudate and discolored blood-coagula. The mucous membrane throughout is cloudy, congested, swollen and everted, as is the rule in recent penetrations of the intestine and in those occurring during life.

We recognize, therefore, in this case three injuries to the intestine produced by a single stab with a knife. They are at the same time instances of the three most common stab-wounds of the intestine: the division of the wall of the intestine, the single and the double perforation.

## FIGURES 109, 110.

### Fig. 109.—Stab-wounds Produced with a Four-cornered Picture-nail.

The vault of the skull of a woman, aged 77 years, who was found dead, lying in a pool of blood, August 3, 1882. The body revealed *in toto* 38 stab-wounds, of which 32 were on the head and face. Of the latter, 11 extended to the bones of the skull, 4 penetrated the external table, and 3 the entire thickness of the bones of the cranium. These latter corresponded in situation with penetrations of the meninges and injuries to the brain-cortex, with extensive extravasation of blood. One situated in the occipital region penetrated even to the pons Varolii.

The stab-wounds of the skin were partly slit-like, partly star-shaped, whereas those of the bones of the skull were quadrate and sharp-edged. The largest was situated in the posterior portion of the left temporal region and had a diameter of  $\frac{1}{2}$  cm.

It was therefore evident that the perforations had been made with a four-cornered instrument. And in reality there was found in the blood beside the body a large iron nail, a so-called mirror-hook, such as is used for hanging heavy pictures. It had a length of 17 cm. and was 1 cm. in width at the base. It was four-cornered, pointed at one end, and fitted exactly into the openings in the skull, so that there was no doubt that the nail was the instrument employed in causing the injuries.

That the woman had been murdered there could be no question, as most of the stab-wounds affected the occipital region, and as, further, there were stab-wounds of the face and of both hands; in addition, the inferior maxilla was fractured.

The culprit was not discovered.

---

### Fig. 110.—Punctured Wound in the Parietal Bone Produced with a Knife.

The wound was produced with a large pocket-knife. It shows distinctly the form of a transverse section of the knife-blade, and indicates in which direction the cutting-edge and that in which the back of the knife were held. Of the edges of the fracture in the external table of the skull, the anterior one, at the wide end of the wedge, is somewhat indented; the others, as also the back of the wedge, are sharp. On the other hand, the vitreous table was broken off along both edges.

Death resulted from intermeningeal hemorrhage.

Fig. 109.



Fig. 110.

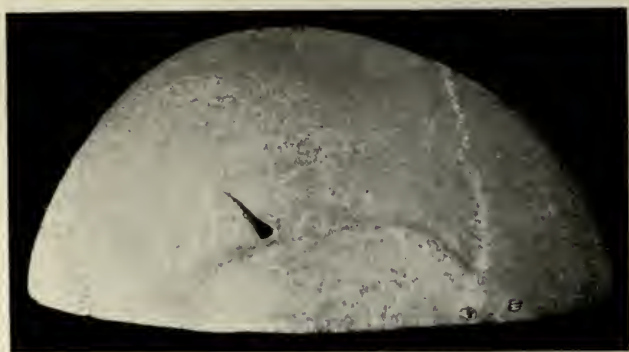






Fig. III.

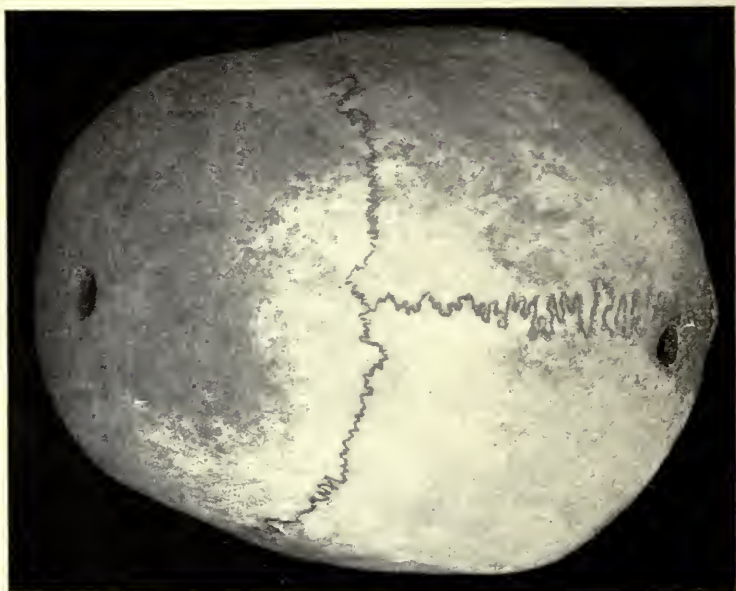



Fig. II2.



## FIGURES 111, 112.

FIG. 111.—Vault of the skull of a young man, who, with suicidal intent, drove into his head two heavy bolts (designed for hanging lamps) and then threw himself from a window. Death resulted from internal hemorrhage consequent upon rupture of the liver.

The punctured wounds are almost 1 cm. in width and completely round. The meninges were penetrated on both sides and the brain-cortex injured.

---

### **Fig. 112.—Punctured Wounds Produced with a Sharpened Three-cornered File.**

Three of the wounds have the form of a triradiate star, produced because each of the cutting-edges of the file had cut into the skin. Two others, although produced by the same instrument, are irregular, either because folds of the skin were punctured, or because several punctures were made into these places.

## FIGURES 113, 114.

### **Punctured-incised Wounds of the Left Hand Received in Self-defence.**

The wounds were found on a man, aged 47 years, who was killed in a brawl, having received twenty-four stab-wounds with a knife on the head and nine on the thorax.

The dorsal surface of the left hand and the adjoining portion of the forearm, illustrated in FIG. 113, show six punctured incised wounds. Of these, three are slit-like and affect the dorsal surface of the hand, and one the extensor side of the forearm, whereas the other two are tangential slits of the skin, one being situate on the ulnar side of the first phalanx of the middle finger, the other above the head of the ulna.

On the palmar surface of the hand—FIG. 114—in addition to the continuations of the two last-mentioned tangential slits, one sees three slit-like wounds upward of 1 cm. in length in the palm of the hand, and three similar, rather shorter wounds at the junction of the hand with the forearm.

All of these wounds are situate without regularity and penetrate deeply into the subcutaneous connective tissue, without there being demonstrable any communication between the wounds on the dorsal and those on the palmar surfaces of the hand.

They are evidently stab-wounds made by a knife, received in self-defence. Their presence in such number is accounted for by the great number of other wounds on the head and chest with which they are in relationship.

Fig. 113.

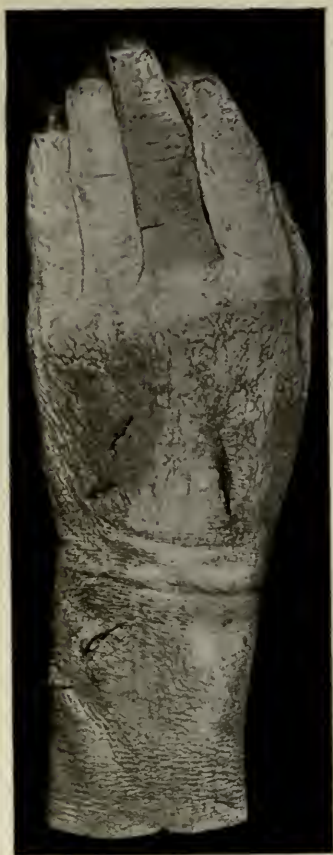

Fig. 114.

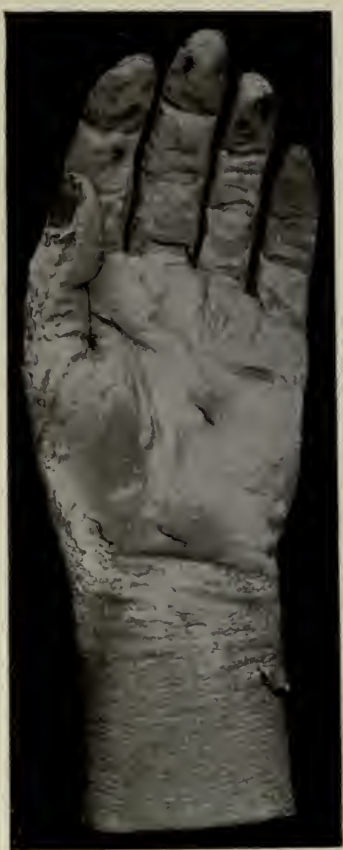





Fig. 115.



## FIGURES 115, 116, 117.

### Murder Produced with a Fascine-knife.

FIG. 115.—During the night of October 27, 1885, M. S., a prostitute, aged 23 years, was found dead and apparently murdered.

After cleansing the head, which was entirely covered with blood, there were found externally the injuries evident from the accompanying illustration, which was prepared in accordance with the skin of the head, which had been preserved. The injuries are: 1. A slit-like incision with sharp edges, 4.5 cm. in length, directed anteroposteriorly over the left frontal protuberance. Extending to the bone beneath—which is fractured in the same direction—half of it affects the non-hairy, half the hairy, portion of the forehead. 2. Three almost slit-like incisions transversely through the left temporal region. They have sharp edges and upward the length of a finger; they are equidistant from each other 2 cm.; they are directed through the external ear and penetrate to the bone. The middle and lowermost ones divide the tragus and the antitragus. The uppermost one, after an intermission of 1.5 cm., continues as an incision—1 cm. in length, affecting only the upper layers of the skin—which courses over the cheek beneath the malar bone. 3. A slit-like wound along the lower border of the inferior maxilla. It has sharp edges, is 3 cm. in length, and penetrates to the bone.

FIG. 116 shows the fractures of the skull corresponding to the external wounds. In the first place, beneath the first-mentioned wound, there is a gaping fracture of the frontal bone 4.5 cm. in length and 3-4 mm. in width. Like the wound, it is directed anteroposteriorly, and its edges at both extremities approximate to form acute angles. For a short distance beyond this gaping fracture there is a fissured fracture of the frontal bone which runs in the same direction. There is no associated laceration of the dura mater, but there are contusion and suffusion of the inner meninges and those frontal convolutions situated beneath. The inner edges of the fracture are bevelled and in the middle broken off; the external are sharp and pointed. There is a partial fragmentation of the inner table.

The temporal muscle beneath the second-mentioned wounds is much incised, some of the incisions revealing a slit-like character. The temporal bone throughout its entire extent and the parietal bone in its lower part are extensively fractured. Among the fractures, however, there are three principal ones which pursue courses similar to those of the cutaneous wounds, and which in part have a distinct fissure-like character. There are much laceration and contusion of the meninges and of the brain beneath, with extensive blood-coagula.

From the form, length, and course of the cutaneous wounds and of the fractures of the bones it was concluded that they had been produced

by blows with a weighty instrument having a rather blunt edge, and that this instrument might have been—that it even probably was—a saber, or a similar instrument. It was also inferred that in all probability the blow over the forehead was the first, and that the others were inflicted upon the already prostrate and unconscious woman. The latter supposition is borne out by the number and the parallel course of the wounds.

There could be no possible doubt that the case was one of murder, as in addition to the above-mentioned injuries the first phalanx of the left thumb with the nail was almost completely severed. This injury was probably received in endeavoring to ward off a blow.

Numerous spermatozoa were found in the vaginal secretion; but from this fact—because of the occupation of the woman—one may not with certainty draw the inference that the murderer had coitus with her immediately before killing her.

### Fig. 117.—Saber-blow.

F. N., aged 43 years, during a labor-strife, received a blow with a saber from a gendarm, and died of encephalitis and meningitis as a consequence thereof, at the end of 14 days. Of the injury to the skull one can readily distinguish the fracture due to the blow, and in addition, proceeding from the latter, a lamelliform separation of a large section of the parietal bone. The fracture due to the blow is arched, with the convexity forward. It extends from the anterior temporal portion of the right parietal bone to the parietal eminence, a distance of 10 cm. The characteristics of the fracture are most marked at its central portion, where one can distinctly recognize the anterior smooth bevelled and the posterior pointed edges. Posterior to this fracture there is an oval plate of bone the entire thickness of the skull—10 cm. in length and 5.5 cm. in width—which is separated and can be thrown back as a flap. Thus, through an elongated oval opening of the same size as this section of bone, one may view the interior of the skull. The anterior edge of the opening is smooth and bevelled, the posterior irregularly fractured. This separated plate of bone is transversely fractured at its upper part, while at the middle of its anterior edge—at that part where the characteristics of the saber-fracture are best developed—there is a small, isolated, oval fracture of the margin of the bone. It is 4 cm. in length and 1.3 cm. in width, and affects only the outer table.

Fig. 116.

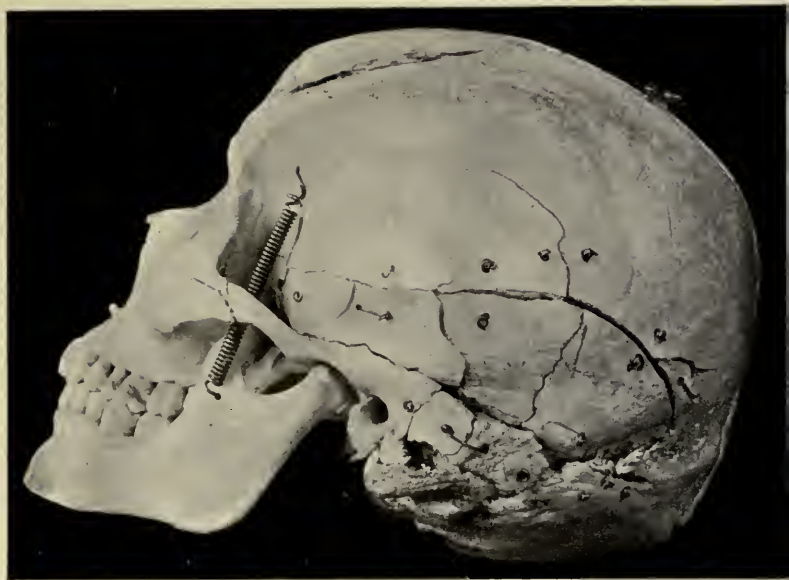

Fig. 117.







Fig. 118.

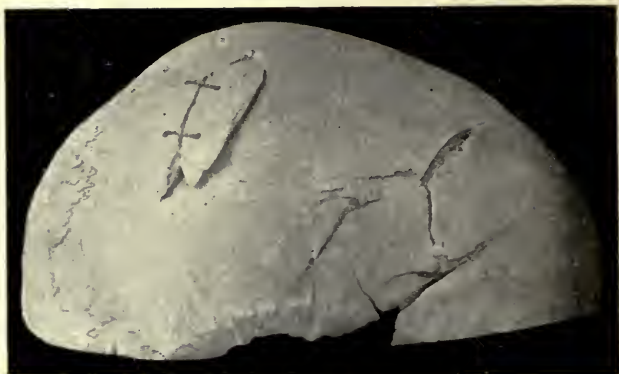



Fig. 119.



## FIGURES 118, 119.

### **Fig. 118.—Murder Caused by Numerous Hatchet-blows.**

The vault of the skull of a woman, aged 43 years, who with her four children was murdered by her husband, who at the time was in a state of delirium tremens. The woman was killed by blows with the cutting-edge of the hatchet and subsequent cutting of her throat, the children simply by cutting their throats with a kitchen-knife. The murderer, who also cut himself in the left thoracic region, died a few months subsequently in an insane asylum.

One notices on the right side of the skull four almost parallel fractures caused by the blows. The three anterior ones are rather simple fissures. Of these, the middle and at the same time the uppermost one penetrates obliquely from behind forward, and at its anterior part is associated with an elevation of the bone. The fourth fracture, situate in the region of the parietal eminence, penetrates the entire thickness of the bone obliquely from before backward. Its forward edge is arched, with the convexity anterior, and is sharp, smooth, and bevelled. Its posterior edge is pointed, and, with an oval plate of bone the thickness of the skull, is broken off and can be displaced backward as a flap.

FIG. 119.—Vault of the skull of a man, aged 54 years, who died in consequence of a saber-blow received from a policeman.

Two and a half fingers' breadth behind and running parallel with the left coronary suture there is a linear fracture with sharp edges, 3.5 cm. in length; and posterior to this a pointedly oval fracture of the same length and 1 cm. in width at its center. The latter is depressed anteriorly 1-2 mm. The vitreous table is fractured beneath to a somewhat greater extent, but in similar form. A fragment of bone from the anterior edge of the fracture had lacerated the middle meningeal artery, giving rise to an extensive flat extravasation of blood between the dura mater and the bone. The saber was not sharp, and in consequence did not produce a fissured fracture, but such an injury as would an angular instrument.

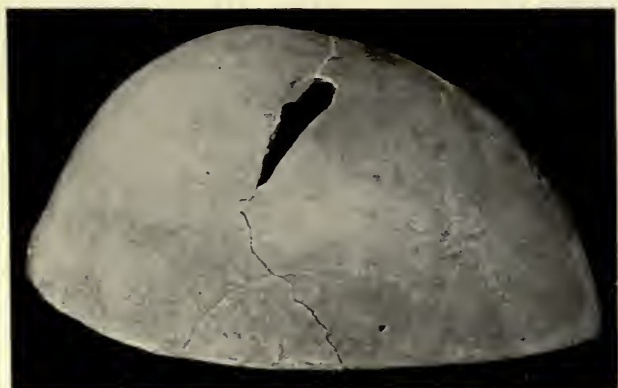FIGURE 120.

**Hole-fracture (Lochbruch) Produced by a Blow with the Cutting-edge of a Hatchet.**

In Vienna, in 1884, a banker and his two-children were killed by anarchists. On the body of one boy there was found a roundish fracture in the occipital region; on that of the other a regular rectangular fracture (lochbruch) with dentate edges, in the middle of the frontal bone (illustrated in my textbook, seventh edition, page 457). On the body of the father, however, there was found the wedge-shaped fracture of the right parietal bone depicted in the accompanying figure. It has a length of 4.5 cm. and, at the base of the wedge, a width of 1.1 cm. Its apex is directed to the right and below. The forward edge of the fracture is sharp, the posterior in its upper part indented; the inner table on both sides broken off. The fragments of the latter, as also the section of bone from the larger fracture, were driven deeply into a fissure-like laceration of the brain-substance. From the base of the fracture another extends to the interparietal suture, and from the apex still another, which latter runs forward and below to the middle fossa of the skull.

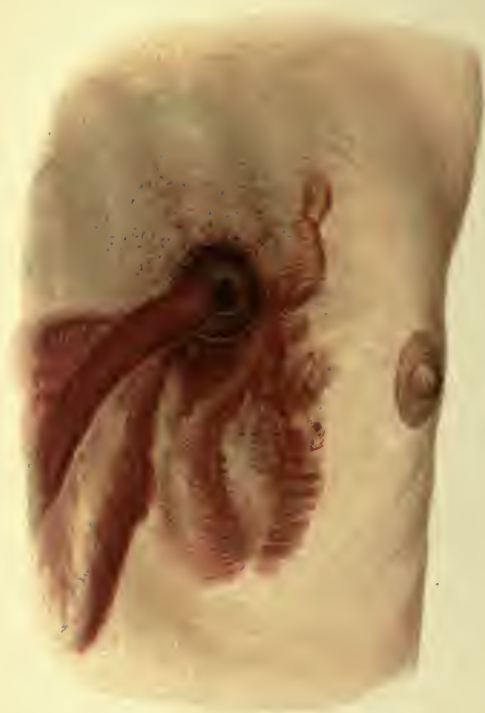It was evident that the injury was produced by the cutting-edge of a hatchet-like implement, and as the fractures of the skulls of the two boys were of a totally different character, one might readily suppose that two or three implements had been employed, or that the murders had been committed by two or three persons. There occur, however, hatchet-like instruments (so-called beilstöcke) which are commonly employed in the households of Vienna. They possess, in addition to a cutting-edge, a prominent back with a circumscribed four-cornered striking-surface. One must, therefore, concede the possibility of all three injuries having been produced with the one instrument and by the one person—the cutting-edge being used in one instance, the back of the implement in killing the boys. As a matter of fact, it was subsequently determined that one anarchist was the murderer. As others kept a lookout, he committed all three murders with a so-called fokos (a short beilstock or hatchet). He first killed the banker with the cutting-edge of the implement, and then, as the boys came running to their father, he felled each with a blow with the back of the hatchet.

Fig. 120.









## PLATE 19.

### **Close-range Gunshot-wound in the Region of the Heart Produced with a Revolver of 9 mm. Caliber. Natural Size.**

Two fingers' breadth to the inner side and a little above the left nipple there is a circular opening, 4 mm. in diameter—looking as though produced with a punch. It has blackened edges and a black base, and to the right of it there is a dried streak of blood. The perforation is situate in the middle of a likewise circular, dried, leather-like, brownish-black area, which latter in turn is surrounded by an irregularly round and indistinctly limited zone, about the size of a dollar. The latter is much excoriated and is beginning to become dried. The entire region was originally covered with powder-dust, after the removal of which a second discoloration persisted. This latter is especially marked in the upper half of the outer excoriated zone, and consists of numerous black points which cannot be washed away, and which have been produced by unexploded or but partially exploded grains of powder. Finally, one notices, after cleansing the wound of entrance and the adjoining parts, still a third—the most external—zone. It is the size of the palm of the hand and extends to the left, beyond the nipple. The skin over it is slightly prominent; it is doughy to the touch and bluish in color.

Examining the individual details of this gunshot-injury more carefully, one finds that the circular perforation was without doubt caused by the bullet; but as the opening measures only 4 mm. in diameter, while the bullet measures 9 mm., the wound of entrance is much smaller than the projectile. This is only to be explained by assuming that the skin retracted after the occurrence of the perforation, occasioning a diminution in the size of the opening. When there does not occur a laceration of the wound, due to the direct force of the explosion—such as happens in shots from the immediate vicinity with large weapons—the bullet causes a funnel-shaped inversion or stretching of the skin. At the same instant it perforates the apex of the funnel, permitting retraction of the remainder of the stretched skin. By this procedure the inner surface of the cone-shaped inverted portion of the skin becomes abraded and forms, after the occurrence of the perforation, the inner leather-like dried zone, which one generally, though incorrectly, designates the “burnt margin.” The circular form of its limitation corresponds with the extent of the skin which was inverted, and approximately, therefore, with the caliber of the bullet. Of the occurrence of these phenomena one can satisfy himself by shooting through a tense plate of India-rubber.

The edges of the “burnt margin” in close-range shots are usually undermined to a considerable extent, particularly when the weapon is held in close apposition to the body. In addition, the edges of the perforation are blackened with powder, this being an important characteristic of close-range shots. The undermining is due to the direct

action of the exploding gas, which penetrates between the skin and the firmer structures beneath (the wall of the thorax, the skull, etc.).

The zone surrounding the "burnt margin" is the result of the contusions of the skin produced by the exploding gas, being possibly also due to singeing of the tissues. The blackening on and in this area is caused by the powder, that which could be washed away being due to the powder-dust, that which is scattered and punctiform being due to inclusion within the skin of grains of powder.

On the other hand, the external bluish area, the size of the palm of the hand and doughy to the touch, is due to the suffusion of blood which had collected in the subcutaneous and intermuscular tissue in the neighborhood of the wound.

---

## FIGURES 121, 122.

### **Fig. 121.—Suicide with a Carbine.**

The perforation, situate in the region of the heart, is an irregular opening 12 mm. in diameter. It has somewhat serrated edges and is blackened both externally and in its depths. Quite an extensive area about the wound is diffusely blackened, and the adjoining hairs are singed.

The channel of the gunshot-wound is directed from before backward and penetrates the heart, extending to the thoracic vertebrae. In one of the latter a conoidal shot, but slightly deformed, was found. This gunshot-injury is therefore not essentially different from that produced with a revolver of moderate caliber.

---

### **Fig. 122.—Gunshot-wound of the Right Temporal Region Produced with a Double-barrelled Rifle, which in Shooting Burst; Suicide.**

Blackening of an area of the skin the size of the palm of the hand in the temporal region. In the middle of the discoloration there is an irregular opening, 2.5 cm. in length and upward of 1 cm. in width, with blackened edges. The hair in the vicinity is singed. Directly in front of this opening there is a ring with double contour, respectively 1.5 cm. and 1.3 cm. in diameter. This is evidently an impression of the orifice of the second barrel of the gun.

In addition there is a portion of the skin of the right thoracic wall. It reveals a curved wound, 2 cm. in length, situate between the anterior extremities of the second and third ribs. In the subcutaneous connective tissue of the wound there was found a section of the burst barrel of the gun, 2.5 cm. in length and upward of 1 cm. in width. One could distinguish the touch-hole and portions of the chamber of this barrel.

Fig. 121.

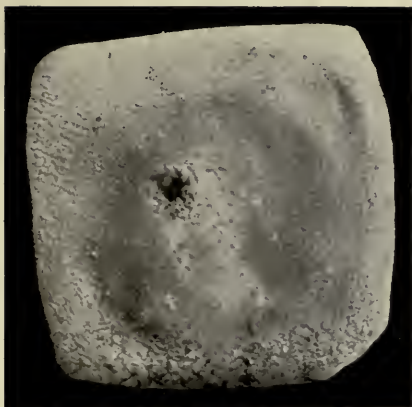



Fig. 122.







person may be able to perform various activities. He may particularly, as in the present case, occasion several additional gunshot-wounds even of the heart itself. This happens especially in cases of gunshot-wounds produced with a revolver, as the shots follow in rapid succession, and because the direct destructive force of the explosion is but slight and the projectiles produce relatively small openings, particularly the smallest varieties of revolvers, such as was used in the present case.

---

#### **Fig. 124.—Revolver-shot in the Mouth.**

Irregular angular opening, the size of a bean in the left posterior part of the hard palate. It has blackened base and ragged edges, in the vicinity of which grains of powder are scattered.

---

#### **Fig. 125.—Suicide by a Gunshot-wound in the Mouth.**

Externally nothing was to be noted but hemorrhage from the mouth and nose; internally, however, in the forward part of the oral cavity extensive blackening due to powder.

On the dorsum of the tongue to the left, behind the apex, there is an irregular, bean-sized, slit-like, markedly blackened opening. From this there courses posteriorly through the left half of the tongue a canal having the breadth of a small finger. The wound of exit from the tongue is at its base, but the wound itself continues posteriorly, destroying the left half of the epiglottis, the fold of mucous membrane above the left greater cornu of the larynx; thence through the posterior pharyngeal wall to the disintegrated transverse processes of the uppermost cervical vertebræ. Here, in an extensive suffusion of blood, there was found a conoidal bullet, 9 mm. in width, somewhat flattened at the apex. The large vessels of the anterior part of the neck were uninjured, but the left vertebral artery at about the situation of the destruction of the lateral mass of the atlas was irregularly lacerated.

The skull was uninjured. There was some extravasation of blood between the inner meninges, especially to the right below in the parietal region, and beneath these extravasations small contusions of the brain-cortex. The medulla and the cord were uninjured. There was a considerable quantity of aspirated blood in both lungs.

Death was therefore in part due to the contusion of the brain and its consequences, in part to suffocation the result of the aspiration of blood coming from the lacerated vertebral artery.

Fig. 124.

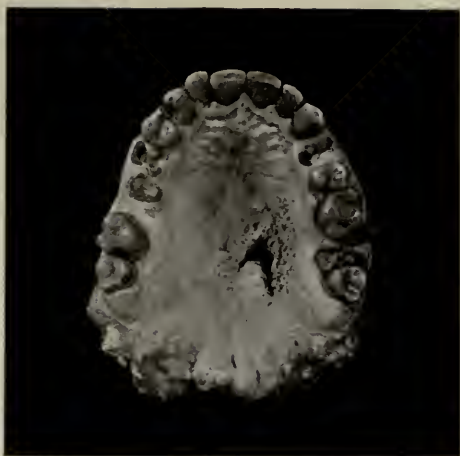

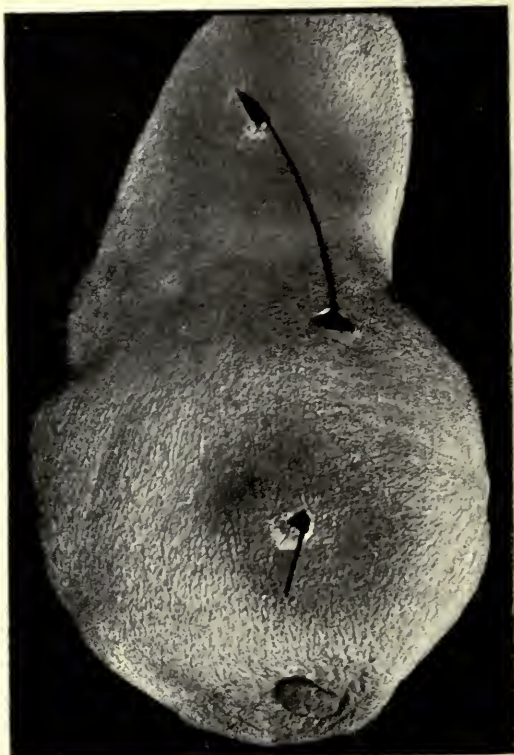
Fig. 125.

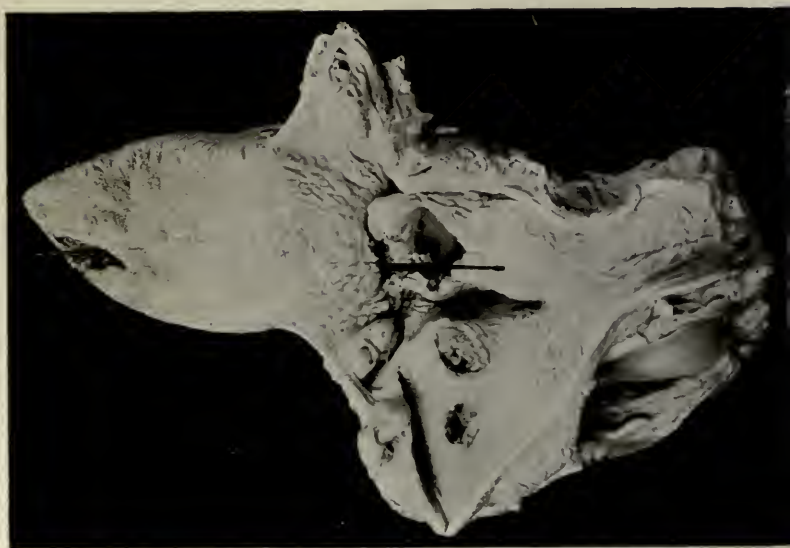





Fig. 126.



## FIGURE 126.

### Shot through the Dependent Mamma with Three External Openings.

During a fight in an inn, as it became necessary to forcibly eject one of the most boisterous of the combatants—having a loaded revolver of 7 mm. caliber—the latter is said to have been accidentally discharged. A female pedler sitting at a table one meter distant was struck with the bullet and killed. The physician first summoned found the woman already dead, and declared that the two upper wounds had been produced by the bullet, but that the lowermost on account of its slit-like form might have been caused by a stab. This opinion appeared not improbable, as the fight took place in the neighborhood of the woman and had become very furious, and as knives were said to have been drawn.

The necropsy, however, demonstrated that the third wound was also a gunshot-wound, and that all three wounds were produced by a single shot. The bullet had penetrated the dependent mamma, from above downward, and then entered the chest, where it opened up the apex of the left ventricle of the heart. There was therefore produced in the skin by *one* shot two wounds of entrance and one of exit. The first wound (of entrance) is irregularly circular and shows an area of contusion corresponding with the dimensions of the bullet; the second (a wound of exit), situate at the lower fold of the mammary gland, is slit-like, but without a ring of contusion; the third and lowermost opening has also a slit-like form, but shows at least in its upper part an abrasion of the epidermis, and thus permits of its recognition as a wound of entrance. (The figure should be inverted.)

## FIGURE 127.

### **Suicide by a Shot with a Hunting-rifle and "Spreading Cartridge" (Stauchpatrone).**

The case was that of an officer's valet who shot himself with his master's hunting-rifle. He had probably shot into his mouth or under his chin, pressing the trigger with his foot, as his boot had been removed from one foot.

The destruction is so excessive that there remain but fragments of bone and unrecognizable soft parts. Included among the parts destroyed are the lower and upper maxillæ, the entire base of the skull, the organs of the upper part of the neck, and the upper cervical vertebræ.

As the cartridge employed contained 6.5 grams of powder, the extensive destruction of tissue is accounted for by the direct force of the explosion, the more so as experiments with large firearms have shown that similar destructions may be produced by shots into the mouth of powder alone. In case of such injuries, therefore, it is unnecessary to immediately think of some special form of projectile, such, for instance, as an explosive-shot or a hydraulic-shot (wasserschuss). In the present case, however, there was another factor capable of increasing the effect of the shot; that is, the peculiar conformation of the cartridge. The latter was provided with a "spreading mechanism" (stauchvorrichtung); that is, a copper pin was let into the conical point of the soft leaden projectile, so that when a bone or other hard object is struck it drives the same asunder.

Fig. 127.







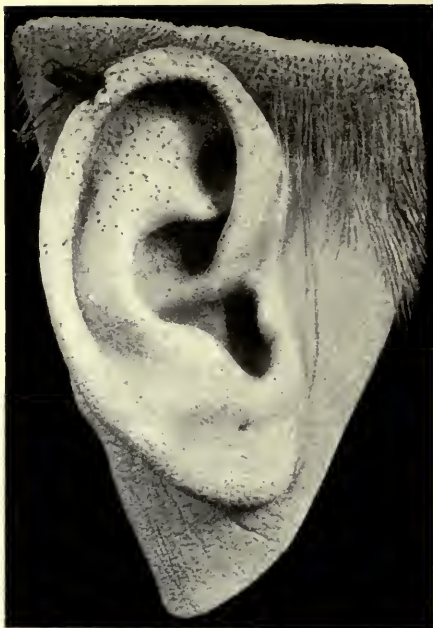
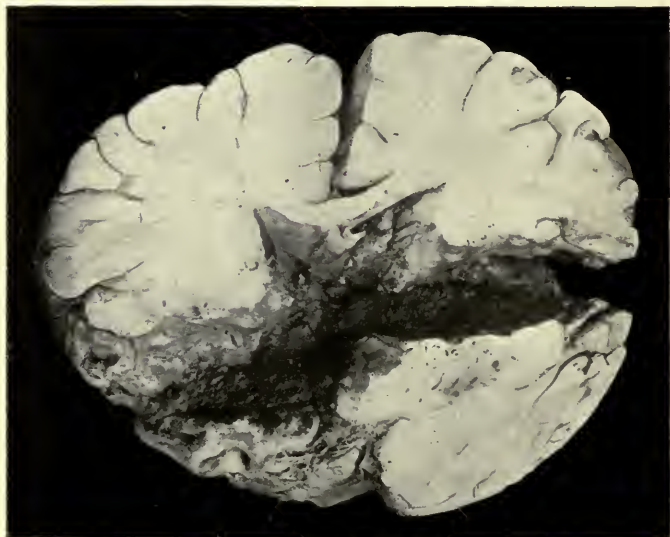


Fig. 129



## FIGURES 128, 129, 130, 131.

### **Fig. 128.—Grazing Gunshot-wound of the Right External Ear, with Scattered Grains of Powder in its Vicinity.**

This case is one of so-called double murder, such as occurs annually in large cities, and not infrequently several times during the year.

In a hotel, a young man, having shot his mistress, shot himself and jumped from a window. He died immediately as the result of rupture of the right lung and various fractures of the ribs.

On his body there was found above the right zygomatic process a blackened opening the size of a pea. This led directly inward to a short canal, destroying the roof of the right orbit. A misshapen conoidal bullet was found wedged in the right side of the crista galli. The dura mater and the inner meninges above the bullet were lacerated, suffused with blood, and contained scattered grains of powder. There was a contusion of the brain the size of a dollar.

This case itself is of interest, as it demonstrates that even after a gunshot-wound of the head, whereby the brain itself may be injured, the ability of the individual to act may persist—that is, the person injured may impart a second shot or cause another injury, or, as in the present case, end his life by jumping from a height.

The girl died while being transported to a hospital. There were found a gunshot-wound of the head and another of the chest.

The first commenced as a semicircular, furrowed splitting of the upper edge of the helix of the right external ear. It is 0.5 cm. in width, and shows black punctiform spots. In the vicinity of the wound distributed over an area about the size of a dollar in the upper half of the ear there are various blackish points. These decrease in number toward the periphery of this area, but are found also in the scalp behind the upper margin of the ear. There, one notices also a blackened opening the size of a pea, which leads into a canal which, entering the cranial cavity above the base of the petrous portion of the temporal bone, penetrates both ventricles of the brain and ends in the left temporal region, without injury to the dura. Here, imbedded in a blood-clot between the inner meninges, a misshapen conoidal bullet, of 7 mm. caliber, was found.

The wound of the chest, which was the size of a pea, was situated at the inner part of the right mamma. The clothing over it was closed, perforated, and blackened. Neither the wound in the skin nor the hands were blackened. The wound—directed from before backward and from right to left—penetrated the anterior wall of the chest, the anterior mediastinum, and the right auricle of the heart—all of which parts were markedly suffused with blood—and ended in the left side of the vertebral column. Lodged in this latter situation a misshapen bul-

let of 7 mm. caliber was found. There were no spermatozoa in the vaginal secretion.

That the girl was shot by the man there can be no doubt, but whether or not this occurred with her consent, in the absence of any positive information, cannot be determined. The suspicion, however, is aroused that the shooting may have occurred without the previous knowledge or consent of the deceased because of the fact that the shot was directed toward the right side of her chest and penetrated her clothing, and because of the fact that in shooting through the right temporal region the mouth of the weapon was not placed in direct apposition with the skin, but was held at a distance of about 5 cm. from the body. This latter fact was inferred from the distribution of the powder-grains and confirmed by experiments with the revolver employed.

---

**Fig. 129.—Gunshot-wound Transversely through the Brain ;  
Suicide.**

Wound of entrance in the right temporal region ; the track of the shot transversely through both striate bodies ; both lateral ventricles filled with disintegrated brain-substance and blood-clots ; discoloration produced by the powder diminishing in grade toward the left.

---

**Fig. 130.—Simple Punctured Gunshot-wound of the Frontal  
Bone Produced with an Ordinary Revolver.**

Circular wound of entrance 12 mm. in diameter, with sharp edges bevelled internally. No wound of exit. Suicide.

---

**Fig. 131.—Close-range Shot with a Mannlicher Rifle ;  
Suicide.**

Circular wound of entrance at the glabella. From this there proceed in a star-like fashion three fractures. Two course outward into the orbits, where they end with destruction of the vault of the skull. The third extends posteriorly from the wound of entrance through the middle of the left coronary suture to the left parietal eminence. Here it divides into two. The external descends into the left posterior fossa of the skull, whereas the internal courses almost transversely and in an arched manner through the posterior third of the interparietal suture to the separated squamous portion of the right temporal bone. That part of the occipital bone situate between these two fractures is very much splintered.

Fig. 130.

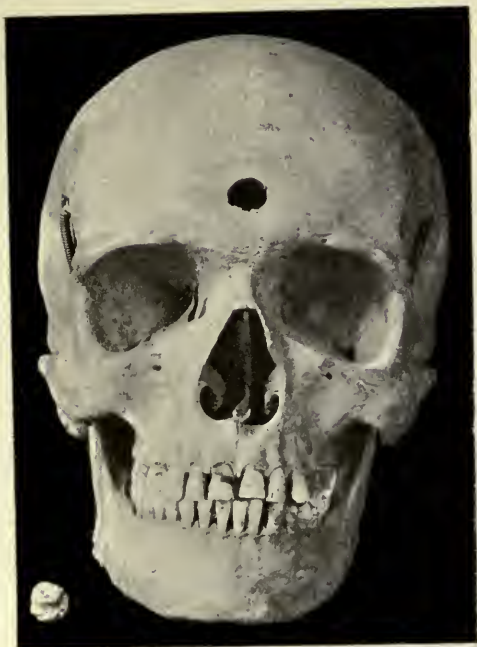

Fig. 131.

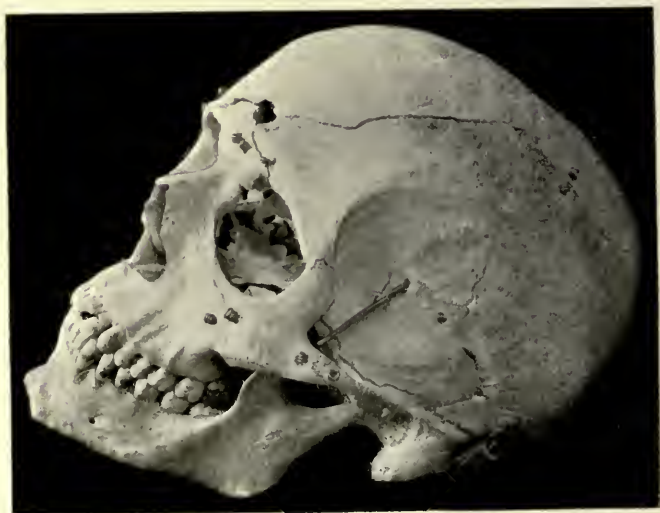





Fig. 132.

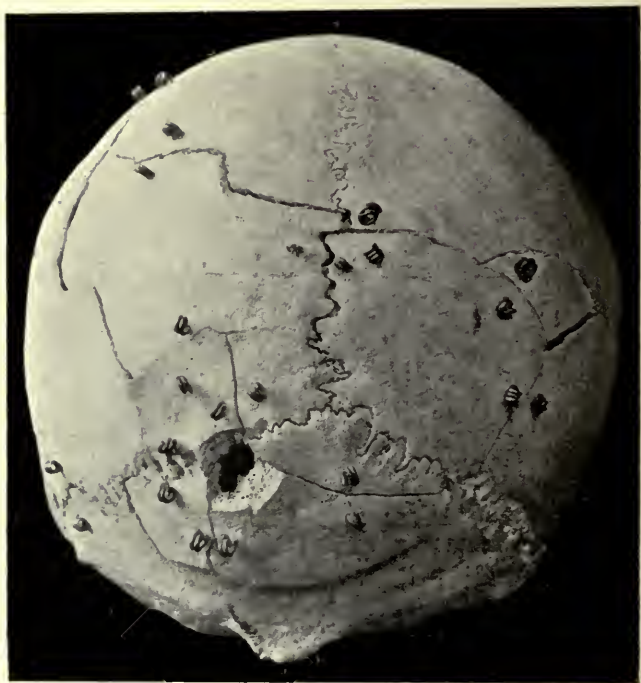
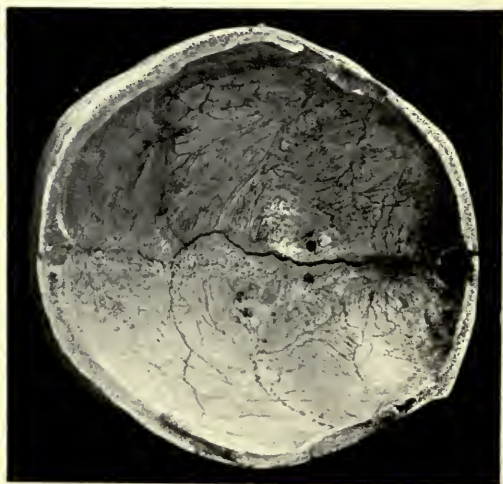


Fig. 133.



### FIGURES 132, 133.

#### **Fig. 132.—Wound of Exit of the Gunshot-injury Produced with a Mannlicher Rifle, Illustrated in Fig. 131.**

The wound of exit is a roundish opening in the occipital region, 2 cm. in diameter. Its edges externally are bevelled, internally sharp. The bones about the opening originally appeared irregularly shattered, but after replacement of the fragments are found to make up an irregular plate of bone occupying almost the entire occipital region, in the lower part of which the wound of exit is situate. About this as a center there is a smaller roundish plate of bone, which forms externally a slightly prominent cone, and which reveals four fractures radiating from the perforation.

---

**FIG. 133.—**Suicide by a shot with a revolver of moderate caliber in the forehead. Inner side of the wound of entrance with bevelled edges. From the posterior periphery of the perforation there begins a fracture which courses along the obliterated interparietal suture to its middle, where, forming a very obtuse angle, it divides into two long limbs.

## FIGURES 134, 135.

**Fig. 134.—Wound of Exit at the Right Side of the Occiput of a Gunshot-wound through the Left Frontal Region, Produced with an Army Revolver of 9 mm. Caliber; Suicide.**

A plate of bone half the size of the palm of the hand has been shot out. It is much shattered, and shows in the center an irregular perforation, rather larger than a bean, through which the bullet made its way.

The opening, corresponding in size with the fractured plate of bone, is irregularly round and has a notch at its lower part. Its edges to the inner side of the skull are sharp, to the outer side bevelled. Thus, despite the marked destruction of the skull, one can still distinctly recognize indications that the force came from within the cranial cavity; that the opening is therefore a wound of exit.

---

**Fig. 135.—Suicide by a Shot with an Army Revolver (12 mm.) into the Right Temporal Region.**

In the anterior lower part of the right temporal region there is the inferior half of the circular wound of entrance, 1.5 cm. in diameter. The upper half, including a portion of the parietal bone the size of a hand, is absent, and was not near the body. As a consequence of the force of the explosion it had probably been thrown a considerable distance and was not to be found. The skull shows, in addition, various long fractures. Some of these begin at the wound of entrance, some at either of the narrow ends of the large oval defect of bone, the long axis of which latter is in the direction of the long axis of the skull. Some of these fractures extend to the base of the skull. A portion of the brain was absent, the remainder much disintegrated, and in it there was found a much deformed conoidal bullet, 12 mm. in diameter.

The excessive destruction is accounted for by the great force of the exploding gas, and presupposes a large charge of powder, and inferentially a large weapon. That the fracturing of the skull ensued from within is evident from the edges of the large opening, which internally are sharp, externally markedly bevelled throughout.

Fig. 134.

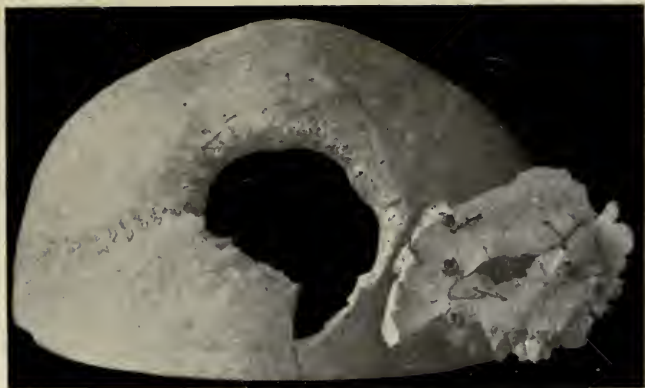


Fig. 135.

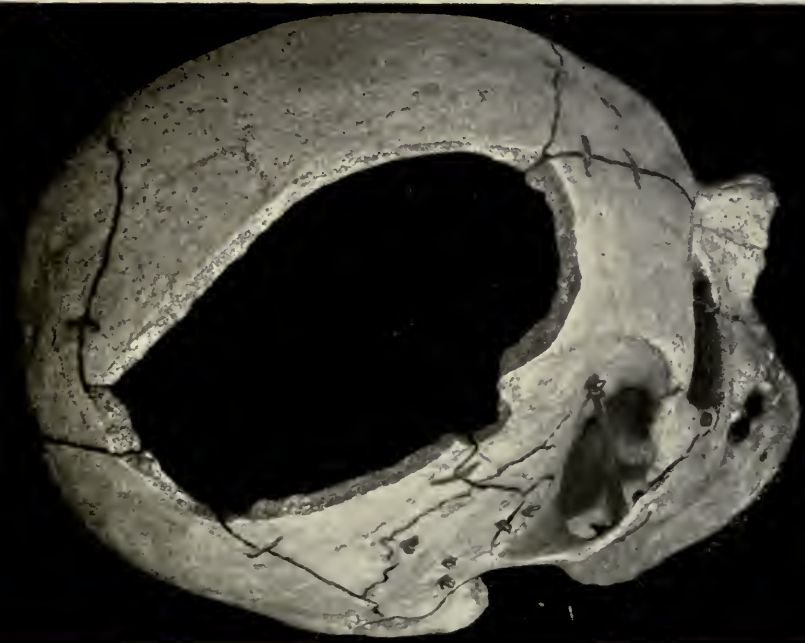





Fig. 136.

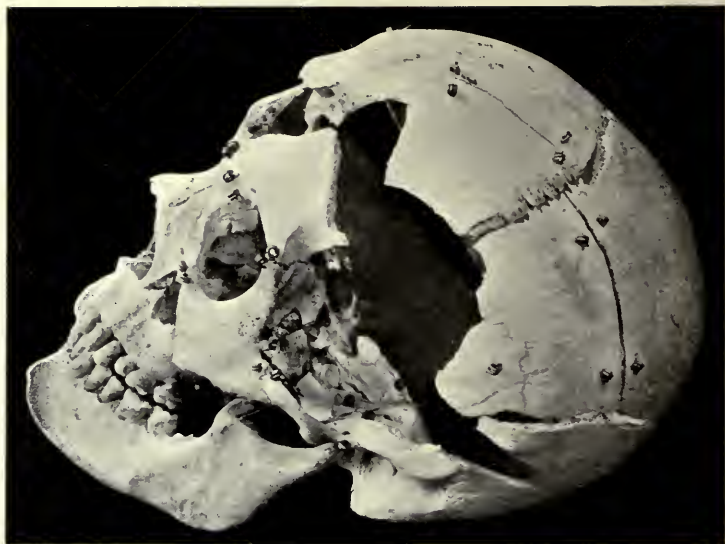

Fig. 137.



FIGURES 136, 137.

**Fig. 136.—Suicide by a Shot in the Left Temporal Region with a Moderately Large Revolver Loaded with Broken Lead.**

Skull of a man aged 21 years. Excessive destruction of the entire skull; perforations and fractures of all the bones, partial upward displacement of the vault of the cranium, and diastasis of the right coronary suture.

---

**Fig. 137.—Murder by Anarchists.**

Shot from the immediate vicinity directed at one lying prostrate on the floor. Wound of entrance about the inner third of the left coronary suture. From the perforation there proceed two fractures. Of these, the anterior is directed through the frontal bone to the left frontal protuberance; the second courses posteriorly to the interparietal suture, through this to the inner posterior part of the right parietal bone, thence below to the posterior fossa of the skull. The projectile penetrated perpendicularly through the anterior part of the left lateral ventricle and was found deformed at the base of the skull.

## FIGURES 138, 139.

### Suicides by Gunshots. Unusual Situation of the Wounds of Entrance.

FIG. 138.—The wound of entrance—represented by a circular opening—is situate in the parietal bone, in the angle formed by the interparietal and the right parietofrontal sutures. The frontal bone is fractured through its center. The fracture begins in front of the wound of entrance at the middle of the parietofrontal suture and gradually widens toward the base of the skull, ending in the sella turcica. The fracture was evidently due to the sudden vertical compression of the skull exerted by the shot.

•

---

FIG. 139.—Skull of a man, aged 30 years, who one evening, while sitting in a crowded Prater-café, shot himself. After the report he was seen to fall from the bench, holding a double-barrelled gun of 9 mm. caliber in his hand. On his person other cartridges and a card were found. In the latter of these he announced poverty as the cause of the suicide. The wound of entrance had a most remarkable situation, being found in the occipital region, directly above the apex of the tabular portion of the occipital bone. Externally it was blackened with powder.

The perforation of the bone is circular, 12 mm. in diameter. Externally its edges are sharp, internally bevelled. From the right periphery of the opening there begins a diastasis of the parieto-occipital suture which continues into a fracture of the bones of the skull, with coarsely serrated edges. The latter encircles the skull in about the direction in which one is accustomed to open the skull postmortem, and ends at the left side of the skull in a diastasis of the suture between the occipital bone and the petrous portion of the temporal bone. The vault of the skull can thus be lifted up as one would a flap. In addition, there are isolated fractures of the roofs of both orbital cavities.

The markedly misshapen conoidal shot was found at the much shattered apex of the petrous portion of the temporal bone.

The case is noteworthy because of the very unusual situation of the wound of entrance. Had the suicide not occurred in full view of the people and under otherwise very manifest circumstances, the unusual situation of the wound might readily have awakened the suspicion that the deceased had been shot by others.

Fig. 138.

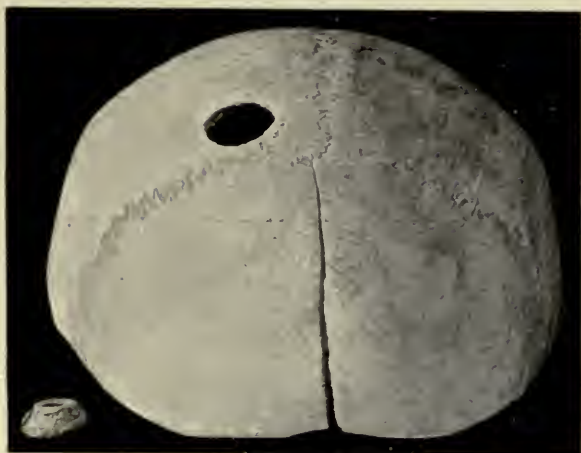

Fig. 139.

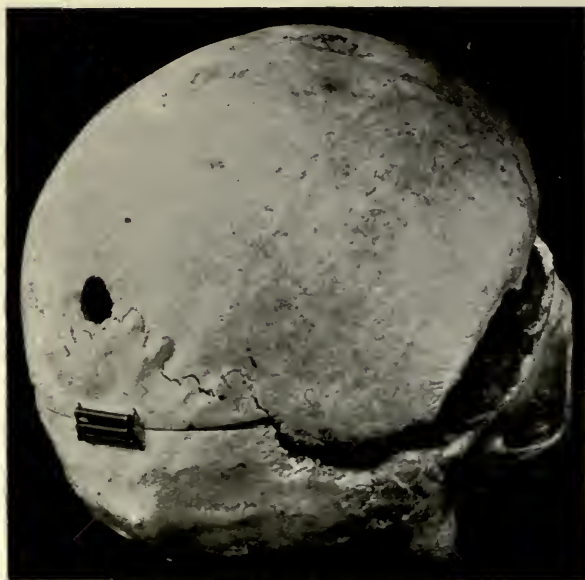
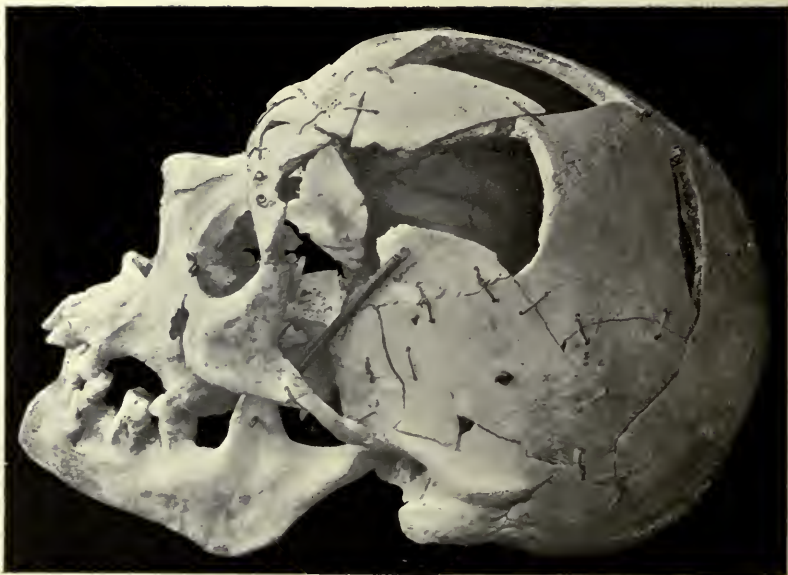




Fig. 140.



### FIGURE 140.

Small shot from a hunting-rifle, at a distance of three paces, into the left frontal region. Elderly man shot while stealing wood. Marked destruction of the skull, especially of the left frontal and temporal regions, with absence of certain portions of the bone.

## PLATE 20.

### Encircling Gunshot-wound.

An interesting example of deflection of the projectile from the direction of the shot, or of the so-called *ricochet-shot*, within the body, is the so-called *encircling-shot*. This is produced when a shot, striking an arched bone obliquely, travels around it. Such gunshot-wounds have been observed not only on the convexity of arched bones—as, for instance, those of the vault of the skull or the ribs—but also on their concavity.

The case illustrated in Plate 20 belongs to the latter category.

The case was that of a young man who had killed himself with a shot from a revolver of 7 mm. caliber. The projectile perforated the skin of the right temporal region directly in front of the line of the growth of the hair, making a pea-sized blackened opening. It then coursed obliquely upward and backward through the temporal muscle and the great wing of the sphenoid bone into the outer part of the right Sylvian fissure; thence to the concavity of the right frontal vault. From this point it became directed anteroposteriorly around the entire convexity of the brain, between the dura firmly attached to the bone and the upper surface of the brain-substance, as far as the anterior part of the inferior occipital convolution, where it lodged. During its course it gave rise to a fissure-like laceration of the cerebral convolutions and the superjacent inner meninges.

Such deflections of bullets render quite difficult the following of the channel of a gunshot-wound and the discovery of the bullet; they merit, therefore, attention. In cases of this sort it is better at first to remove the brain *in toto*, to carefully wash away the intermeningeal extravasation, and then to proceed to the further examination of the brain.

Angular deflections of the bullet are much more commonly met with than such arched ones, and almost always at the end of the track of the gunshot-wound. The bullet, striking the skull obliquely, is deflected at either an acute or obtuse angle into the brain again, forming a new bullet-track which is usually short.

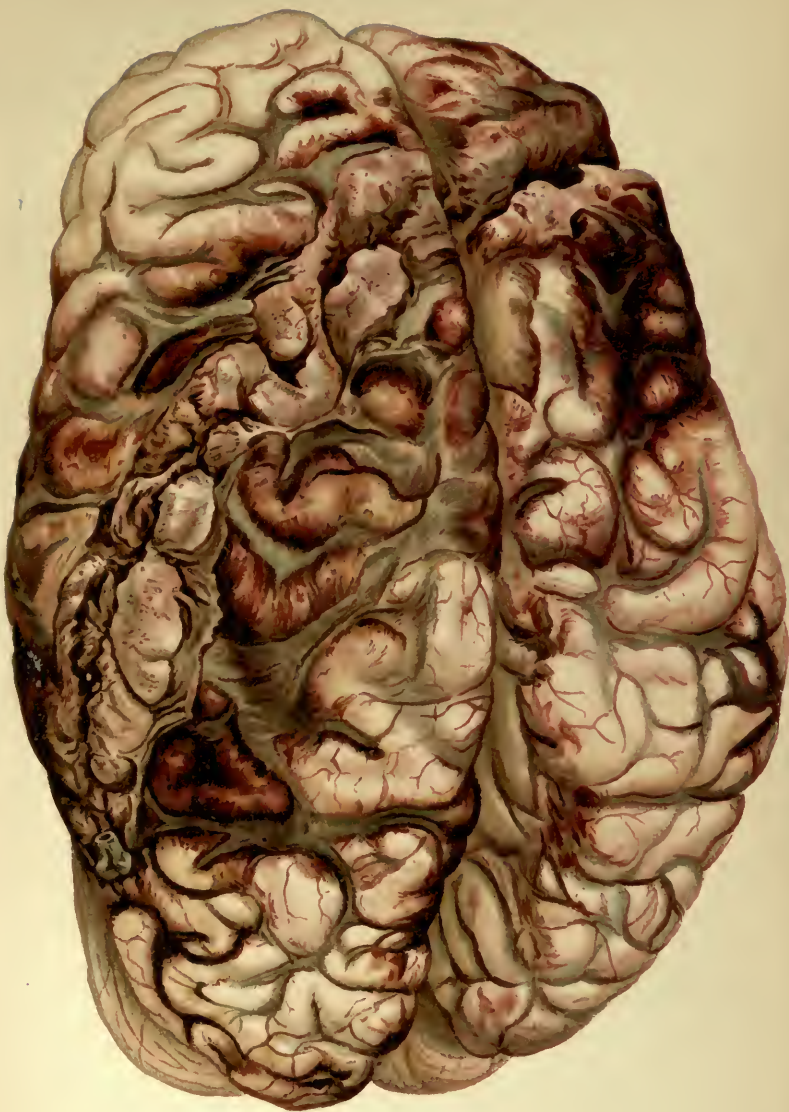





Fig. 141 — 155.

141



145



151



142



146



152



147



153



143



148



154



144



149



155

150



## FIGURES 141-155.

### Deformation of Projectiles.

Projectiles commonly become deformed, especially if they come into contact with bone. Such deformation renders difficult the recognition of the variety of the projectile (whether ordinary or conoidal or broken lead), and the answering of the question as to whether it was fired from a particular firearm; it is further of influence upon the character of the wound, as the greater the deformation of the projectile the wider and the more irregular the wound, whether bone or soft parts be affected.

The extent of the deformation depends especially upon the softness of the material of which the projectile is made. It is a well-known fact that, other things being equal, shots made of soft lead are subject to the most marked changes. In addition, the deformation is the more marked the greater the force with which the shot is propelled from the gun and the more resistant the bone; for instance, long bones are more resistant than flat bones. The character of the deformation is particularly dependent upon the direction in which the projectile meets the bone; upon whether or not the point struck is a flat or sloping surface, or an edge or a prominence. If the projectile strike the surface of the bone perpendicularly, it becomes flattened, and may remain as a thin disk attached to the bone. If, however, it enters or penetrates the bone, it becomes subject to a fungiform flattening, the edges being at the same time everted. The principal change affects the forward end of the projectile—of conoidal bullets, the apex. The posterior end is usually preserved, and, as a rule, even in case of absolute flattening of the projectile, permits of the recognition of its former conoidal character. Figs. 142, 145, 153, 154, and 162 show such shots. If the shot strike obliquely, not only is its anterior part more or less obliquely deformed, but also its posterior part. Despite this, however, the latter is usually discernible, FIG. 141; military shot (long lead), FIG. 143; Italian or French conoidal shot, from the battle of Solferino, FIG. 144; Russian, from the Turko-Russian war, FIGS. 148 and 160.

If the bullet strike the edge of a bone or solid rough surfaces, it may be irregularly deformed *in toto*, or it may be in part or completely splintered, and portions of it, being broken off, may give rise to additional gunshot-tracks—FIGS. 151, 152, 155.

### FIGURES 156-169.

As is well known, in an endeavor to prevent the disastrous consequences of the deformation of the bullet in military operations, so-called covered shots were introduced. These are long, narrow bullets of lead, covered with a mantel of hard metal—nickel or steel. FIG. 163 shows such a shot completely intact, although it had penetrated the skull of a man who committed suicide. That the protection afforded by the mantel is not absolute is evident from FIGS. 164, 165, 166, 167, and 169. In these we notice various fragmentations of the mantels and deformations of the enclosed lead of bullets which struck distant stones and walls. FIG. 168 reveals a similar deformation of a bullet which remained in the greater trochanter of a person accidentally shot.

Fig. 156 - 169.

156



157



158



159



160



161



162



163



164



165



166



167



168

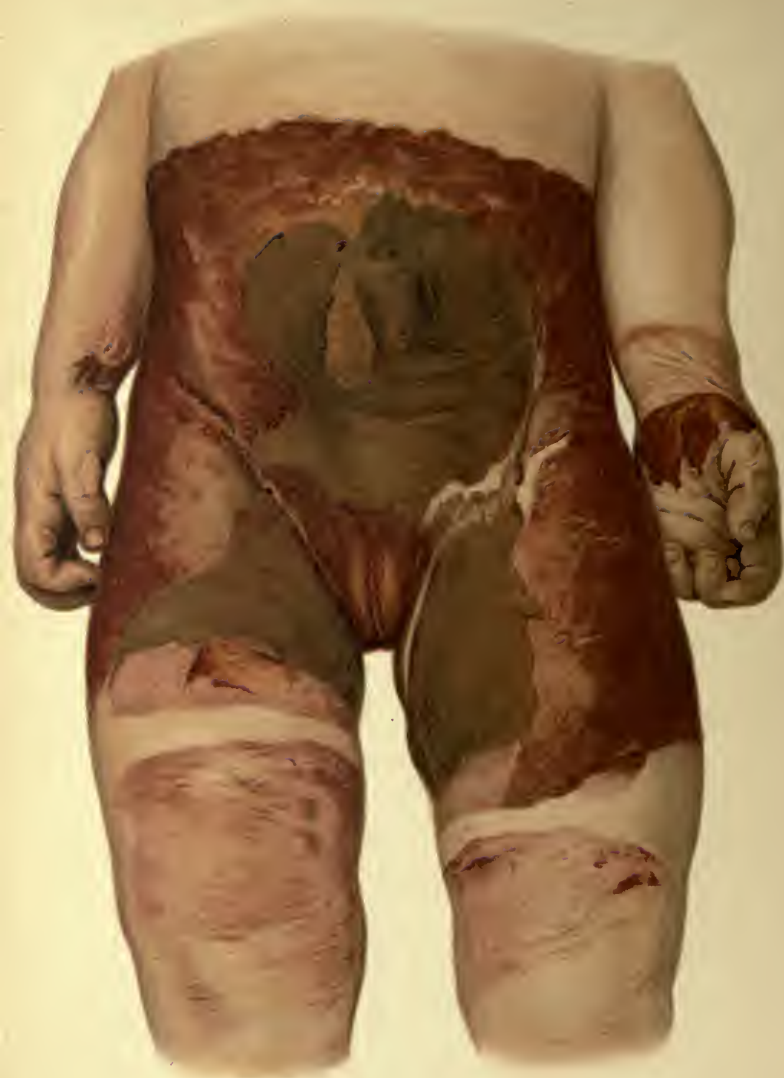

169









## PLATE 21.

### Burns Produced by Flames.

The case is one of those relatively common in large cities during the winter. A child, aged 2 years, being left without attendants in a small apartment, approached too near the stove. Its clothes caught fire and the child was extensively burned. It was still alive when found, but soon became unconscious, and died at the end of four hours.

But even without this history, there could be no doubt that the burns were produced by flames. There were found burns of minor grades of the upper part of the body, especially of the face; the hair of the frontal and temporal regions, the eyebrows, and the eyelashes were singed; in addition, the skin and the respiratory orifices were blackened, many of the burnt areas were as though roasted and of a brownish-black color, and finally the distribution of the burns was extremely characteristic—resembling swimming-breeches. This distribution of the burns occurs especially in the case of women and children when the clothing of the lower portion of the body catches fire and is quickly consumed. This latter is favored by the air which intervenes between the clothing and the body and by the light fabrics of which the clothing is made. This sort of burn is not so likely to be met with in the case of men because of the closer apposition of their clothing to the body, and because of the more substantial materials of which it is usually made. The latter may even afford a certain protection against burning, of which in the present case one may see an indication in the limitation of the burn at the waistband, and at the areas above the knees corresponding to the former situations of the garters.

One may distinguish four grades of burns: 1. Erythemas, narrow margins of redness at the periphery of areas of the more intensely burnt skin. 2. The separation of the epidermis, with the formation of vesicles filled with pale serum at both wrists, as a vesicle the size of a nut on the back of the right thumb, and as a ragged, almost glove-like detachment of the upper layers of the skin of the left hand. 3. Extensive denudation of the corium with coagulation-necrosis of the upper layers of the cutis. It is this which forms the greatest part of the burn, and it is here that the reactive hyperemia and edema are most marked, and it is this tissue which, when the body is exposed to the air, becomes dried, forming hard, leather-like, brownish-red coverings. 4. Extensive brownish areas as though roasted and rendered black by smoke; to these the epidermis is closely adherent, and with the cutis appears coagulated. Such areas are those between the umbilicus and the symphysis pubis and on the inner surface of both thighs; therefore those areas which the flame must have affected early and intensely. In this case recovery would have been possible only after complete desquamation of the roasted-like cutis.

There are further to be noticed several ruptures of the cutis along the inguinal folds and the left genito-crural fold. Their white color and the non-reactiveness indicate that they were produced postmortem by extension of the thighs and consequent rupturing of the parched skin of those regions.

---

## FIGURE 170.

### Murder or Suicide by Burning.

The case was published in the *Intern. fotogr. Monatsschrift für Medizin und Naturwissenschaften* (III.), Jahrgang 1896, by Dr. Franz Neugebauer, of Warschau, who has graciously permitted me to republish it.

The body of a man, who remained unidentified, was found in the knee-elbow position excessively burnt, beside some railroad-tracks. The body had about it an odor of petroleum, and near by was an empty petroleum-can. No injuries to the body were discovered. On the other hand, however, there was found aspirated soot in the air-passages, and from this latter it was concluded that the burning had occurred *intra vitam*. All vestiges of hair had disappeared; the clothing, with the exception of one shoe, had been completely consumed. The surface of the body was blackened and appeared as though roasted; here and there the skin was burst.

The burning was evidently the result of applying a light to the clothes previously saturated with petroleum. Whether the case was one of suicide or murder could not be positively determined. As similar cases of suicide have occurred (especially in Vienna), this possibility cannot be excluded. Dr. Neugebauer considers the case more likely one of murder, and believes that the deceased might have been intoxicated at the time of the deed; thus the absence of any injuries or indications of strangulation is accounted for.

According to Dr. Neugebauer, the peculiar position of the body developed postmortem, and was due to the contractions of the burnt skin and the musculature drawing up the extended body. Similar abnormal positions have often been observed in cases of deaths from burns, as, for instance, in the burning of the Ring Theater and of the Opéra Comique; they were also known to Devergie, who designated them "fencing-postures."

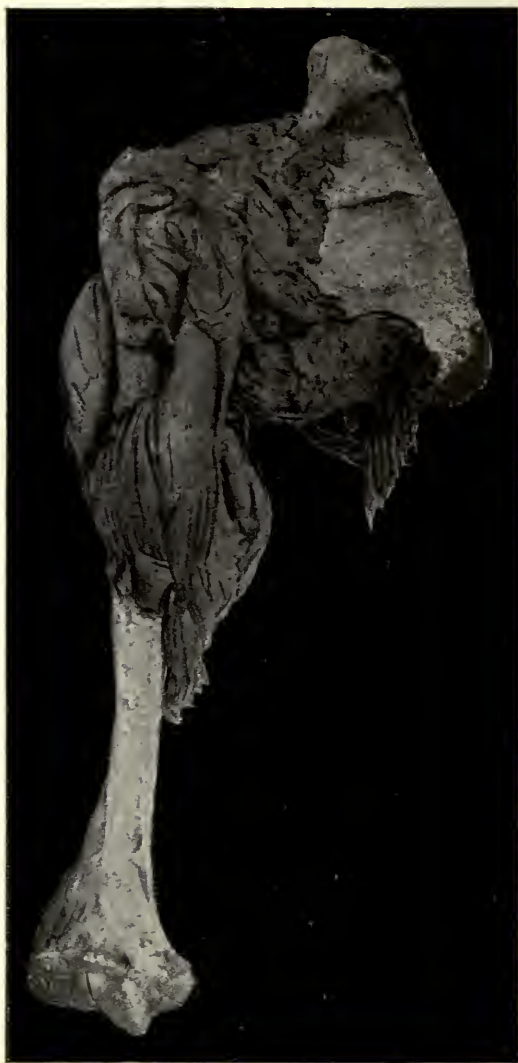Fig. 170.







Fig. 171.



## FIGURE 171.

### **Right Upper Arm and Scapula of a Charred Body, with the Muscles Attached to Them.**

The charred remains of an unidentified man, aged about 50 years, which were extracted from the ruins of a hay-barn destroyed by fire. The man had probably hidden himself in the hay and started the conflagration by smoking.

The illustration shows the slightly burnt right humerus and the therewith articulated scapula, and the superficially charred but otherwise roasted-like musculature of the upper arm and shoulder; the skin is missing. The muscles are loosened from the periphery of the scapula and from the distal end of the humerus, and retracted toward the shoulder-joint, where they form a thick swelling. At the peripheral ends of the retracted muscles the tendons—separated from the bones, especially the biceps tendon—are discernible. The latter has been converted into a viscous substance, its point of insertion separated from the bone and retracted, leaving the lower half of the humerus bare.

This retraction and separation of the musculature is of common occurrence in semi-charred bodies. It depends, on the one hand, upon the contraction of the burnt muscles, and, on the other, upon the conversion of the tendons into a viscous substance and their consecutive loosening from the bone. This possesses a forensic importance in so far as such contractions may give rise to mistakes in the determination of the age or the condition of the nutrition of the deceased, and as possibly—though erroneously—from such contractions the inference may be drawn that the individual was burnt while alive.

## FIGURE 172.

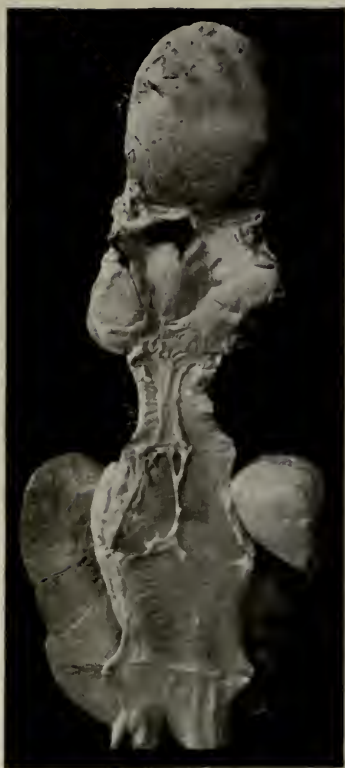### **Healed Scald-wound of the Esophagus.**

The preparation illustrated in the figure was found at the necropsy of an emaciated foundling, aged 8 weeks, which died of bilateral lobular pneumonia.

The esophagus in its lower half is dilated to triple its normal size. The intact mucous membrane of the pharynx is limited transversely at the entrance of the esophagus by pale, rounded, overhanging margins. At the middle of the esophagus the mucous membrane continues into a white cicatrix of its anterior wall. It is made up of dense fibers, and therefore resembles striated tissue. It extends to the lower third of the esophagus, in which situation a portion of it is undermined as a bridge. The gastric mucous membrane was unchanged.

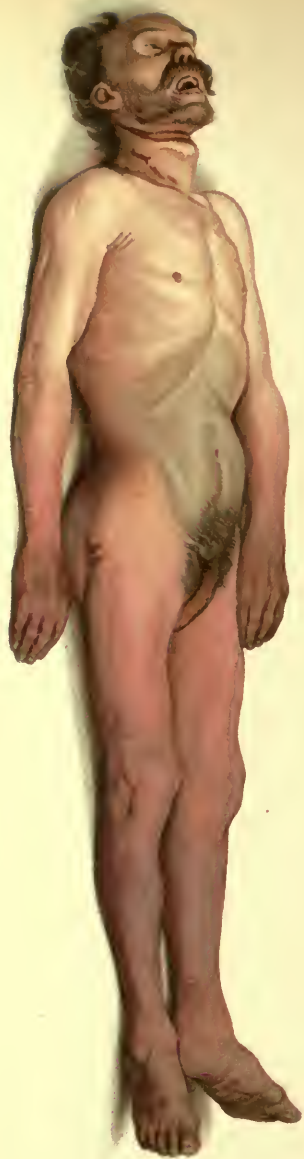The lesion was originally considered the consequence of the caustic action of sodium hydrate or some similar substance. But inquiries revealed no confirmatory evidence of this supposition. On the other hand, the fact was elicited that in the early days of its life the child may have been given tea entirely too hot; that, therefore, the lesion was the result of a scald. This assumption is confirmed by the striated appearance of the cicatrix, which I have heretofore observed after wounds due to burns, but never as the result of the action of caustics.

Fig. 172.









## PLATE 22.

### **Suicide by Hanging; Suspension of the Body for Several Days; Peculiar Distribution of the Hypostases.**

Body of an unknown man, aged about 60 years, found hanging to a tree in the Dornbach forest, October 30, 1896.

The normally brunette skin, through the imbibition of bloody serum, has assumed a dirty violet color. The skin of the face, of the neck, and of the upper part of the body as far as the waist is pale; below this region, increasing in intensity downward, it is of a dirty violet color—the discoloration reaching its highest grade in the feet. The discoloration is diffuse; only here and there can one distinguish fading, punctiform, reddish spots. These are made up of the minutest ecchymoses, and because of their small size are not depicted in the illustration. A similar discoloration is also discernible in the dependent arms. The skin of the upper arms is pale, but below it becomes more and more livid, so that the hands and fingers show a markedly dirty violet color.

This bilateral, symmetrically distributed discoloration of the skin is the result of the long-continued perpendicular position of the body. As a consequence of this the external hypostases (the so-called post-mortem lividity) have not developed (as usually) on the posterior surface of the body, but in the lower dependent portions thereof.

Such distribution of the postmortem lividity, when found in a body, by no means indicates that the deceased died as a result of hanging; it may also develop when a body is hung up. It merely indicates that the body was hanging for a long time. But from the degree of the development of this phenomenon, in connection with other postmortem findings, one may approximately conclude how long the body was suspended.

In the present case, despite the low temperature in the forest, the abdomen was already putrescent—green; the serosanguinolent imbibition of the hypostatically discolored parts, as well as of the rest of the skin, was well advanced; the eyeballs were much depressed and relaxed. It was in consequence concluded that the body must have been hanging about a week or at least several days.

There was no question as to the case being one of suicide by hanging. The groove produced by the rope, which was 1 cm. thick and old, is dried and leather-like. At the front of the neck it is directed transversely between the larynx and the hyoid bone; on both sides alike it ascends behind the mastoid processes of the temporal bones to the nape of the neck, where it terminates in the hair. Excepting this groove, no injury was found either internally or externally; in particular no indications of violence could be discovered.

To the right side of the neck in its lower part, however, there were found three brownish, dried, irregular, linear spots. They affect only the upper layers of the skin, are not associated with any deeper injuries, reveal no indications of reactive phenomena, and may therefore be looked upon as having probably developed postmortem.

There were no striking evidences of congestion or ecchymoses of the face. This is readily explicable because of the symmetric arrangement of the rope, which gave rise to a sudden, equable compression of the various vessels of the anterior part of the neck.

---

## FIGURES 173, 174.

### **Position of Noose in Cases of Persons Hanged.**

In FIG. 173 an instance of the typical position of the noose is represented. The rope encircles the anterior part of the neck between the larynx and the hyoid bone, and on both sides ascends below and behind the mastoid process to the nape of the neck, where at the margin of the growth of the hair it joins a little to the left of the median line. The head is inclined forward, and as a consequence the chin approaches the chest.

In FIG. 174 there is depicted that position of the noose which occurs next in frequency to the aforementioned typical position—that is, the noose is situate behind the ear—more commonly the left. The head is inclined forward and to the right; the groove made by the rope is more marked at the right side of the neck.

Fig. 173.

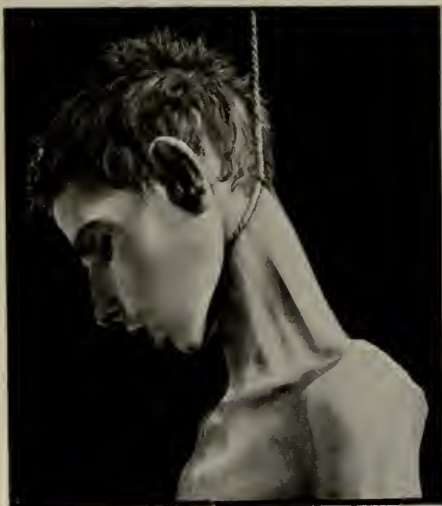

Fig. 174.

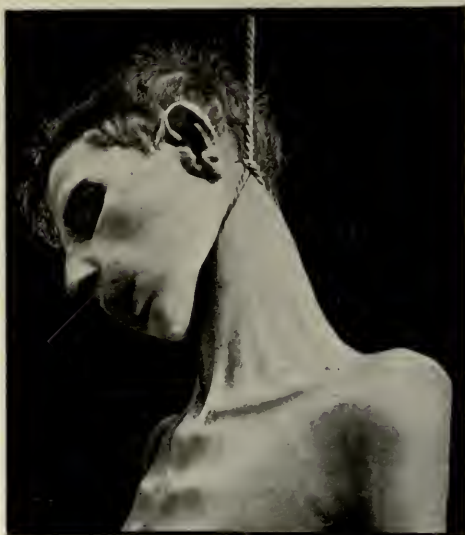


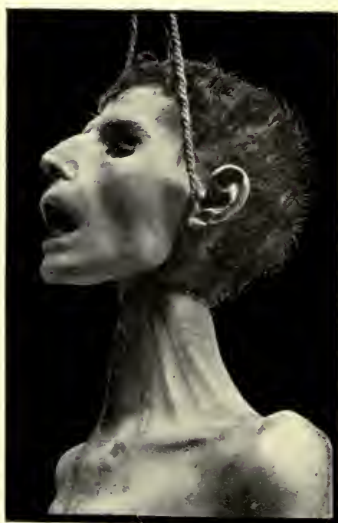


Fig. 175.



Fig. 176.



## FIGURES 175, 176.

### Position of Noose in Cases of Persons Hanged.

In FIG. 175 the knot is situate, and the end of the rope is directed upward, between the left ear and the left angle of the inferior maxilla. The head is inclined to the right, and the groove made by the rope is more marked at the right side of the neck.

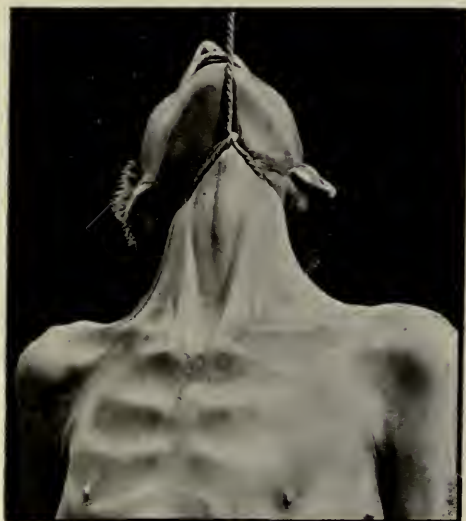In FIG. 176 we see a most abnormal, though repeatedly observed, course of the rope. The rope is first placed at the nape of the neck, its two ends brought horizontally forward and crossed, and on either side posterior to the angles of the inferior maxilla carried upward to the point of suspension. The neck is markedly elongated, and as a consequence of the horizontal course of the rope greatly and symmetrically constricted. Thus the folds of the skin of the neck of the much emaciated individual converge toward the constriction. The head is erect and held fast by the rope ascending behind the angles of the inferior maxilla.

## FIGURE 177.

### **Abnomal Position of Noose in a Hanging.**

The figure illustrates a most unusual case in which the noose is placed in a position directly opposite to the common or typical situation. The knot is found at the anterior part of the neck directly under the chin. The rope encircles the nape of the neck, in which situation the groove made by it is most marked. It ascends toward the front of the neck beneath the angles of the lower jaw and joins under the floor of the mouth, between the larynx and the chin. It then ascends perpendicularly over the chin to the point of suspension. The head is inclined excessively backward, the anterior part of the neck markedly stretched, and on both sides beneath the inferior maxilla greatly constricted. It is thus evident that both the respiratory passages and the larger vessels of the neck may be compressed until they are completely occluded by the rope in this position.

Fig. 177.



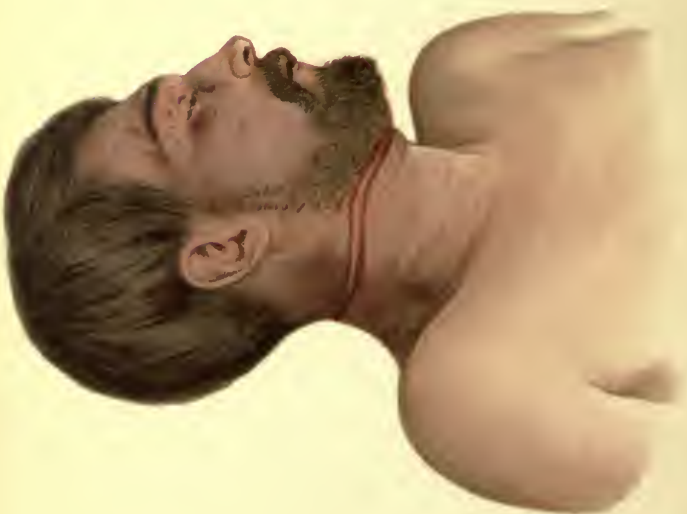



b



a



## PLATE 23.

### **Suicide by Hanging with a Double Rope. Asymmetric Position of the Noose.**

The case was that of a cabinetmaker, aged 36 years, who hanged himself, and whose body had been given to students for dissection.

The face is especially cyanotic, and shows numerous punctiform ecchymoses of the skin of the eyelids and surrounding parts, and also minute isolated ecchymoses in the skin of the rest of the face. Larger ecchymoses, nearly the size of a hempseed, are also present in the markedly injected conjunctivæ and in the mucous membrane of the lips.

The groove made by the rope is situate asymmetrically. Encircling the right side of the neck, both extremities of it ascend behind the angle of the left inferior maxilla, forming an incomplete angle, open below. As a consequence, the head is inclined somewhat to the right and the groove is more marked to the right—the extremities of it becoming less marked as they ascend.

The groove, as is particularly evident to the right, is a double one. It consists of two furrows with parallel edges joining to form one. Each furrow is as wide as an ordinary rope. They are separated from each other by a narrow band of skin, which also has parallel edges. The base of the furrows is pale and reveals indentations of the twists of the rope. The edges of the furrows, as also the intervening portion of the skin, are very red, and reveal macroscopically, as also on examination with a low-power lens, a marked and almost uniform injection of the cutaneous vessels, and in addition numerous minute ecchymoses.

These lesions, which are explained by the constriction of, and by the embarrassment of the circulation in, the affected portion of the skin, when as marked as in the present case, possess a diagnostic importance in so far as they indicate that the suspension occurred during life. The correctness of this latter assumption, in the present case, is further enhanced by the fact that there are present no signs which would warrant the supposition that a hypostatic hyperemia was present before the adjustment of the rope, nor the possible view that the marked cyanosis and ecchymoses of the face and neck occurred before the suspension as a result of death from another mode of suffocation.

The reason that in the present case such a marked cyanosis developed, whereas in persons hanged the face usually shows the ordinary death-pallor, is found in the asymmetric situation of the noose. As a result of this, in contradistinction to cases in which the rope is placed typically and in which *all* the vessels of the anterior part of the neck are compressed, in the present case only those of the right side of the neck were obstructed—a circumstance which naturally led to marked congestion.

## PLATE 24.

### **Suicide by Hanging with an Old Rope Wound Five Times about the Neck.**

On the forward part of the neck between the larynx and the hyoid bone five furrows are discernible. Of these the two uppermost are in part close together with an intervening reddened ridge, in part overlapping. The lowermost are separated from each other by a spindle-shaped prominent area of skin, which appears as though hemmed in by the two grooves. Its edges are markedly injected and pervaded by minute ecchymoses. Both sections of skin are divided by another furrow, which, proceeding from beneath the right half of the upper, courses obliquely to the left half of the lower, where it becomes lost. This diagonal groove is somewhat wider than the others, and reveals about the middle of its base a narrow reddened elevation. It is, therefore, likewise a double furrow.

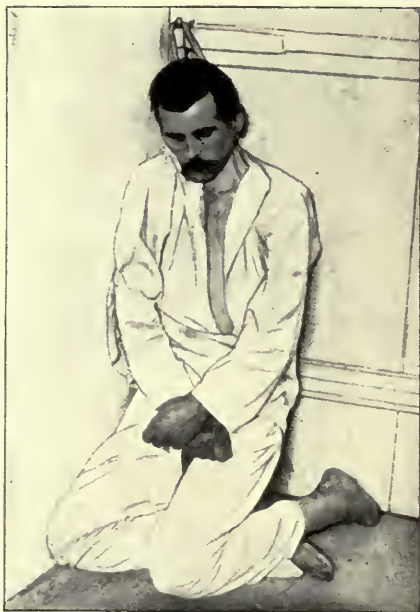
The face and neck of the body show no remarkable cyanosis; neither were ecchymoses to be seen either in the skin or in the visible mucous membranes. Under these circumstances one would be justified in concluding, from the marked injection and ecchymoses of the ridges or areas of skin between the various furrows produced by the rope, that the deceased was hanged or hanged himself while still alive.

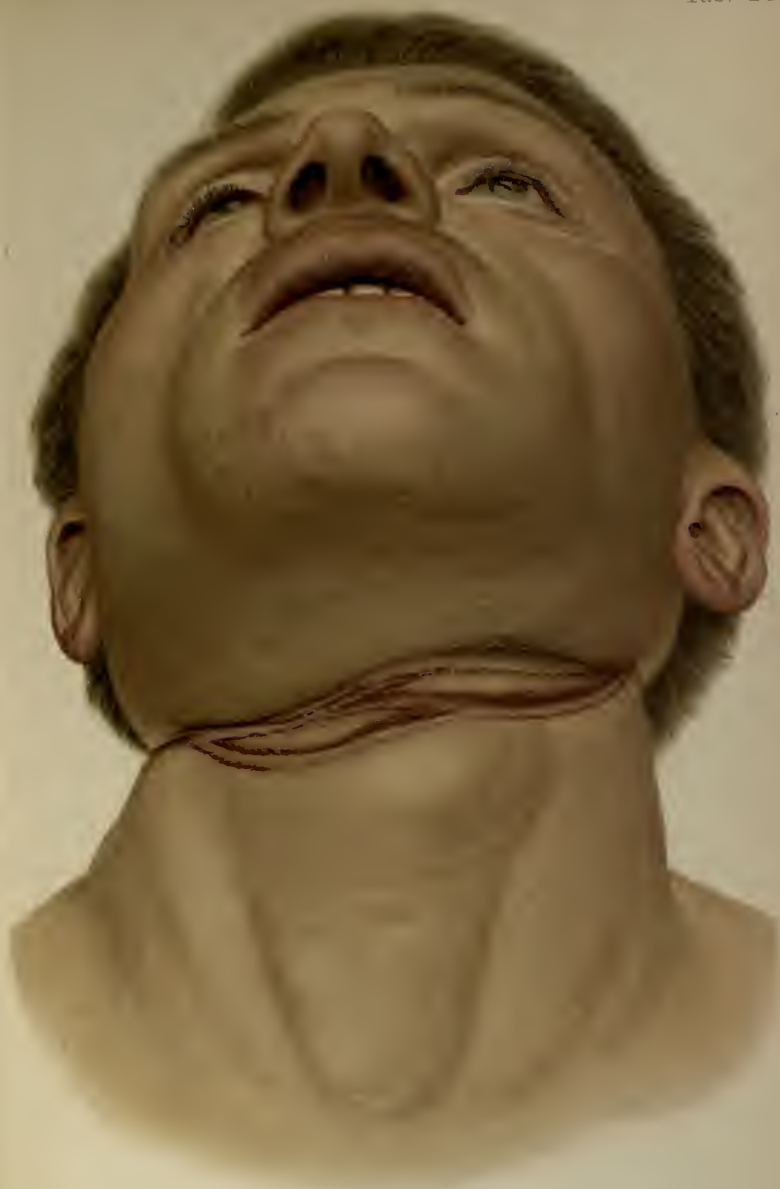





Fig. 178.



## FIGURE 178.

### **Suicide by Hanging in the Kneeling Posture.**

The illustration of the case was sent to me by Dr. Vucetic of Slavonia. The case was that of an epileptic who, during an attack of insanity, hanged himself to the door-hinge in his cell. Strangulation was produced by a torn piece of his clothing, which encircles symmetrically the anterior part of his neck and the knot of which is found at the middle of the nape of his neck. The head is inclined markedly forward. The body in the kneeling posture is in contact with the floor—at least there is found to be no interval between the latter and the knees. The constricting band around the neck is nevertheless very tense. The hands are crossed in his lap.

## FIGURES 179, 180.

### **Fig. 179.—Suicide by Hanging in a Semi-sitting Posture.**

The deceased was found hanging in the open air and dead. The rope forming the noose was wound about a clothes-line-pole stuck perpendicularly into the ground. The knot of the noose was placed at the anterior part of the neck, from which location one end of the rope ascended over the chin to the point of attachment. The head was inclined markedly backward. The nates were removed about 30 cm. from the ground, the legs outstretched and somewhat abducted, the heels resting upon the ground. The abnormal posture has arisen, on the one hand, as a result of the length of the noose; probably also, on the other hand, because, as a consequence of the weight of the body, the rope wound about the pole slipped down.

---

### **Fig. 180.—Suicide by Hanging in the Prone Posture.**

(After Bollinger.)

The case, published by O. Bollinger, of Munich, in Friedreich's *Blätter für gerichtliche Medizin*, Part I., 1889, and graciously allowed me for illustration in this atlas, was that of an insane patient affected also with disease of the spinal cord, who hanged himself by means of a long noose, formed by twisting together his sleeping-gown, which he had fastened to a bedpost. The noose was of just such length that, when the patient withdrew it somewhat from the foot of the bed, he was enabled to insert his head between it and the lower edge of the bed. As a result partly of the weight of the body, partly of the compression of the neck between the noose and the edge of the bed, strangulation ensued.

Fig. 179.



Fig. 180.







Fig. 181.

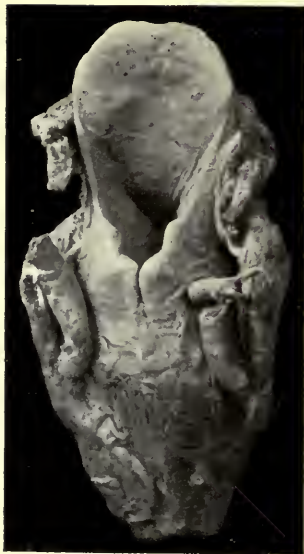
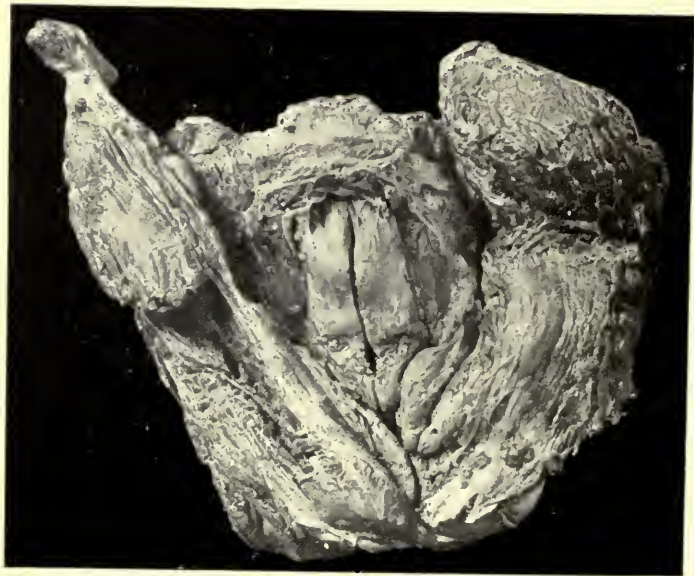


Fig. 182.



## FIGURES 181, 182, 183.

### **Fig. 181.—Fracture of the Larynx and of the Hyoid Bone in a Person Hanged.**

Larynx of a man, aged 43 years, who hanged himself in a typical manner. The furrow made by the rope coursed, as usual, between the larynx and the hyoid bone. The cornua of the latter are fractured near the extremities on both sides, and the fractured ends directed downward. The laryngeal cartilages are uninjured; on the other hand, however, the upper cornua of the thyroid cartilage are fractured—the left at its base, the right somewhat above this—and both likewise directed downward.

---

### **Fig. 182.—Bilateral Rupture of the Sterno-cleido-mastoid Muscles in a Person Hanged.**

The illustration shows the soft parts of the anterior part of the neck and the larynx of an elderly man who was found hanged. The body was large and muscular and showed marked postmortem rigidity. The larynx was ossified and very prominent. The furrow produced by the noose was situated beneath "Adam's apple" and was quite deep.

Both sterno-cleido-mastoid muscles at the level of the ligamentum cricothyreoideum were lacerated transversely from before backward. A portion of the muscular sheath and a few of the muscular fibers were preserved intact; certain of the muscular vessels were lacerated and exuded some fluid blood, which was readily washed away. The muscular stumps were otherwise pale, and revealed no sign whatever of suffusion. From one point of rupture to the other, transversely across the cricothyroid ligament, there was a furrow-like depression. The larynx itself was uninjured.

The case was evidently an instance of postmortem rupture of the muscles, produced by stretching of the neck while rigid, and occurring at the points of constriction of the sterno-cleido-mastoid muscles caused by the noose.

---

### **Fig. 183.—Fracture of the Thyroid and Cricoid Cartilages in a Person Hanged.**

A man, aged about 50 years, hanged himself with a wide strap in such a manner that the latter was placed over the lower part of the prominent thyroid cartilage and the cricothyroid ligament. As a result there occurred a single fracture of the thyroid cartilage and a double

fracture of the anterior portion of the cricoid cartilage. The former occurred along the anterior angle of the larynx, as a consequence of the compression of the larynx from before backward, and the consecutive flattening of the angle of the thyroid cartilage and the separation of its alæ; the double fracture of the cricoid cartilage was the result of the dragging inward of the ligamentum cricothyreoideum by the superimposed portion of the strap, which had as a consequence the fracturing of the middle portion of the cricoid cartilage.

---

## FIGURES 184, 185.

### Fig. 184.—Self-strangulation.

(After Bollinger.)

An insane patient, upon whom Bollinger (Friedreich's *Blätter für gerichtliche Medizin*, Part I, 1889) had performed a necropsy, ended his life by strangulation in a very peculiar manner. The body was found, as the illustration (kindly loaned me by Professor Bollinger) shows, prostrate, with almost the entire back in contact with the floor, the right foot pressed against a bedpost. About the neck was a loop-knot made of a bed-sheet torn in two, one end of which was attached to the forward bedpost. The deceased, by pressing his foot against the hind bedpost, had drawn the noose tight, and thus brought about the strangulation.

---

### Fig. 185.—Newly Born Child Killed by Having Its Throat Cut and by being Strangled.

On January 23, 1892, there was found on the street, between two heaps of paving-stones, the body of an immature, newly born child, wrapped in rags.

The body was very much decomposed; in part it was of a greenish discoloration, in part as though it had been soaked in water, boggy, greasy and moist to the touch, malodorous; in places the epidermis was absent, in places it could be readily stripped off.

The neck, below its middle, is tightly bound and thereby reduced in size by a gray band, 3 mm. in width, which doubled encircles it, and which to the right of the anterior median line is tied in a single knot and one loop. The areas of skin between the encircling bands are slightly elevated and spindle-shaped; that to the left side of the neck is 1 cm., that to the right 2 cm. in width. The protruding skin is without epidermis and of a dirty, pale violet color. The band is 53½ cm. in length. The ends forming the loop hang over the chest. After removal of the band there are found on the neck two deep pale furrows, with pale edges. They are of the same width as the constricting band, and cross on both sides of the neck.

Fig. 183.

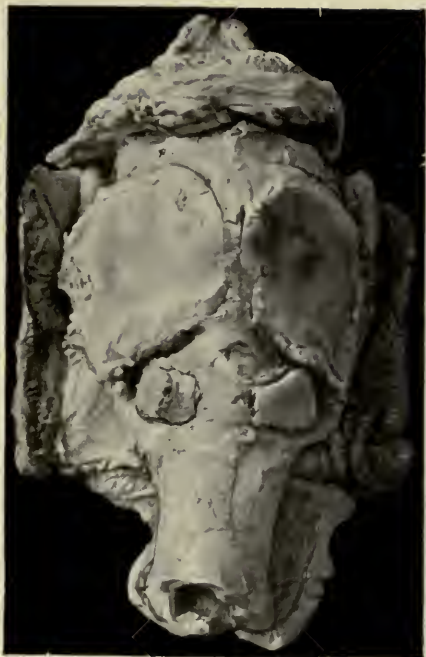

Fig. 184.

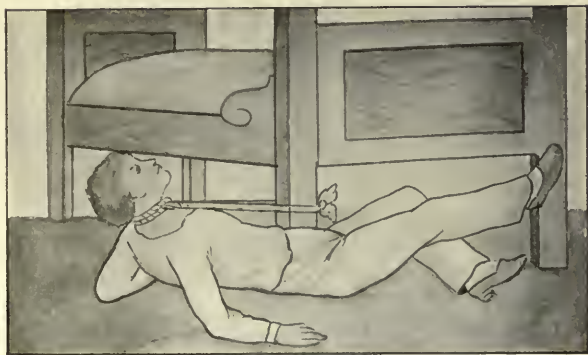
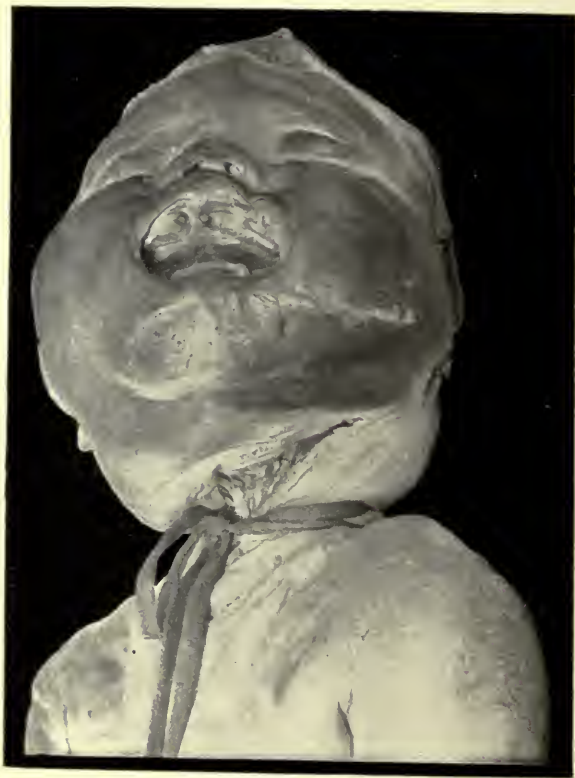


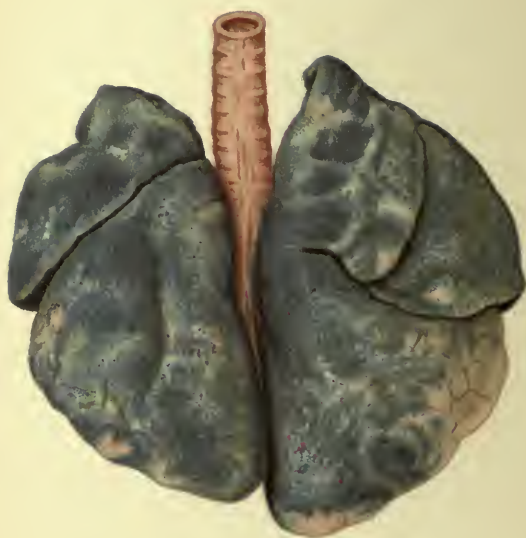

Fig. 185.







In addition, there is seen in the neck an arched incision which has its convexity directed to the right, and which is partly covered by the band. It has rather sharp edges, which have become softened by putrefaction. It begins beneath the angle of the left inferior maxilla, forming an acute angle with its lower border; thence coursing obliquely to the right and below across the anterior aspect of the neck, it ends about one and a half finger's breadth above the middle of the right clavicle, with which it also forms an acute angle. It penetrates to the cervical vertebræ, which it exposes, and divides the muscles of the anterior part of the neck, as also the trachea and the esophagus immediately below the larynx. All the wounds have sharp edges. An injury of the carotid arteries is not demonstrable. The right jugular vein, on the other hand, appears incised; but of this one cannot be positive on account of the softening of the tissues. There is no extravasation of blood in the wound. All the parts of the latter, however, appear as though soaked in water. About  $\frac{1}{2}$  cm. above and parallel with this wound there is a second. It likewise has sharp edges, is 4.5 cm. in length, but penetrates only to the subcutaneous connective tissue. It is softened as the other wound, and shows no extravasation of blood.

The necropsy, in addition, revealed only advanced putrefaction of almost all the organs—they even floated,—and general anemia. In the lungs, in addition to numerous air-bubbles of irregular size beneath the pleura, there were still recognizable larger areas, in which the pulmonary air-vesicles were preserved and uniformly filled with air.

Although symptoms of vital activity were not discovered—a fact naturally accounted for by the advanced putrefaction, and although the anemia may have been in part due to the putrefaction, in part to the imbibition by the tissues of fluid, it was nevertheless clear that an attempt had been made to kill the child by cutting its throat, and that, as it did not die immediately, it was subsequently strangled. This is a natural inference, as both injuries would have been superfluous had the child been already dead, and the strangulation itself would have been uncalled for, if the throat-cutting had already caused the death of the child.

---

## PLATE 25.

### Lungs of a Dog which was Drowned.

The direct demonstration of the fluid in which a person has been drowned and its distribution are rarely possible in human beings, as the drowning occurs usually in water, and this, when present in the lungs, does not differ much from other watery fluids, especially from that of edema. It is much better as regards definite results when the drowning occurs in a closet-well or in any other fluid containing morphologic elements, as the latter may sometimes be detected both macroscopically and microscopically within the minutest bronchi and even within the

alveoli. The most instructive pictures are, however, furnished when the drowning occurs in a colored watery fluid and the necropsy is performed soon after death—that is, before manifestations of imbibition supervene.

Such occurrences in human beings are of the greatest rarity. On the other hand, one may readily cause drowning of animals in such fluids and thus study the manner in which, in cases of drowning, the fluid in which the drowning occurred distributes itself in the affected lungs. Plate 25 illustrates an instructive example of this.

In the first place, by such experimentation one may demonstrate that the fluid in which the drowning occurs always enters the lungs; and, secondly, that less enters with the first inspiration than with the inspirations which take place after unconsciousness has developed, especially with those inspirations occurring during the so-called “terminal respiratory movements,” those which ensue after the violent manifestations of suffocation have subsided and asphyxia has supervened. The reason for this is that the fluid which at first enters is for the greater part expelled by the expiratory cough which immediately takes place.

The more healthy and the stronger the animal experimented with, the larger the quantity of aspirated fluid. On the other hand, the more emaciated and the weaker the animal the less the quantity of fluid that reaches the lungs.

It is *a priori* to be expected that even in favorable cases the lungs should not be completely filled with the aspirated fluid, as some of the residual air in the lungs remains and hinders the further entrance of the fluid. We find, therefore, in all cases, both on the external surface and on the surface of section, a mottled appearance, revealing various grades of development and transitional stages. The darkest areas contain the most fluid, the paler areas less, and the uncolored areas very little or none at all.

Even in the very darkest areas one may, on very careful observation, especially with a low-power lens, recognize groups of pulmonary alveoli containing air. Between these, however, there are frequently others, in which the pulmonary alveoli have ruptured into the interstitial tissue. It is in this manner that interstitial extravasation of the fluid causing the drowning occurs.

The distribution of the fluid in the individual lungs and parts thereof is not constant. The right lung appears to aspire more than the left, the lower lobe more than the upper, the periphery, especially the edges of the lung, less than the more centrally located portions.

The filling up of large portions of the pulmonary tissue with fluid, and as it appears frequently also its infiltration into the interstitial tissue, prevent the collapse of the lungs, and lead to that distention of them to which, for such a long time, such diagnostic importance has been attached, and which has been designated balloon-like inflation of the lungs.



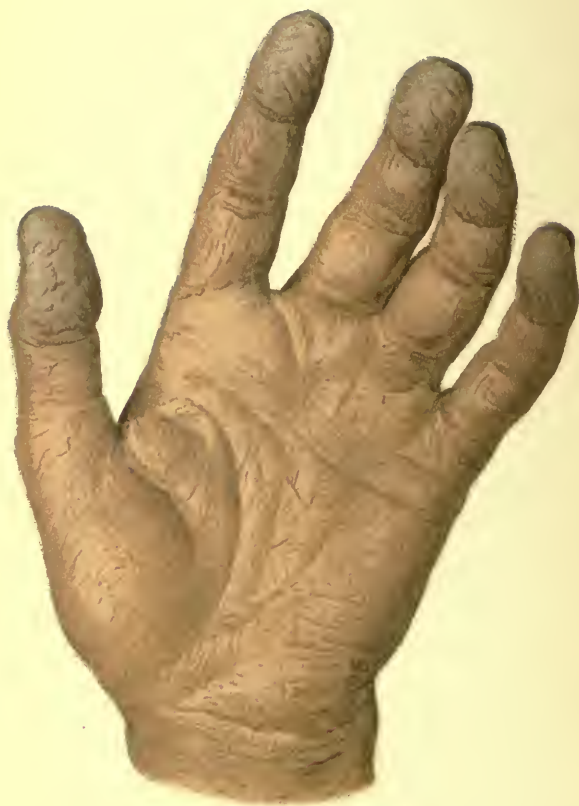

PLATE 26.

**Left Hand of a Drowned Day-laborer whose Body Remained  
in the Water 24 Hours.**

The epidermis of the tips of the fingers already show changes due to the imbibition of water. The epidermis has become pale; it is swollen and markedly wrinkled. The rest of the epidermis is, as is usual with day-laborers, thickened, in part callous, but not otherwise altered.

Had the body remained two to four days in the water, the epidermis of the thenar and hypothenar eminences would have shown changes similar to those of the tips of the fingers, and these, in the course of a few days more, would have spread over the entire palmar surface of the hand.

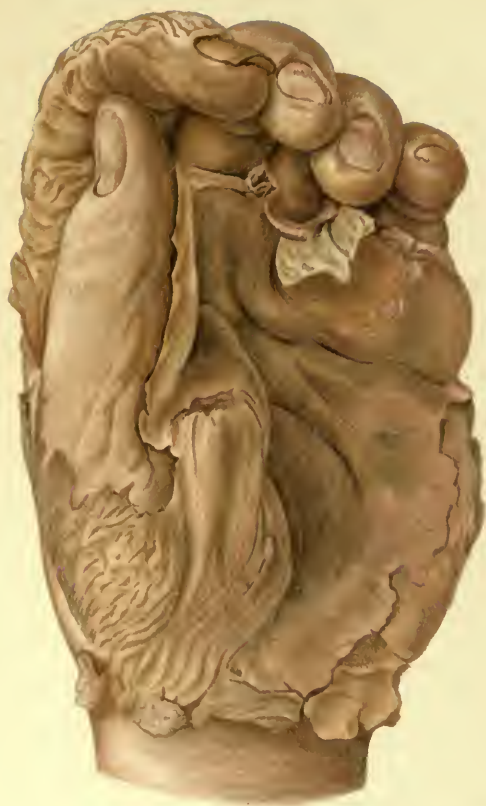## PLATE 27.

### **Left Hand of a Drowned Person whose Body had Remained in Running Water for Several Weeks.**

Necropsy February 23, 1884. The epidermis is markedly swollen, wrinkled, pale, and in part detached from the hand like a glove. The epidermis and the nail of the index-finger are still adherent, but the nails and the epidermis of the other fingers have become entirely loosened and have been washed away.

The parts thus exposed have the appearance of a gracile and well-cared-for hand. Such appearances, when the coarse epidermis and the nails have become entirely detached, may all the more readily give rise to misconceptions in respect to the social position and occupation of an unknown individual, as the matrices of the nails present a deceptive resemblance to still preserved and well-cared-for nails.

A somewhat similar appearance may also arise when, through putrefaction or scalding or burning, the epidermis and the nails become detached in a glove-like fashion.









Tab. 23.

## PLATE 28.

### **Fungus- (Algæ-) formation on a Cadaver found in Water.**

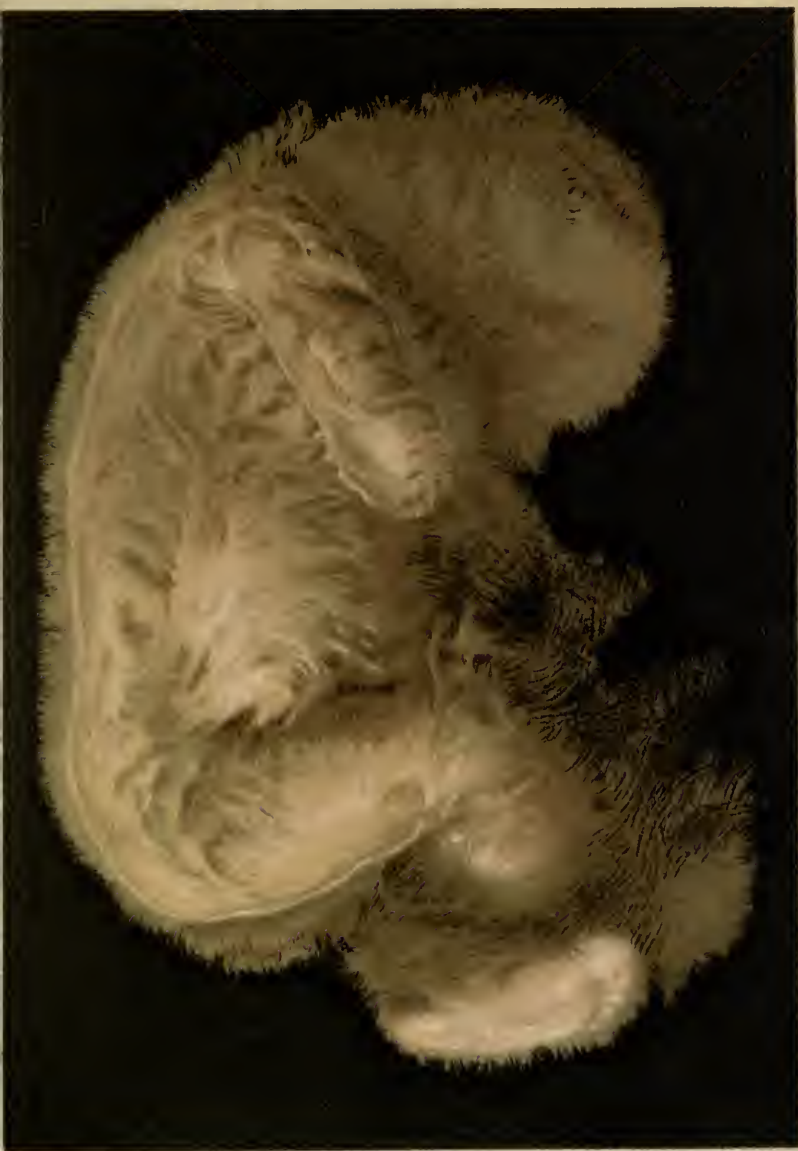Cadavers which have remained a long time in water show generally, on those parts not protected by clothing, a more or less well-developed unctuous covering, which is usually taken to be slime or mire. On more careful investigation, however, this covering is found to consist of fungi (algæ) belonging to the class phycomyces. These develop very early on the cadaver, increase very rapidly, and in a few weeks may cover the exposed portions, or, if it be altogether naked, the entire body.

Plate 28 illustrates the first stage of this process. The body is that of a newly born, immature child, which had remained fourteen days in running water. The appearances under water are depicted. The body is somewhat swollen, and of a slightly red tint, dependent upon the low temperature of the water. It is entirely covered with a colorless envelope, 1-1.5 cm. in thickness, which consists of closely interwoven filaments which float in the water and which are made up of algæ. This formation is especially well marked at the more angular portions of the body. In certain situations, as, for instance, in the popliteal spaces, about the hands and the feet, it has developed into large masses which conceal the contour of the affected parts. On the removal of the cadaver from the water this algæ-formation collapses and forms a covering much resembling moist cotton.

## PLATE 29.

Plate 29 represents the same child after it had remained four weeks in the same water. The body is completely covered with a thick coating of algæ, so that the general form of the cadaver is scarcely discernible. The algæ formation is not only more extensive and thicker and the algæ-filaments longer, but they have also become discolored. This is due, on the one hand, to degeneration of numerous portions of the algæ-formation, and, on the other, to various precipitates. These are particularly the ferri oxidum hydratum, from the iron sewer-pipes; but, in addition, various kinds of filth which readily become deposited upon a cadaver immersed in running water. These, when the body is removed from the water and the algæ-formation collapses, give to the entire covering more and more the appearance of ordinary mire.

Upon the extent of the development of this formation of algæ—during the first week at least—an opinion may be based as to how long the cadaver has been in the water. Particularly is one justified in the conclusion that the body has been in the water but a few (at the most six or seven) days, when as yet no development of algæ is found. The development takes place somewhat slower during the winter than during summer, but occurs in water of 8° C. and even lower temperature.









## PLATE 30.

### Alterations of the Blood due to Irritant Poisons.

As is well known, the irritant poisons are divided into two groups according to the manner in which they disturb the organic tissues at their point of application; that is, upon whether they produce but slight cauterization or a deeper eschar. In the first group are those which give rise to eschar-formation through coagulation of the albuminous bodies; in the second, those which cause, as a result of their application, solution, swelling, and softening of the tissues.

The first group comprises the mineral acids, carbolic acid, oxalic acid, and the metallic irritant poisons, especially mercuric bichlorid; the second, caustic potash and caustic soda—potassium and sodium hydrate. We obtain, as a primary result of the application of the substances of the first-mentioned category to a mucous membrane or to an organ, a grayish-white, cloudy, dried alteration of the affected surface; in contradistinction to this, the application of a solution of potassium or sodium hydrate results in a clearing up of the affected tissues, which assume a swollen appearance. As a consequence of the solution of the blood which occurs at the same time, through imbibition, they later become darker in color.

Nor does the primary picture produced by the coagulating irritant poisons always persist. Subsequently it not uncommonly changes, the change being especially dependent upon the manner in which the blood of the affected part and its immediate vicinity becomes altered as a further effect of the irritant.

In this respect the coagulating irritant poisons vary. Sulphuric acid, hydrochloric acid, and oxalic acid not only coagulate the blood, but after a short time change the hemoglobin in part into hematin. As a consequence, there subsequently ensues a brownish-black or black imbibition of the region the seat of the eschar-formation. On the other hand, carbolic acid and mercuric bichlorid produce only a coagulation of the blood, but no solution of the hemoglobin. There occurs, therefore, no hemorrhagic imbibition of the eschar, and the latter, even after prolonged application of the irritant, presents its original white or grayish-white appearance.

In Plate 30 we see these processes depicted as they occur in a test-tube. In *a* we see blood after the addition of moderately concentrated sulphuric acid. We see in the lower third of the test-tube the blackish coagulum, and above this the acid, brownish-black solution of hematin. The same appearances, but in a darker shade, are seen in *b*, which shows the effect of the addition of hydrochloric acid to blood.

In *c* we find a complete solution of the entire blood produced by a solution of sodium hydrate. The fibrin was not only early dissolved, but the hemoglobin was also changed to hematin in alkaline solution.

On the other hand, in *d* and *e* (carbolic acid and mercuric bichlorid) we see the blood only coagulated, and above this a deep layer of almost colorless fluid, which evidently contains none of the coloring-matter of the blood. We observe, in addition, that the color of the blood-coagula differs from the color of the coagula or of the solutions of the blood produced by the addition of sulphuric or hydrochloric acid; that is, they are not black or brownish-black, but after the addition of carbolic acid the coagulum is of a bright brick-red color, whereas after the addition

of mercuric bichlorid it is of a grayish-violet color. In case of poisoning with these irritants these colors glimmer through the white epithelial eschar, and thus independently of other peculiarities assist in the diagnosis or differential diagnosis of the variety of poisoning.

---

## PLATE 31.

### Poisoning by Caustic Soda.

M. C., aged 21 years, with suicidal intent, swallowed a large quantity of a so-called solution of sodium hydrate (about 40 per cent. sodium hydrate). He became immediately ill with symptoms of violent gastro-enteritis; he vomited blackish masses, and revealed on examination a "swollen mouth." A neighboring physician, being summoned, administered vinegar as an antidote, and ordered the removal of the patient to a neighboring hospital. Here, despite copious vomiting and lavage of the stomach, he died at the end of two days.

The body revealed marked congestion and swelling of the entire mucous membrane of the mouth. The epithelium was in part separated from the underlying structures; in part it was still attached in the form of soft, white, turbid shreds. The epithelium was absent from the mucous membrane of the entire esophagus. The mucous membrane itself was softened throughout, swollen, markedly congested, and of a brown color, increasing in intensity below.

The stomach contains coffee-colored, turbid fluid. The epithelium is absent from the entire mucous membrane. The mucous membrane itself is soft throughout, markedly swollen, and arranged in coarse folds, of a brownish-black color. This discoloration is especially marked at the crests of the rugæ, at which situations fading ecchymoses and small superficial areas of loss of substance are also to be noticed. On section the mucous membrane is of a brownish-black color, dependent upon imbibition of hematin in solution. This color diminishes in intensity in the depths of the mucous membrane, but here and there extends to the submucosa. In addition, the mucous membrane is injected and shows in places hemorrhagic infiltration. The submucous cellular tissue is edematous. The blood in the vessels is coagulated, but the coagula are soft.

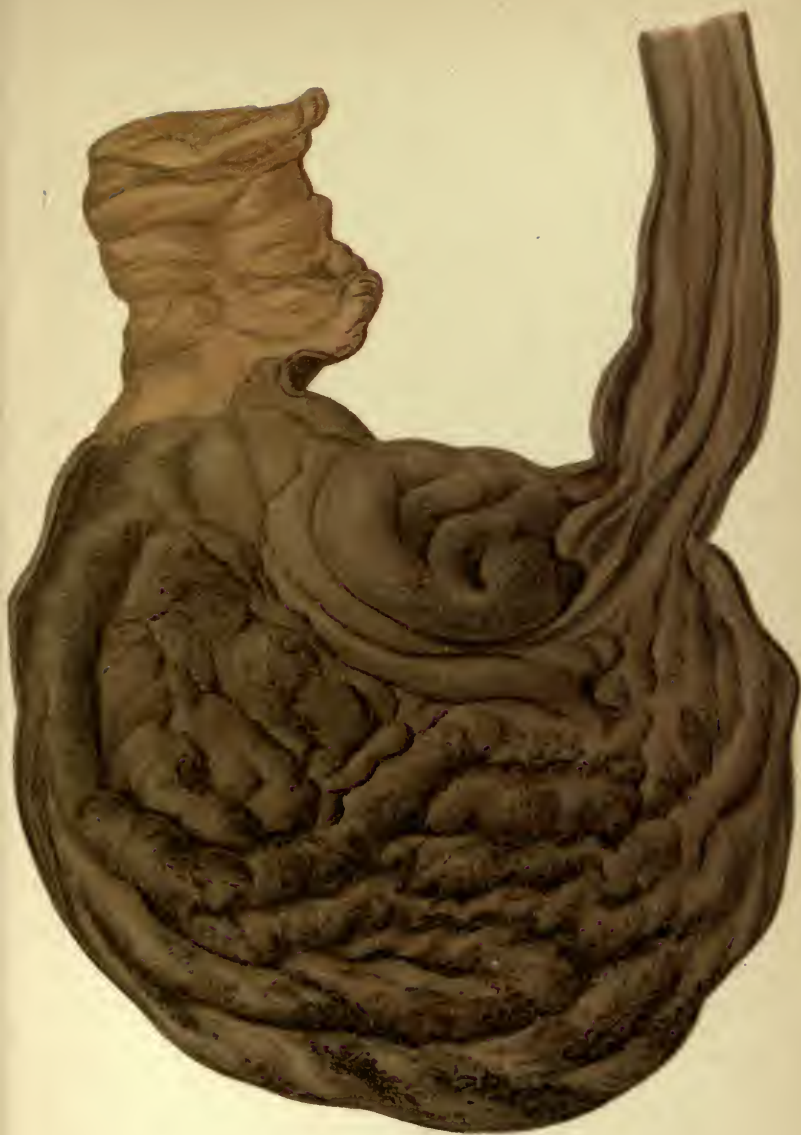The mucous membrane of the duodenum is relaxed, and shows slight imbibition of bile, but no other changes.

---

## PLATE 32.

### Poisoning with Concentrated Sodium Hydrate Colored with Ultramarine-blue.

The preparation is from a man, aged 50 years, who was brought to the hospital during the night with the history that he had purposely poisoned himself with a solution of caustic soda colored with ultramarine-blue, which he had for sale in his shop.













Externally no blue discoloration was to be noticed; but there were marked congestion and swelling of the lips, with partial desquamation of the swollen epithelium. On the other hand, the epithelium of the base of the tongue was of a blue color, cloudy, and could be readily removed. The mucous membrane of the mouth and pharynx was congested and swollen. On account of edema of the glottis tracheotomy was performed, but the patient died the next morning.

The necropsy revealed, in addition to the changes in the mouth and pharynx already mentioned, a marked edema of the glottis and of the lungs. In addition, there was an intense blue discoloration of the epithelium throughout the length of the esophagus. The epithelium was also much swollen and cloudy, and arranged in coarse folds; the mucous membrane beneath was congested and swollen. The stomach was moderately contracted and filled with a blackish, turbid, alkaline material, which was soapy and slippery to the touch, and in which there were demonstrable soft ragged particles (shreds of desquamated epithelium) which were of a blue color and appeared as though coagulated. The mucous membrane is throughout wanting in epithelium; it is markedly swollen, arranged in coarse rugæ, and colored almost uniformly black. The swelling and the blackish discoloration affect the entire thickness of the hemorrhagically infiltrated mucous membrane, and also reach into the hyperemic and edematous submucous cellular tissue. The larger vessels of this latter, as also the coronary vessels of the stomach, contain soft blood-coagula.

In the region of the pylorus, and from here for a distance of about 50 cm. into the jejunum, the mucous membrane is somewhat altered; it is flabby, as though edematous, and throughout of a bright blue color, which color diminishes in intensity toward the lower part.

To avoid accidents, the coloring with ultramarine-blue of solutions of caustic soda, commonly for sale in the shops, is extensively and with reason recommended and employed. The color to which this gives rise in the viscera can, in a given case, be made use of in the diagnosis of a case of poisoning by caustic soda, or in differentiating this from similar poisonings, such, for instance, as poisoning with sulphuric or hydrochloric acid. If one add ultramarine-blue to such acids, the color becomes dissipated, with the liberation of sulphur and sulphuretted hydrogen. The blue color in such poisonings would therefore not be present.

---

## PLATE 33.

### **Suicidal Poisoning with Concentrated Sulphuric Acid.**

A. M., aged 33 years, a day-laborer, was found groaning and vomiting in a city park. He could speak with difficulty, and asserted that a short time previously, because of a satiety of life, he had drunk a poisonous fluid.

In the hospital he vomited a blackish material, which was markedly acid in reaction and in which free sulphuric acid was demonstrable. He sank rapidly, and died an hour after his admission.

The body revealed extensive, brown, leather-like, dried areas on and about the lips. On both sides these extended from the angles of the mouth to the lower jaw, and on the right side also to the middle of the neck. The oral epithelium was grayish-white, dry, and extensively sep-

arated in shreds; the mucous membrane beneath was congested and swollen, the superficial vessels injected and black. The mucous membrane of the entire esophagus showed similar alterations, and was at the same time arranged in rigid folds, and appeared superficially as though cooked.

On opening the peritoneal cavity there was found therein a brownish, turbid fluid, which was very acid in reaction and which contained crumbling flocculi and vestiges of food. Both layers of the peritoneum were of a dirty gray color, cloudy, and stiff,—as though cooked. The vessels were injected and black, and from them could be expressed black, friable blood-cylinders. These changes extended over all the abdominal viscera, affecting some superficially, others more deeply. In particular, the greater part of the intestines appeared as though cooked, cloudy, rigid, and completely filled with black cylinders of blood. The mesentery showed similar changes.

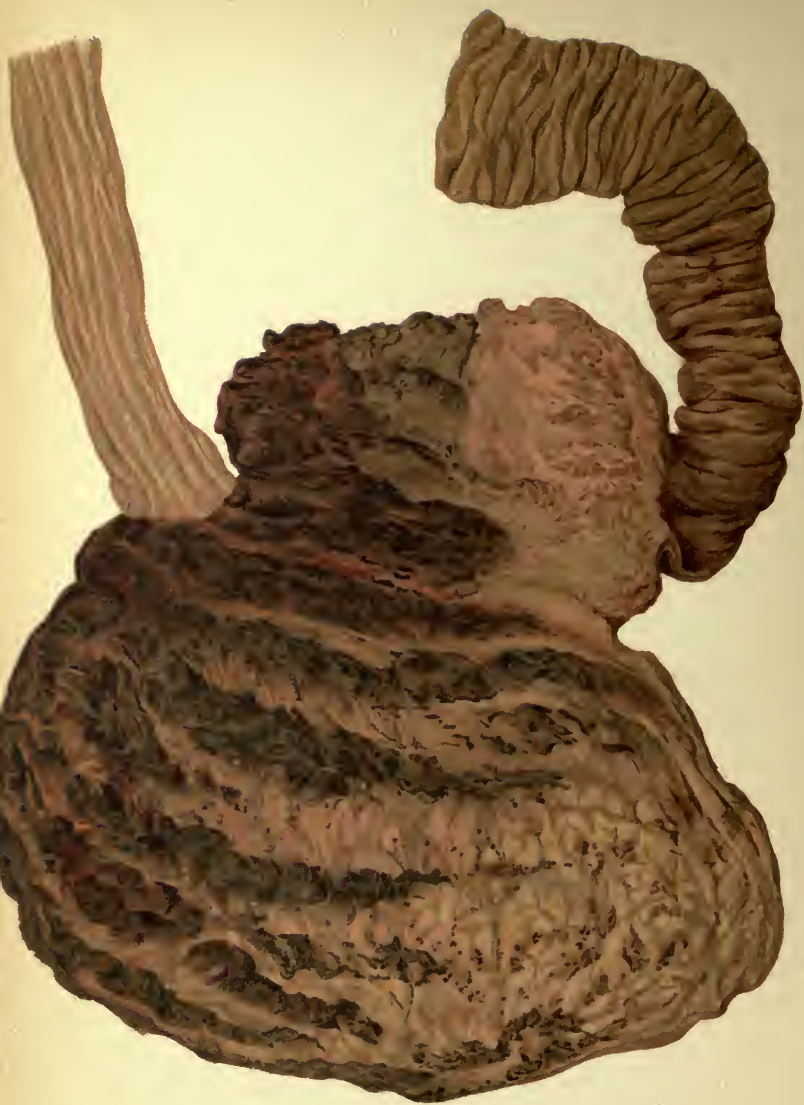The stomach is contracted; appears externally as though cooked. The coronary vessels are black and distended; from them blackish dried blood may be expressed. At the fundus of the stomach there is a perforation—patulous for two fingers—with thinned, ragged edges. Through this the brownish acid masses found in the abdominal cavity escaped from the stomach, and engendered the above described lesions.

The mucous membrane of the stomach is wanting in epithelium throughout; it has been converted into a black, hemorrhagically infiltrated eschar. In many places it is entirely absent, so that the swollen connective tissue, discolored brown by imbibition and pervaded by a network of black vessels, here and there even exposes the peritoneum. The latter is particularly the case at the fundus of the stomach in the neighborhood of the perforation, toward which the walls of the stomach become very much thinned and the ragged margins of which are finally formed by the perforated peritoneum.

The perforation of the stomach must have occurred soon after the ingestion of the acid, which fact explains the rapid course of the case, especially the rapid collapse of the patient. At all events, it occurred during life, as otherwise the tense injection of the vessels of the mesentery with rigid, coagulated masses of blood is inexplicable.

In view of the large quantity and the concentration of the sulphuric acid employed, as indicated by the anatomical lesions, there can be no doubt as to the case being one of suicide; and this fact is made clear by the attendant circumstances of the case.





## PLATE 34.

### Poisoning with Dilute Sulphuric Acid.

A servant, aged 20 years, after an unpleasantness with her mistress, drank about 50 grams of dilute (about 20 per cent.) sulphuric acid. Having vomited violently at home and complained of intense pain in the organs of deglutition and in the abdomen, she was immediately taken to a hospital. On admission, examination revealed whitish-gray escharosis of the entire surface of the mouth, and of the skin below the angles of the mouth; in addition, pain and tenderness in the region of the stomach, vomiting of blackish masses—acid in reaction, and manifestations of collapse. Despite the employment of antidotes the girl died the following day, twenty-four hours after she had taken the poison.

The necropsy revealed whitish-gray escharosis throughout the mouth; partial desquamation of the epithelium of the oral mucous membrane; inflammatory congestion and swelling of the mucous membrane itself; yellowish-brown, dried, leather-like streaks coursing from the angles of the mouth; coffee-colored contents of the stomach; and, in addition, the appearances depicted in the accompanying illustration.

The mucous membrane of the esophagus is swollen and arranged in very rigid longitudinal folds. The epithelium is grayish-white, cloudy, thickened, appears as though cooked, and shows at the crests of the folds fine transverse tears.

On the inner aspect of the wall of the stomach one can distinguish two areas, one of which is colored brownish-black to black, the other being dirty pale violet in color, with here and there scattered blackish points. The first, affecting more particularly the left half of the stomach, especially the posterior and lower wall, radiates along the coarse rugæ of the stomach toward the right half. These are the portions of the stomach which the sulphuric acid first met, and with which it remained longest in contact. Here in varying degree, through coagulation, the mucous membrane has become the seat of eschar-formation, and shows extensive hemorrhagic infiltration and imbibition. The hemoglobin of the blood, both that within and that without the vessels, has been converted into hematin in acid solution, and has given rise to the brownish-black to black discoloration of the eschar. This eschar-formation affects especially the crests of the rugæ. The blood in the small vessels of the affected mucous membrane is almost completely coagulated, and through the withdrawal of its watery constituents has been converted into friable blood-cylinders. The cellular tissue beneath the eschar is swollen and edematous, and shows here and there hemorrhagic infiltration.

The mucous membrane between the rugæ the seat of escharosis, as also the mucous membrane of the entire right side of the stomach with the exception of certain small brownish-black areas, is, with the sub-mucous cellular tissue, markedly swollen, turgid, and projects above the eschars.

The mucous membrane of the duodenum is likewise swollen, markedly injected, and reveals slight grayish-white cloudiness of the epithelium.

## PLATE 35.

### Hydrochloric-acid Poisoning.

F. P., a servant, aged 46 years, was brought to the hospital, January 23d, with contusions of both ears and a fracture of the inferior maxilla. He asserted that he had received these injuries eight days previously by falling from a wagon. He was markedly dyspneic, and died at the end of three days, with tetanic convulsions.

The necropsy revealed healing contused wounds of both auricles and a diagonal fracture of the inferior maxilla. This was situated between the middle incisor teeth and showed some suppurative in the neighborhood. In addition there was extensive escharosis of the mucous membrane of all the organs of deglutition, the stomach, and the upper part of the small intestine. These lesions had evidently been produced by the ingestion of hydrochloric acid, as the filtrate of the contents of the stomach produced no precipitation of barium chlorid, but gave rise to a marked precipitate when added to a solution of nitrate of silver.

The epithelium of the oral cavity and of the esophagus is in great part desquamated, but here and there still attached as grayish-white shreds. The mucous membrane is congested, swollen, slate-colored, cloudy, and pervaded by a network of blood-vessels injected with coffee-colored blood.

In the stomach there was coffee-colored fluid, markedly acid in reaction, and containing particles of food. The mucous membrane of the entire fundus, as also that along the greater curvature as far as the pylorus, is desquamated. The submucosa is black, flabby, ragged, and its vessels filled with thickened blood. The muscularis and the peritoneum beneath in many places are as though cooked. The remainder of the mucous membrane is pale, cloudy, and edematous.

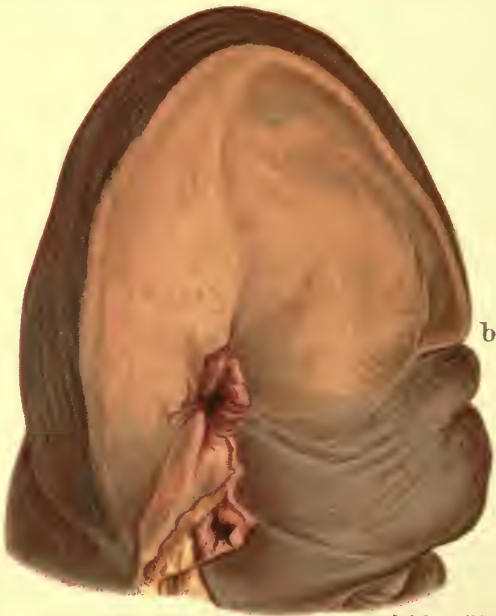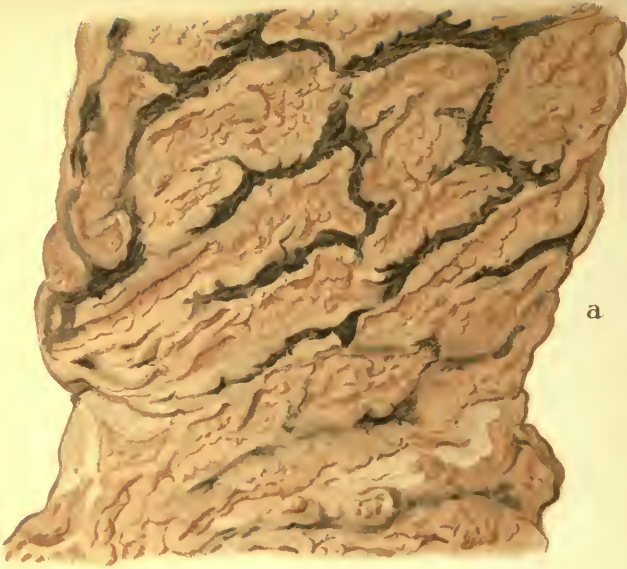
Of especial interest are the inner aspect of the duodenum and the adjoining portion of the jejunum. Here one notices a rather coarse black network, and between the meshes of this, roughened mucous membrane which appears as though cooked. The network corresponds with the crests of the folds of mucous membrane—the *valvulae conniventes*—the seat of the most marked escharosis. The mucous membrane is absent from certain areas, so that the submucosa is exposed. This shows hemorrhagic infiltration and discoloration due to imbibition of hematin in solution. The grayish-yellow areas within this network correspond with the depressions between the *valvulae conniventes*—that is, with the less affected portions of the wall of the bowel. To these portions the mucous membrane with its glands, though the seat of eschar-formation and coagulation, is still attached.

The organs adjoining the stomach appeared superficially as though cooked, and the blood in the portal vein, as also that in the aorta, was









coagulated to a friable dried mass. From the latter finding, as also from the distribution of the escharosis, which could have been produced only by a large quantity of the poison, the conclusion was warranted that the poison had been taken shortly before death, probably in the hospital, and evidently with suicidal intent. This supposition is in accord with the statements of the hospital attendants, that the patient had not vomited, and that having been to the closet during the evening, he was found dead in bed the following morning.

No additional information could be ascertained concerning the fracture of the inferior maxilla nor the injuries to the external ears. Their condition agreed with the assertion of the deceased that they occurred eight days prior to his admission to the hospital, but whether he was the victim of another or whether he produced them himself—possibly with suicidal intent—is incapable of elucidation.

---

## PLATE 36.

FIG. *a*.—A portion of the duodenum from the case of hydrochloric-acid poisoning illustrated in Plate 35—somewhat enlarged. It illustrates, on the one hand, the grayish-white escharosis of the mucous membrane and its glands, and, on the other, the black, injected, stained (with hematin) submucosa, corresponding with the crests of the valvule conniventes. This has been exposed by the destruction of the mucous membrane, and presents itself as a black network.

FIG. *b*.—Diffusion of the irritant poison through the wall of the stomach to the adjoining organs. A case of carbolic-acid poisoning, in which the poison diffused itself through the fundus of the stomach to the inner surface of the spleen.

The fundus of the stomach appeared throughout its entire thickness as though cooked; it was rigid, and of a pale reddish color. Similar changes are also noticeable on the inner surface of the spleen and for a distance of  $\frac{1}{2}$  cm. into the substance of the organ. These can have arisen only through diffusion of the poison through the wall of the fundus of the stomach.

## PLATE 37.

### Poisoning with Concentrated Nitric Acid.

P. B., a servant, aged 36 years, on November 21st, at 9 A. M., swallowed a "large quantity" of nitric acid. At 11 A. M. she was brought to the hospital vomiting, and died the same day at 4 P. M. The motive prompting the deed is said to have been a very painful affection of the head, but particulars could not be ascertained.

The body revealed a remarkable yellow discoloration of the skin about the mouth, with streaks of similar discoloration radiating toward the lower jaw. In addition, the epithelium of the oral mucous membrane was in great part yellowish in color, cloudy, thickened, and could be readily removed. The mucous membrane was pale yellow in color, and appeared as though cooked.

The epithelium of the esophagus is of a uniform bright yellow color throughout; it is arranged in rigid longitudinal folds, is thickened, cloudy, friable, and readily detachable. The mucous membrane beneath appears as though cooked; it has a pale yellowish tinge, and is pervaded with black injected vessels.

The stomach is markedly contracted, and contains yellowish, friable, crumbling material with which are mixed numerous, small, blackish, crumbling blood-coagula. The entire mucous membrane of the stomach has been converted into a bright yellow, dried, fissured eschar. Its surface is irregular; in many situations it is desquamated or becoming detached. The submucosa which is thus exposed is ragged, in part it is yellow in color, in part blackish through imbibition. It presents numerous friable, cylindrical blood-coagula, some of which are contained within the vessels, some project from the vessels, while others are free. The deeper layers of the wall of the stomach are thickened, appear as though cooked, but are without especial yellow discoloration. The coronary vessels of the stomach are distended with firm blood-coagula. In the neighborhood of, and along the entire course of the greater curvature of the stomach, beneath the peritoneum, there are numerous, bean-sized extravasations of blood.

The duodenum is also rigid—as though cooked. Its mucous membrane has also been converted into a bright yellow eschar; it is thickened, and arranged in coarse folds, at the crests of which the mucous membrane is wanting, thus exposing the ragged, hemorrhagically infiltrated submucosa.

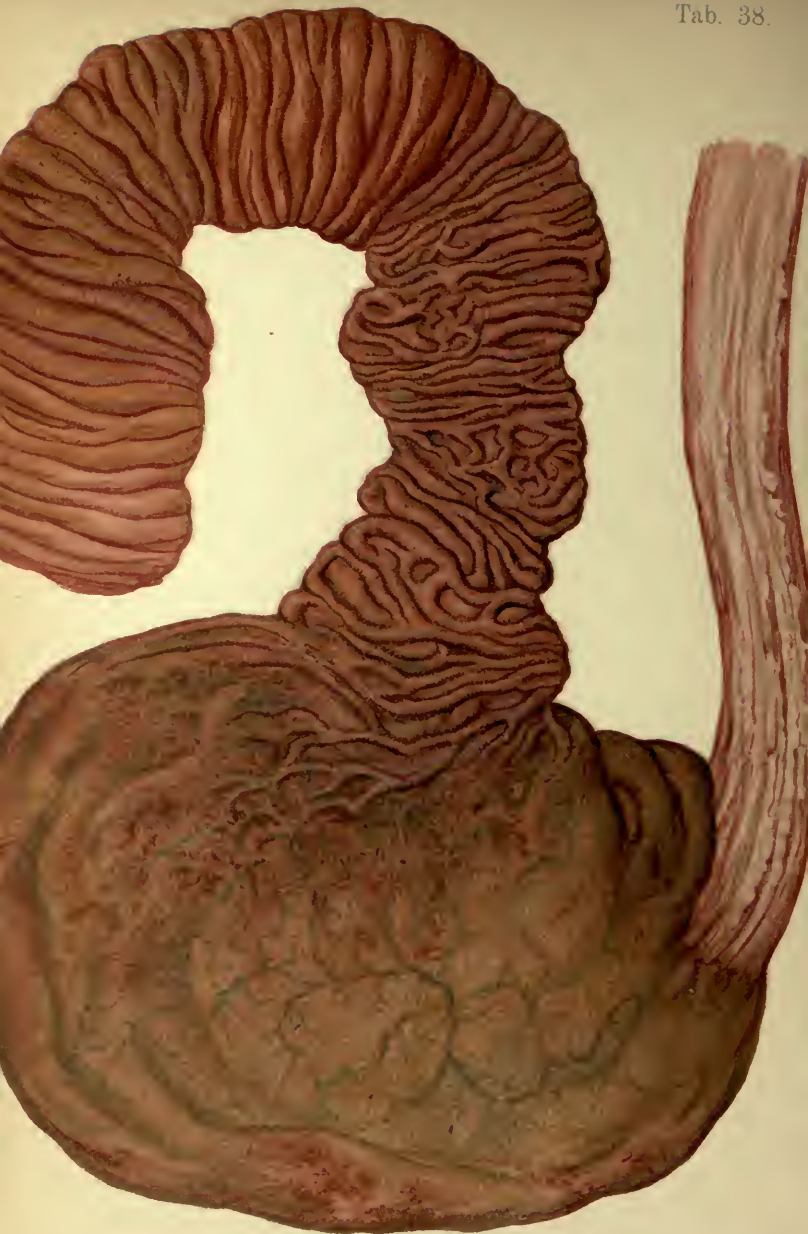The organs adjoining the stomach appear superficially as though cooked, and are of a pale yellowish color.

This yellowish discoloration is a special characteristic of eschar-formation dependent upon the application of nitric acid. According to the generally accepted view, it is due to the formation of xanthoprotein, and is especially noticeable on epidermal and epithelial structures. It is produced, however, only by the concentrated acid, the application of the dilute acid being followed by its development to a slight extent only or not at all. There may, therefore, occur instances of nitric-acid poisoning without any yellowish discoloration.









## PLATE 38.

### Poisoning with Carbolic Acid. Suicide or Accident?

J. M., a laborer, aged 51 years, at 5.45 A. M., drank from a bottle labelled "Vöslauer Goldeck," but which, however, contained fluid (90 per cent.) carbolic acid. The bottle is said to have been filled to the height of the label, but after the draught to have contained but about a teaspoonful, so that about 80 c.c. of carbolic acid must have been swallowed. The bottle and its contents belonged to a woman who employed the carbolic acid for the extermination of vermin. On the other hand, it was ascertained that the deceased had frequently spoken of a surfeit of life, and had latterly been an assistant to an apothecary. M. vomited immediately, became unconscious, and died at the end of about a half hour.

At the necropsy the lips were found of a reddish-brown color and dried. The epithelium of the mouth and pharynx was grayish-white, cloudy, and thickened, in part detachable as small, grayish-white shreds. The epithelium of the entire esophagus was arranged in longitudinal folds, pure white in color, rigid, and opaque. The mucous membrane itself, glimmering through, was pale red in color.

The stomach is much distended and flabby; its mucous membrane is pale reddish in color and shows prominent, rather excessively filled vessels. The organ contains about 500 c.c. of a watery, whey-like fluid, which is markedly acid in reaction and has a distinct odor of carbolic acid. The fundus of the stomach is without indications of marked alteration; the mucous membrane is grayish-red, soft, and rather irregular. In the region of the pylorus, however, as also along the lesser curvature, the mucous membrane is arranged in rigid folds, thickened, of a grayish-red color, with milky-white, cloudy epithelium. This cauterization, giving an appearance as though the tissue were cooked, in the neighborhood of the pylorus affects the entire thickness of the wall of the stomach, at certain diffuse areas penetrating to the peritoneum, which in these situations appears congested. It affects also the superficial portion of the adjoining surface of the liver. It increases in intensity toward the pylorus and continues uniformly through the entire duodenum to the beginning of the jejunum, where the mucous membrane becomes again soft and relaxed. For a distance of 30 cm. further, however, it is congested and flabby, and reveals here and there at the crests of the rugæ slight superficial necroses.

From these lesions it is evident, despite the slight cauterization of the stomach, a circumstance readily accounted for by the fact of the stomach being filled at the time of the taking the poison, that a large quantity of carbolic acid, at all events more than a single mouthful, was taken. The fact of such a quantity being swallowed of itself renders probable the supposition that the poison, which even on the lips engenders intense burning, was taken intentionally.

As, in addition, carbolic acid, because of its peculiarities, is well known to the laity, and as the deceased having served for a time as assistant to an apothecary, must have been especially well acquainted with it, it is extremely likely that he attempted to terminate his life in this manner. Confirmatory evidence of this view is furnished in the repeated expressions of a satiety of life of the deceased, and in the tuberculosis of the apices of both lungs with which he had been for a long time affected.

---

## PLATE 39.

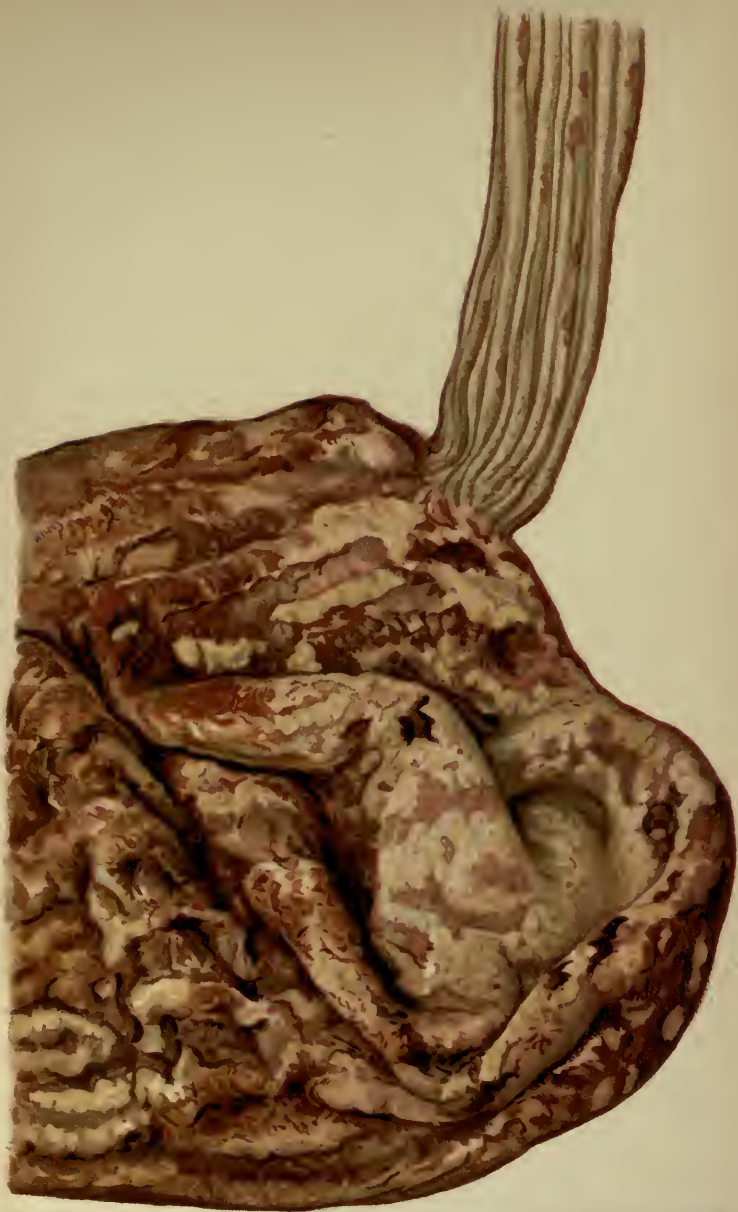### Poisoning with Carbolic Acid. Suicide.

A man, aged 20 years, was found dead before the door of the general hospital at 2 A. M. Beside him was a bottle which had the odor of carbolic acid.

The lips were brownish-red, dried. The epithelium of the mouth and pharynx was throughout white and slightly cauterized; here and there it could be detached. The mucous membrane beneath was pale; that about the arytenoid cartilages and the uvula edematous. The mucous membrane of the esophagus to the cardia was whitish, cloudy, and arranged in longitudinal folds; the epithelium readily detachable.

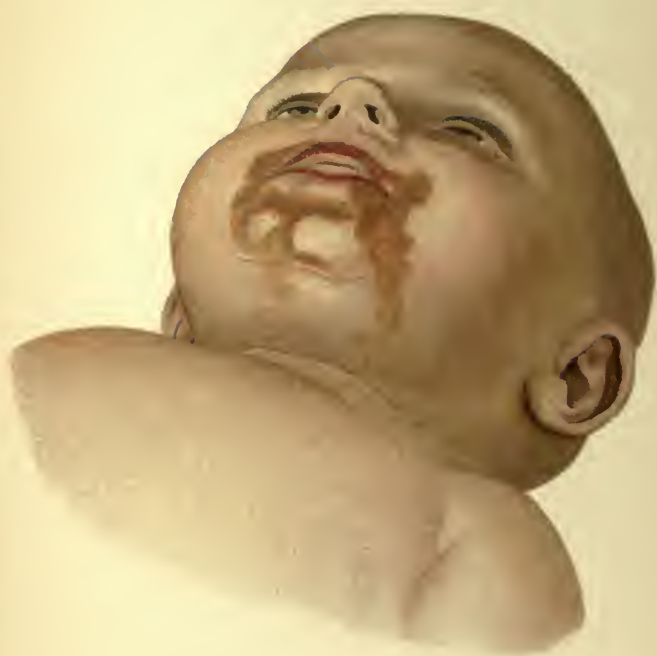The stomach is contracted, firm to the touch. Externally it is partly pale, partly, especially the fundus, violet in color, with bright-red, markedly injected vessels. It contains about 100 c.c. of a bright-red, whey-like, turbid fluid, which is slightly acid in reaction and has a strong odor of carbolic acid. The mucous membrane throughout almost the entire stomach is arranged in rigid folds and appears as though cooked. It is pure white in color, except in the recesses of the rugæ, especially toward the pylorus, where it is better preserved. In these situations it is of a red color, which color is even transmitted through the markedly cauterized areas. In certain situations, especially at the crests of the rugæ, the otherwise milky-white, cauterized epithelium has become desquamated and exposes the bright-red, hemorrhagically infiltrated mucous membrane.

There were no further alterations either in the intestines nor in any of the other organs.









## PLATE 40.

### **Cauterization of the Lips and the Region about the Mouth with Lysol.**

During an evening, a decrepit woman, aged 70 years, administered to her grandchild, aged 6 months, a teaspoonful of concentrated lysol, instead of some medicine. The child began immediately to cry; he became restless and dyspneic, and died the following day. The external examination revealed on the lips and about the mouth the appearances depicted in the illustration, and which of themselves indicate the ingestion of an irritant fluid. The external margin of the lips is congested and swollen; the inner, as also the epithelium of the entire anterior part of the oral mucous membrane, grayish-white and cloudy. The skin about the mouth, and from the lower lip and angles of the mouth to the chin and at the left side also to the neck, is of a brownish-yellow color and of leathery consistency. These changes affect in general the upper layers, only here and there the deeper layers of the skin. Beneath them there is no marked congestion nor swelling. These alterations in the skin are not essentially different from those observed after the application of liquor potassæ, but are to be distinguished from those produced by sulphuric acid by their greater softness, by their more brownish color, and by the absence of injected vessels filled with dried black blood.

The internal examination revealed the epithelium of the mucous membrane of the mouth, the pharynx, the esophagus, and the entrance to the larynx, whitish gray and cloudy; and, in addition, a bilateral lobular pneumonia.

## PLATE 41.

### Acute Poisoning with Corrosive Sublimate.

The stomach of a hospital midwife who had poisoned herself with a concentrated solution of corrosive sublimate and who, with manifestations of rapid collapse, died at the end of four hours. Prior to death she had vomited grayish-white, turbid, odorless masses which resembled coagulated albumin, and the mucous membrane of the lips, mouth, and pharynx presented a diffuse, grayish-white escharotic appearance.

The necropsy revealed, in addition to this latter described condition, a grayish-white, cloudy appearance of the mucous membrane of the entire esophagus. These changes affected not only the epithelium, which was arranged in rigid folds, but also the deeper layers of the mucous membrane, beneath which there was a moderate hyperemia, but otherwise no alterations.

The stomach was contracted, firm to the touch, of grayish-white color on the right postero-external surface and at the fundus, and appeared as though cooked. These changes extended also to the inner surface of the spleen. The remainder of the peritoneal covering was pale and smooth.

The stomach contained a large quantity of coagulated mucus. The gastric mucous membrane is, as appears from the illustration, of a peculiar and uniform pale violet color, rigid, thickened, dried, and arranged in coarse folds. These alterations extend through the entire mucous membrane, here and there also to the submucosa, and at the fundus of the stomach, especially at its posterior aspect, even through the entire wall of the organ. It is thus apparent on the peritoneal surface of the organ and even in the superficial portion of the spleen. The changes are those of coagulation-necrosis of the tissues, which latter macroscopically and microscopically appear as though hardened, preserving their histologic structure.

The peculiar color of the inner wall of the stomach results from the association of the white color of the escharotic tissue, particularly the epithelium, and the mouse-gray color—glimmering through the upper strata—of the blood in the vessels of the mucous membrane which has been coagulated by the sublimate.

Unfortunately this color did not persist long. On the following day the preparation was more of a bluish-gray color, and became even darker when placed in alcohol.

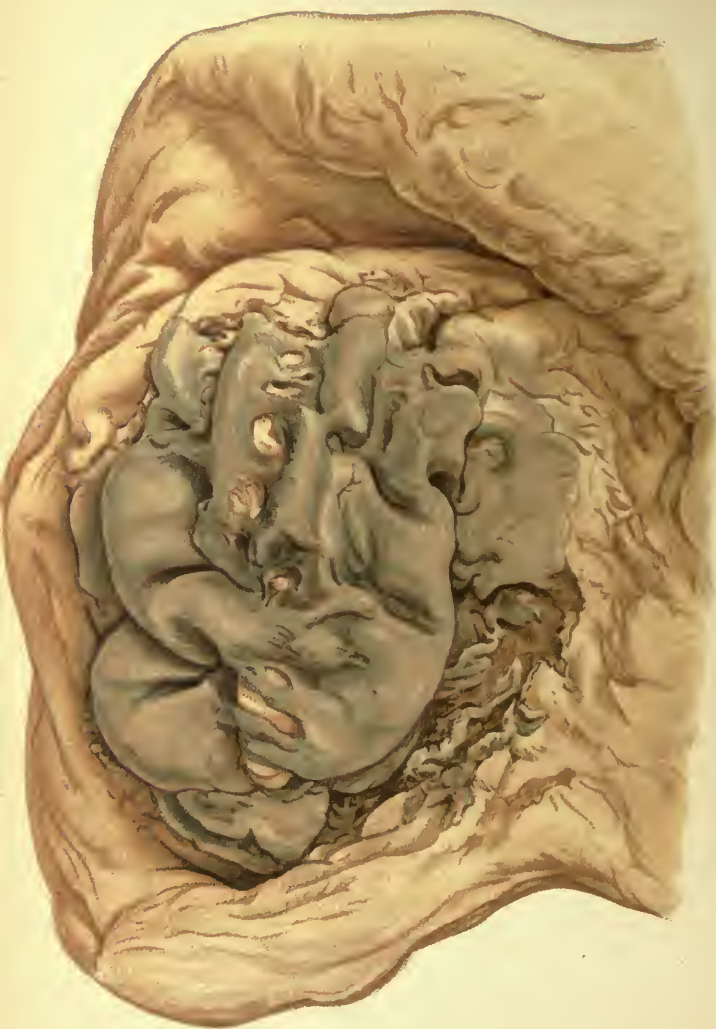The changes described may remain limited to the stomach, but not rarely may be followed a short distance in the intestine,—gradually diminishing in intensity.

Had the chemical been taken in the form of corrosive sublimate pastilles, both the stomach-contents and the escharotic gastric mucous membrane, especially the epithelial layer, would have presented a striking anilin-red discoloration (because of the coloring-matter added to the pastilles.—ED.).









## PLATE 42.

### Subacute Poisoning with Corrosive Sublimate.

J. J., a porter, aged 42 years, on the morning of April 30th, drank a solution of corrosive sublimate which had been prescribed for a skin affection from which he suffered. There soon ensued hematemesis and later hemorrhagic stools, both of which continued until his death, on the morning of May 4th.

At the necropsy the mucous membrane of the pharynx and the esophagus was found congested and injected, deprived of epithelium,—in the lower part with bilious imbibition and readily stripping.

The stomach is much dilated, livid, and has rather rigid walls. In the subserosa, in the region of the pylorus at the smaller curvature, there is an area of suffusion. In the stomach there was a quantity of bilious, hemorrhagic, mucous fluid. The gastric mucous membrane is, in general, swollen and edematous. It is of a grayish-greenish color, and pervaded by various extravasations of blood, which are situate closer together toward the fundus and are arranged in rows corresponding with the rugæ. In the fundus itself there is a fungiform projection of the mucous membrane, which has been converted into a rigid gray elevation almost the thickness of a finger. It is escharated throughout, of a grayish-white color, cloudy, and appears as though cooked. Beneath it the submucosa shows hemorrhagic infiltration and imbibition, as does also the swollen muscularis.

From various irregular, bean-sized areas of the escharated prominence the mucous membrane has been thrown off, thus exposing the somewhat ragged submucosa, the seat of fading hemorrhagic infiltrations. The edges of these areas are partly rounded, partly ragged, partly undermined. Similar but more extensive areas of desquamation and undermining are present along the periphery of a large escharated prominence the size of the palm of the hand. It is possible to introduce the probe a distance of 2 cm. beneath the eschar, which is evidently in process of desquamation. Suppuration is nowhere demonstrable. On the other hand, there is a delicate fibrinous exudate covering the peritoneum beneath. Over portions of the dysenteric intestine there are evidences of beginning peritonitis.

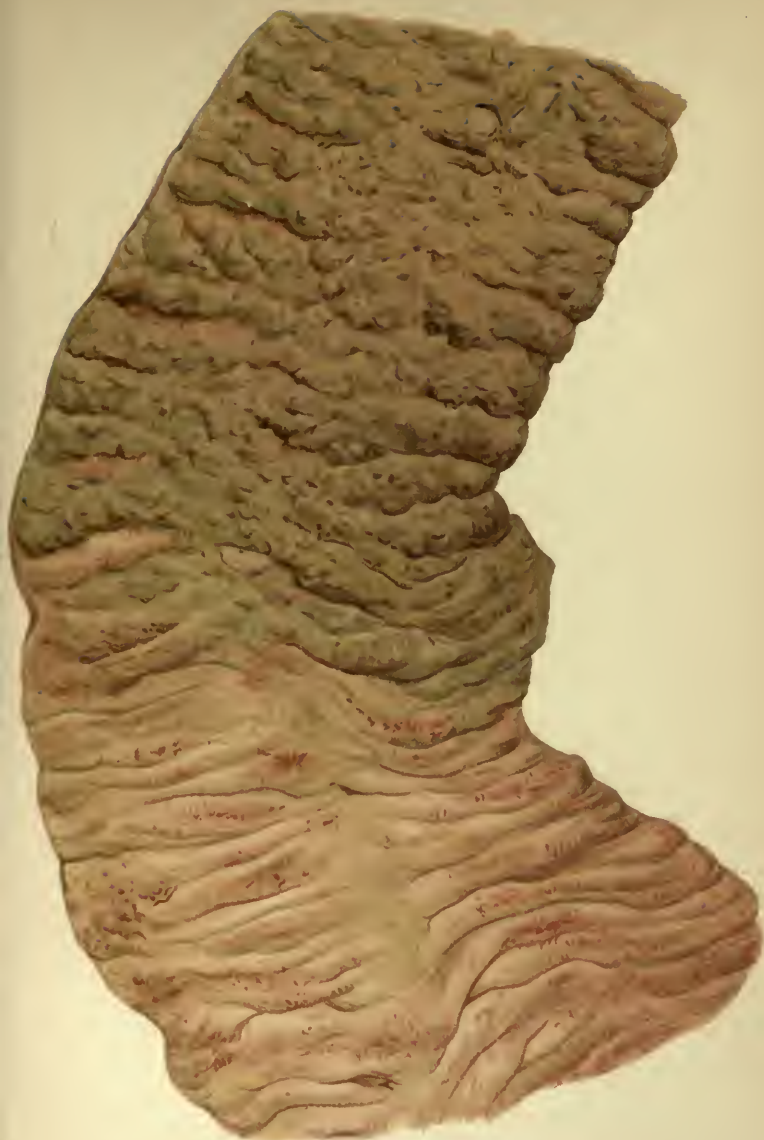In the lower portion of the small intestine, but especially in the large intestine, there are evidences of marked dysentery, that is, extensive diphtheric necrosis and ulceration of the crests of the rugæ.

## PLATE 43.

### **Corrosive-sublimate Dysentery.**

The preparation is from a woman, aged 25 years, who died of puerperal sepsis and diffuse suppuration of the pelvic connective tissue, six days after parturition. In the endeavor which was made outside the hospital to extract the child with forceps, a laceration, 6 cm. in length, of the left vaginal wall was produced. In the hospital the child was delivered with forceps, and the rent in the vagina was sutured. Before the instrumental delivery the vagina was irrigated with a 1:1000 corrosive-sublimate solution. By this procedure the fluid gaining an entrance through the laceration evidently invaded the pelvic connective tissue.

The mucous membrane of the large intestine is throughout markedly congested and flabby, at the crests of certain rugæ much injected, and pervaded by groups of minute ecchymoses. In the upper part, especially at the crests of the rugæ, there is a formation of discolored and malodorous pseudomembrane.









## PLATE 44.

### **Kidney from a Case of Corrosive-sublimate Poisoning.**

The illustration and the text are taken from Professor O. Bollinger's *Atlas der pathologischen Anatomie*, Part II. Plate 7. The case was that of a girl, aged 9 years, who three days prior to her death, with suicidal intent, swallowed a corrosive-sublimate pastil (1 gram). The greater part of the poison was promptly ejected. Complete anuria ensued. At the necropsy the gastric mucous membrane was unchanged; there was a moderate degree of catarrhal inflammation of the intestine; there were subpleural ecchymoses over both lungs and hypostatic pneumonia of the lower lobes.

The kidneys, on the other hand, revealed the appearances of toxic parenchymatous nephritis. The kidney is much increased in size, the capsule strips readily, the surface is smooth, the tissue soft and friable. The cortex is increased in size, of a pale grayish-white color, the normal appearances indistinct. The pyramids are of a dark, bluish-red color and slightly swollen. Microscopically: parenchymatous degeneration and partial necrosis of the epithelium, with calcareous infarction.

### FIGURE 186.

#### **Stricture of the Esophagus and Cicatrix of the Stomach, the result of Poisoning with Liquor Potassæ.**

A boy, aged 14 years, is said to have accidentally swallowed a solution of caustic potash three years ago, and since that time to have been troubled with cough and dysphagia. During the later months of his life he was treated in the hospital for an affection of the lungs. He died suddenly in the hospital.

The necropsy revealed pulmonary tuberculosis and bronchiectasis as the cause of death. To the right side of the stomach and along the greater curvature there is a flat, smooth cicatrix the size of a dollar, toward which the gastric rugæ converge. In the lower third of the esophagus there is a cicatricial stricture, 3 cm. in length. It has thickened and very dense walls, and permits the ready passage through its lumen of a probe, 2 mm. in diameter. Above the stricture the esophagus is dilated, and its mucous membrane is here and there the seat of superficial cicatricial striæ.

Fig. 186.

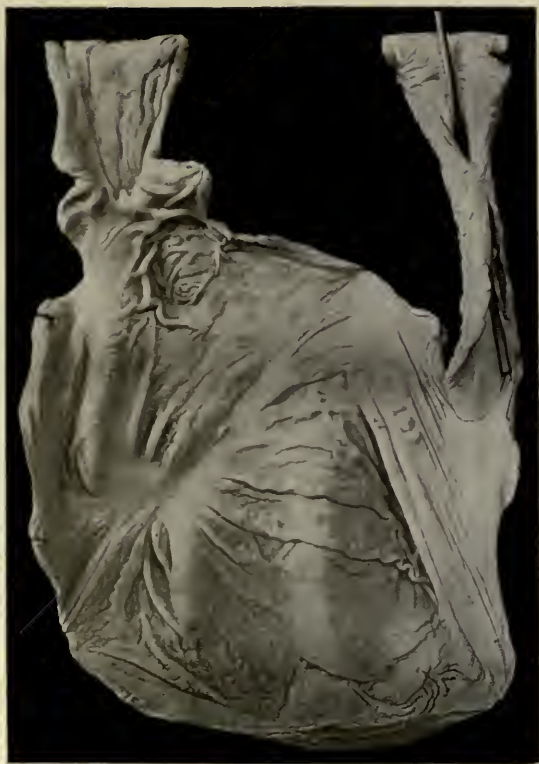





Fig. 187.

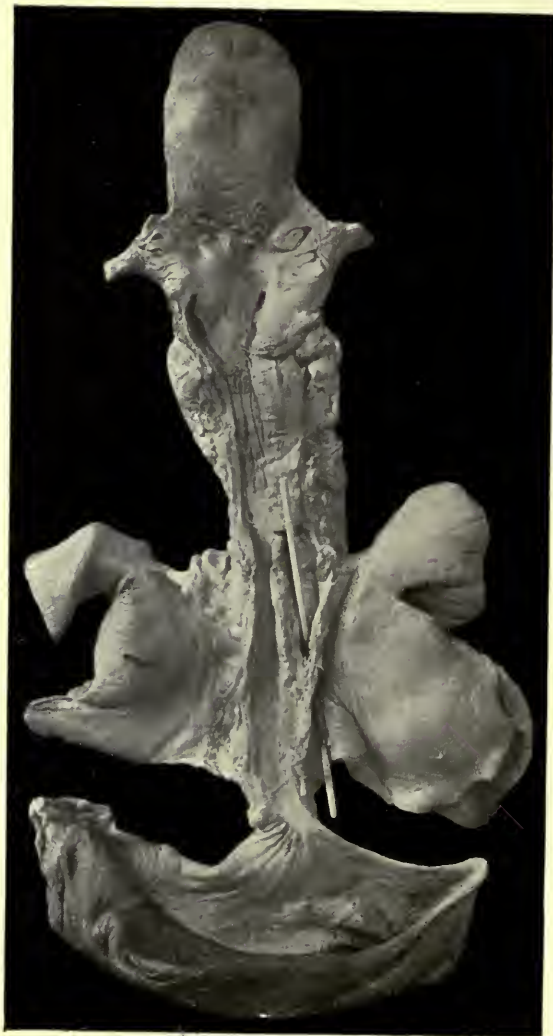

FIGURE 187.

**Stricture of the Esophagus following the Ingestion of Caustic Potash. Perforation of the Esophagus with an Esophageal Sound.**

A child, aged 1½ years, five weeks prior to its death, drank a solution of caustic potash which had been left on a bench by the child's mother. A physician was not summoned, but the child was given milk, oil, etc. Following the exhibition of these vomiting ceased, and the condition of the child is said to have improved. Latterly, however, the ingestion of food became more and more difficult, so that finally fluids only could be swallowed. At this time the child was taken by its parents to a hospital, when ulcers of the tongue and a stricture of the esophagus were recognized. The lumen of the latter was so narrow that only after repeated attempts could a sound be passed.

Immediately after the probing the child became restless, sank rapidly, and died the following day with manifestations of suffocation.

The necropsy revealed a much emaciated child. In the mouth, aside from two small superficial ulcers on the tongue, there were no noteworthy lesions. The right side of the diaphragm was depressed dome-like toward the abdominal cavity and, in addition, was relaxed. The right pleural cavity contained about 200 grams of a yellowish, whey-like, turbid fluid, which was found to consist mostly of milk. The lung was compressed and thickened; the pleural covering was cloudy. The left lung was crepitant. The stomach showed no marked alterations. Its mucous membrane was pale; there were no cicatrices.

The esophagus is somewhat dilated in its upper part. Its mucous membrane is pale, its epithelium thickened, and in the lower part of this area is pervaded with superficial cicatricial striæ. From this region downward the esophagus is rather uniformly cicatricially thickened and diminished in caliber, so that only the blunt extremity of a small pair of scissors can be introduced therein. At the commencement of this area of contraction there is a transverse laceration of the mucous membrane of the right wall of the esophagus, 1 cm. in length. It has rather sharp edges, which are congested but not suffused. It leads into a canal 4 cm. in length, which is directed anteriorly, and which has the thickness of a lead-pencil. It courses beneath the mucous membrane in the submucosa, in the direction of the esophagus downward, terminating in a bean-sized, ragged, discolored aperture, which opens into the right pleural cavity, beneath the hilus of the right lung.

The opinion was expressed :

1. That the child had suffered a cauterization of its esophagus some considerable time prior to its death, and that there was no evidence

opposed to the view that this may have been produced by accidental drinking of a solution of caustic potash.

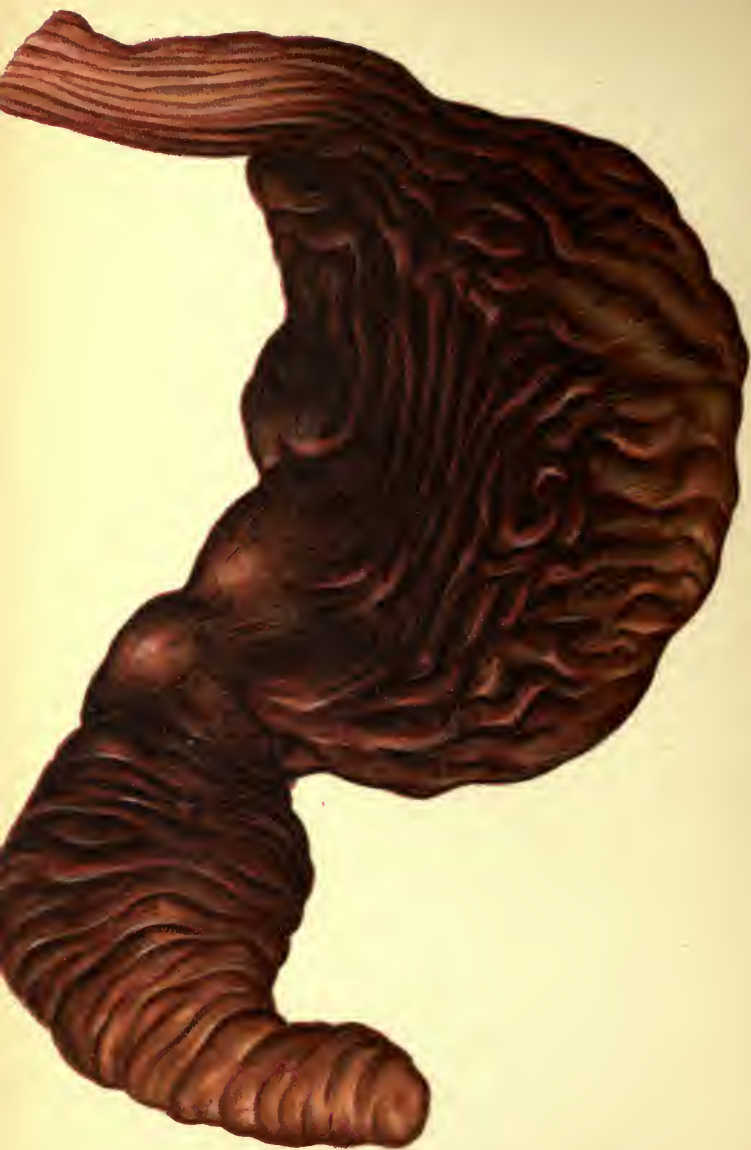2. As a consequence of this cauterization there developed a very marked cicatricial diminution in the caliber of the esophagus.

3. In an attempt to relieve this stenosis by the introduction of a sound the esophagus was perforated. Directly above the commencement of the stricture the probe penetrated the mucous membrane and finally entered the right pleural cavity. As a result of this perforation, the fluid which was subsequently swallowed or otherwise introduced found its way into the right pleural cavity and thus brought about the death of the child by suffocation.

4. It cannot be asserted, in the present case, that the perforation of the esophagus was the result of culpable negligence or malpractice. On the one hand, the stenosis was excessive and the introduction of an instrument through the stricture would have been very difficult even for one experienced, and was absolutely necessary; and, on the other hand, the dilatation of the esophagus above the stricture and the softening of its wall consequent upon the stagnation of food may have favored the rupture.

5. It must be declared that the child was certainly neglected, and that this neglect, especially in view of the fact that it was not given the benefit of medicinal treatment until the end of five weeks, contributed to the fatal termination. This is evident because, had the child been properly treated in time, the stenosis of the esophagus would not have attained such a high grade as was really the fact.





## PLATE 45.

### Potassium-cyanid Poisoning.

By the combination of cyanogen with potassium hydroxid to form potassium cyanid the latter loses none of its well-known qualities. It is in consequence of this that potassium cyanid retains the alkaline taste and markedly alkaline reaction of caustic potash; and that, like the latter, it gives rise to solution of albuminous bodies, causes the tissues to swell and to become cleared, and not only produces disintegration of the blood, but also solution of the hemoglobin, and as a consequence hemorrhagic imbibition of the swollen structures. There is, however, this difference between the two: the solution of the blood produced by potassium cyanid, does not present, as does that which follows the action of caustic potash, a brown or brownish-black color, but a striking red or brownish-red color. This is the result of the specific action of cyanogen, and depends upon the formation of cyanohe-matin.

As the result of this action, the appearance of the stomach at the necropsy, in a case of typical potassium-cyanid poisoning, is very characteristic and remarkable, as shown in the accompanying illustration.

We find the stomach generally contracted, with walls apparently thickened to the touch. As a rule, the organ contains a large quantity of soapy, slimy, hemorrhagic, rather tenacious mucus of alkaline reaction. The mucous membrane throughout, but especially in the dependent portions, is of a diffuse blood-red or brownish-red color, markedly swollen, at the crests of the rugæ transparent, and throughout soapy and slimy to the touch. These alterations may affect the entire thickness of the mucous membrane and even invade the submucosa. At times they may also be followed into the duodenum, less frequently beyond it, and sometimes also into the esophagus and the pharynx (*vide* Plate 46).

The first of these alterations, and that which certainly occurs during life, is the marked hyperemia of the gastric mucous membrane; and this is probably associated with the formation of ecchymoses. The other lesions, especially the solution of the hemoglobin, and the imbibition of this by the inner wall of the stomach, as also the swelling of the latter, because of their nature, do not develop until after the death of the individual. They are the consequence of the long-continued action of the solution of the potassium cyanid on the hyperemic stomach. They are therefore not found at the necropsy performed immediately after death of animals experimentally killed by the poison. One may also satisfy himself that this diffuse hyperemia and swelling likewise ensue, if a hyperemic stomach be filled with a solution of potassium cyanid and examined the following day.

On the other hand, from what has been said, it follows that the above-mentioned remarkable and characteristic lesions develop only when undecomposed potassium cyanid exerts its action. The changes may be wanting when, as may readily occur, the chemical has been decomposed either by the vehicle or by the contents of the stomach.

The affinity of cyanogen for potassium hydroxid in combination with it is so slight that even the weakest acids, as, for instance, carbonic acid, tartaric acid, acetic acid, disturb it and cause the liberation of cyanogen, with the formation of a salt by the combination of the potassium hydroxid with the acid employed. This resultant salt does not possess the above-mentioned peculiarities of the alkali. Similar decomposition will result if the poison be taken in an acid vehicle, or if at the time of its ingestion the stomach contain acid contents. The development of the above-described lesions, therefore, will be the more incomplete the greater the decomposition.

Under such circumstances, despite the fact that potassium cyanid was taken, the case becomes one of hydrocyanic-acid poisoning. As is well known, this gives rise to no especial organic changes, and is only to be detected by the peculiar odor and the chemical investigation.

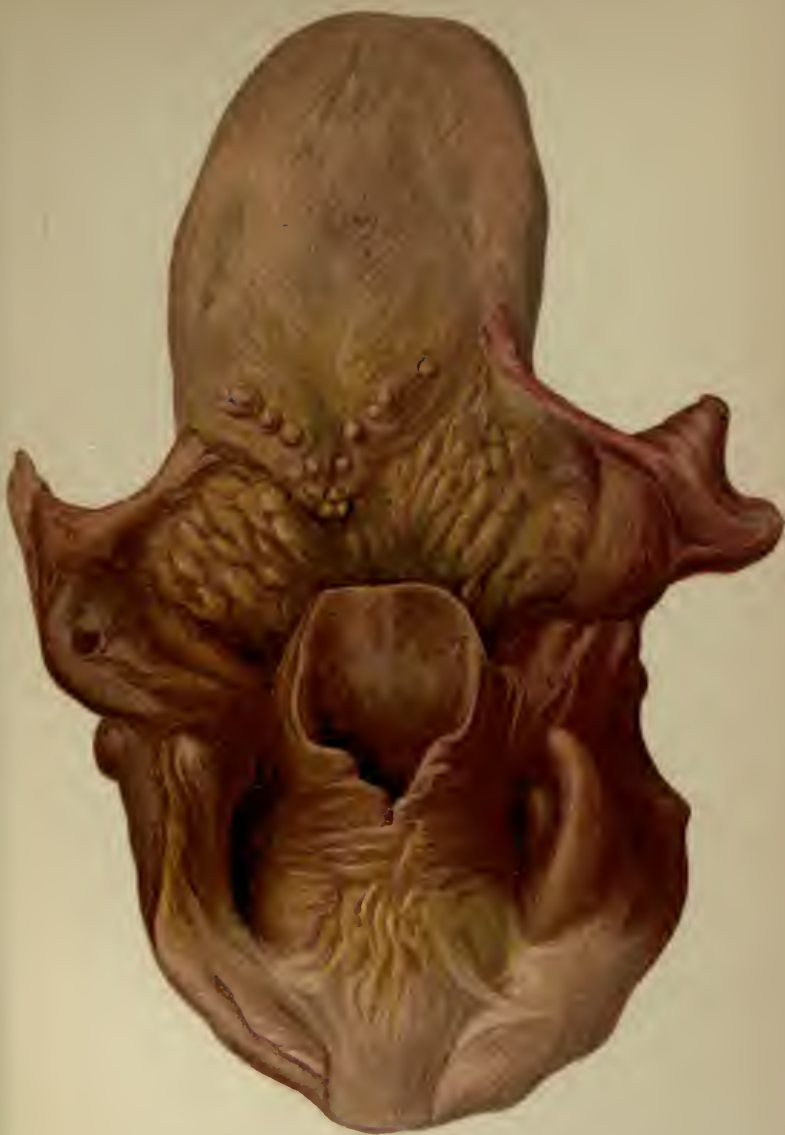---

## PLATE 46.

### **Fauces, Pharynx, and Entrance to the Larynx from a Case of Potassium-cyanid Poisoning.**

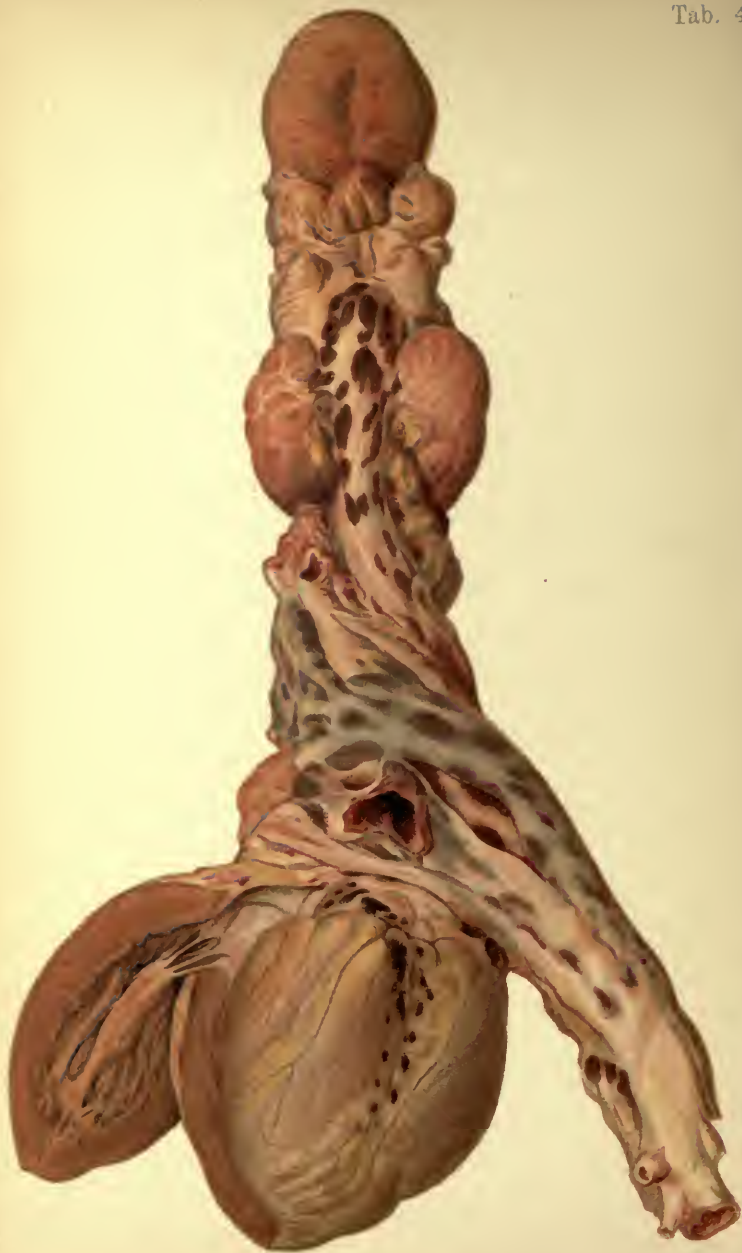The mucous membrane throughout is uniformly suffused with blood, with here and there a yellowish tint, probably dependent upon bile; it is markedly swollen and relaxed, and was covered with a clear, soapy, slimy mucus, markedly acid in reaction.

This lesion is common in cases of typical poisoning with potassium cyanid; that is, in those in which the poison has not been decomposed by an acid. Its occurrence is accounted for by the fact that through vomiting or retching a portion of the very alkaline contents of the stomach reaches the pharynx and may even extend into the lungs. In these situations it produces postmortem changes similar to those which develop in the gastric mucous membrane in cases of typical potassium-cyanid poisoning.









## PLATE 47.

### Subacute Phosphorus-poisoning.

A woman, aged 46 years, the wife of a shoemaker, had latterly exhibited indications of mental aberration; she cried considerably, and manifested an exaggerated piety. She had also repeatedly said that she desired to die and that she would take her life. On February 3d, appearing indisposed and being questioned, she asserted that, although she was well, "one could not foretell what might happen within an hour." At noon she ordered her repast. Into this when it was brought she introduced some substance, but denied that fact to her husband. Since then she has been ill and is said to have repeatedly vomited. On February 5th, a physician being summoned, found the woman much emaciated, and examining her lungs he detected the presence of râles. He advised the removal of the patient to a hospital. Here examination revealed jaundice, muscular and cardiac weakness, dyspnea and râles, vomiting of coffee-colored material, and constipation. Expression was given to a supposition of phosphorus-poisoning, and although the woman denied that she had taken anything unusual, phosphorus was demonstrated, not in the vomited material, it is true, but in the stools which were passed after the injection of enemata. With increasing collapse, the woman died February 7th.

The necropsy, performed February 10th, revealed icterus, and, after making an incision along the vertebral column, infiltration of the cellular tissues with icteric serum. In addition there were numerous ecchymoses upward the size of a dollar in the subcutaneous connective tissue and intermuscular septa. About the nose and the mouth there was some coffee-colored fluid, acid in reaction; similar fluid also in the stomach and in the upper part of the small intestine. The mucous membrane of the organs of deglutition were without especial alterations. That of the stomach was cloudy, swollen, and covered with numerous coffee-colored flocculi. The mucous membrane of the upper part of the small intestine presented similar changes; that of the lower part and of the large intestine was unaltered. In the large intestine there was a considerable quantity of clay-colored fecal masses.

The musculature of the trunk and the extremities was in great part softened and pale. Microscopical examination revealed it to be in part granular, in part the seat of fatty degeneration. In the subcutaneous connective tissue and intermuscular septa, especially in the dependent portions, there were numerous extravasations of blood the size of a bean and larger.

The dura mater contained a considerable quantity of blood and was icteric. On its inner surface there was a delicate, vascularized pseudo-membrane. It was pervaded by numerous recent blood-extravasations

and was readily detachable. The inner meninges on the convexity of the brain were thickened and infiltrated with yellowish serum. The brain was dense, and its parietal convolutions were diminished in size.

The left lung was free, the right partly adherent. Both revealed ecchymoses upward the size of a bean about the hilus and beneath the posterior pleural covering. On section the lungs contained a considerable quantity of blood, and they crepitated throughout; there was considerable mucus in the bronchi.

In the anterior, but especially in the posterior mediastinal space, there were numerous extravasations of blood upward the size of a bean, in great part confluent.

The heart was of ordinary size, softened externally, and on section clay colored. Beneath the epicardium and the adventitia of the larger vessels there were numerous bean-sized ecchymoses. The valves of the heart and the intima of the aorta were normal. The cardiac muscle was in a state of fatty degeneration and was readily lacerated. Beneath the left endocardium there were also lentil-sized ecchymoses.

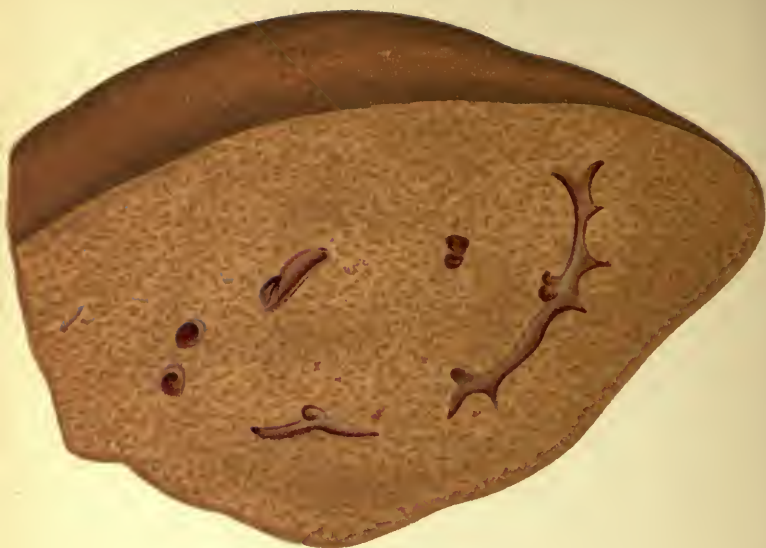The liver and the kidneys were enlarged and showed uniform fatty degeneration (see next plate).

In the omentum and the mesentery, especially in the posterior part of the latter, there were numerous ecchymoses the size of a half-dollar.

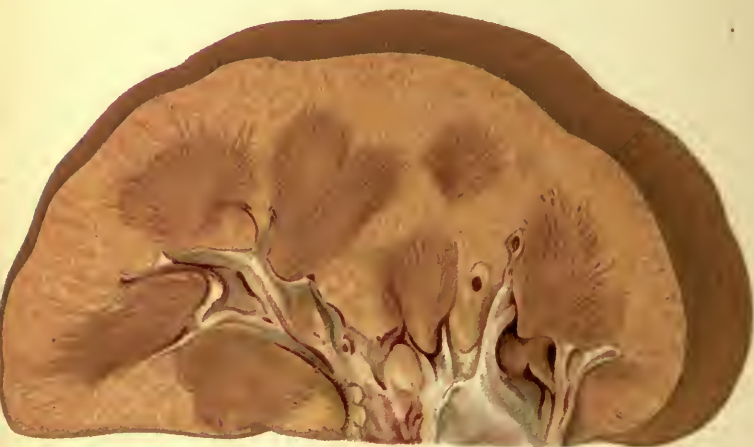
The postmortem lesions above described (jaundice, acute fatty degeneration of the organs, parenchymatous degeneration of the mucous membrane of the stomach with coffee-colored gastric contents, and extensive ecchymoses in various areolar connective tissues, especially in the dependent portions of the body) are characteristic of subacute phosphorus-poisoning—that is, of phosphorus-poisoning leading to death several days after the poison has been taken. By themselves alone they permit the diagnosis of such a condition even when, as in the present case, after death no phosphorus can be detected in the intestinal contents.

The poison was evidently taken in the form of match-heads on the third of February. The duration of the illness was thus four days. There was no question that the case was one of suicide, and the supposition that the deceased was insane found also its confirmation in the discovery of a pachymeningitis vasculosa and indications of cerebral atrophy.





a



b

## PLATE 48.

### **Fig. a.—Liver from a Case of Subacute Phosphorus-poisoning.**

The liver is enlarged, externally somewhat doughy to the touch, almost uniformly fatty-yellow with injected vessels. On section it is also fatty-yellow; the acini are enlarged, and in their center there are discernible the intra-acinous vessels and vestiges of still persistent brownish liver-substance.

Under the microscope the liver-cells were enlarged, globular, and filled with larger and smaller fat-droplets.

---

### **Fig. b.—Kidney from a Case of Subacute Phosphorus-poisoning.**

The kidney is enlarged and pale yellowish. The cortical substance is visibly increased in breadth, almost uniformly fatty-yellow, here and there the injected interstitial vessels and glomeruli are discernible. The pyramids are pale yellow with reddish striations and are likewise increased in width. In the connective tissue of the pelvis of the kidney there are numerous fading ecchymoses.

Microscopically there was found a high grade of acute fatty degeneration of the entire epithelium of the organ.

## PLATE 49.

### **Stomach from a Case of Acute Arsenical Poisoning. Murder by Poison.**

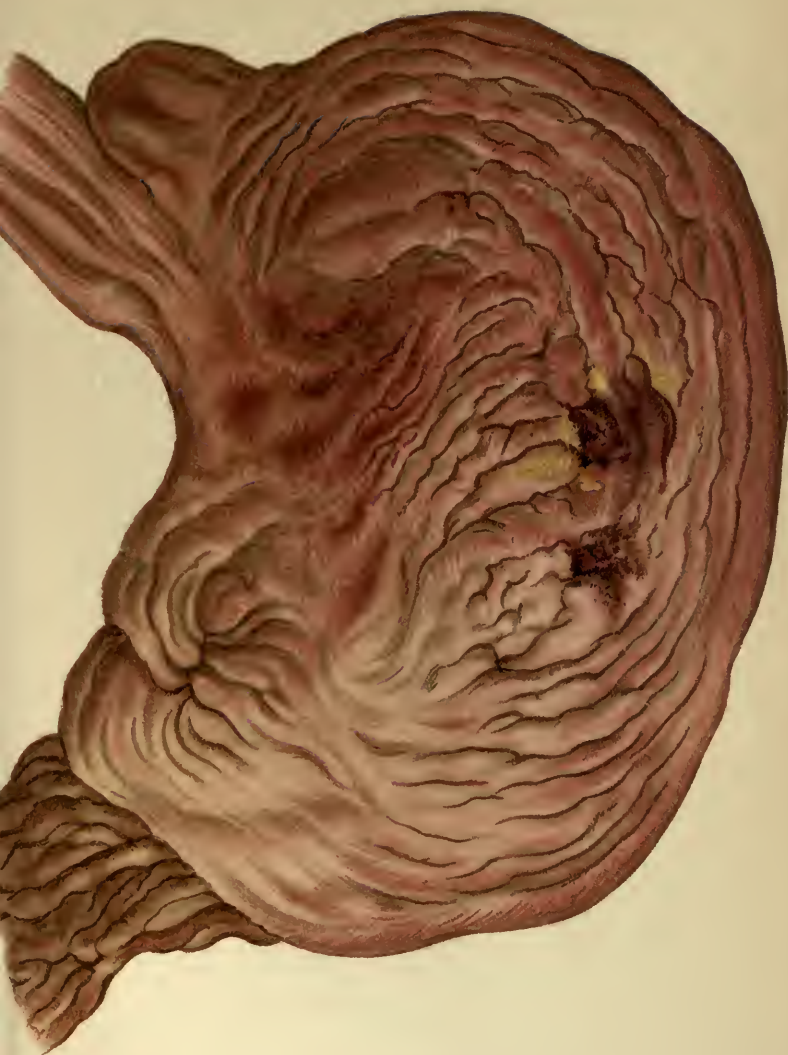On June 5, 1896, for the purpose of determining the cause of death, a medicolegal necropsy was performed upon the body of Marie S., aged 29 years, the wife of a timber-merchant. According to information furnished by the police, the deceased and her two children are said to have been taken ill, on May 26th, after partaking of some sausage. Whereas the children, after vomiting and suffering with headache, rapidly recovered, the illness of the woman continued with vomiting and diarrhea, and eventuated in her death, on June 4th.

Systematic medical attention was not afforded her, and there was therefore no history of her illness.

The necropsy revealed slight but distinct jaundice and hypostatic congestion of the lungs, but no especial changes in the throat or the esophagus. There were moderate hypercemia and swelling of the mucous membrane of the larynx and the trachea. The heart was flabby and dilated, the musculature of a yellowish-brown color, and friable. Microscopically the normal striation was absent, the muscular substance showing marked cloudy swelling. The liver and the kidney likewise showed a high grade of parenchymatous degeneration.

The stomach was moderately distended, flabby, and markedly injected along the curvatures; otherwise there were no noteworthy changes externally. It contained about 180 c.c. of a watery, turbid, slightly hemorrhagic, unctuous fluid without especial odor and without any particular contaminations. The inner wall of the stomach, as shown in the accompanying illustration, is throughout markedly swollen, softened, and congested. The congestion on closer investigation is found to consist of injection of the minutest vessels, especially of those situate at the crests of the rugæ, where it is in great part combined with closely aggregated punctiform ecchymoses. Especially noticeable are both the congestion and the swelling of the fundus of the stomach, of the posterior wall, and about the middle of the greater curvature. In the latter situation there are circumscribed areas, upward the size of a bean, composed of compact and in great part confluent ecchymoses, which have been deprived of their epithelium. Covering these areas and the immediate vicinity there is a fine, soft, bright-yellowish substance, which is unctuous to the touch, and which on microscopic examination reveals neither sand-like nor crystalline particles. Nor were such particles demonstrable either in the gastric contents nor its sediment after precipitation in a conical glass.

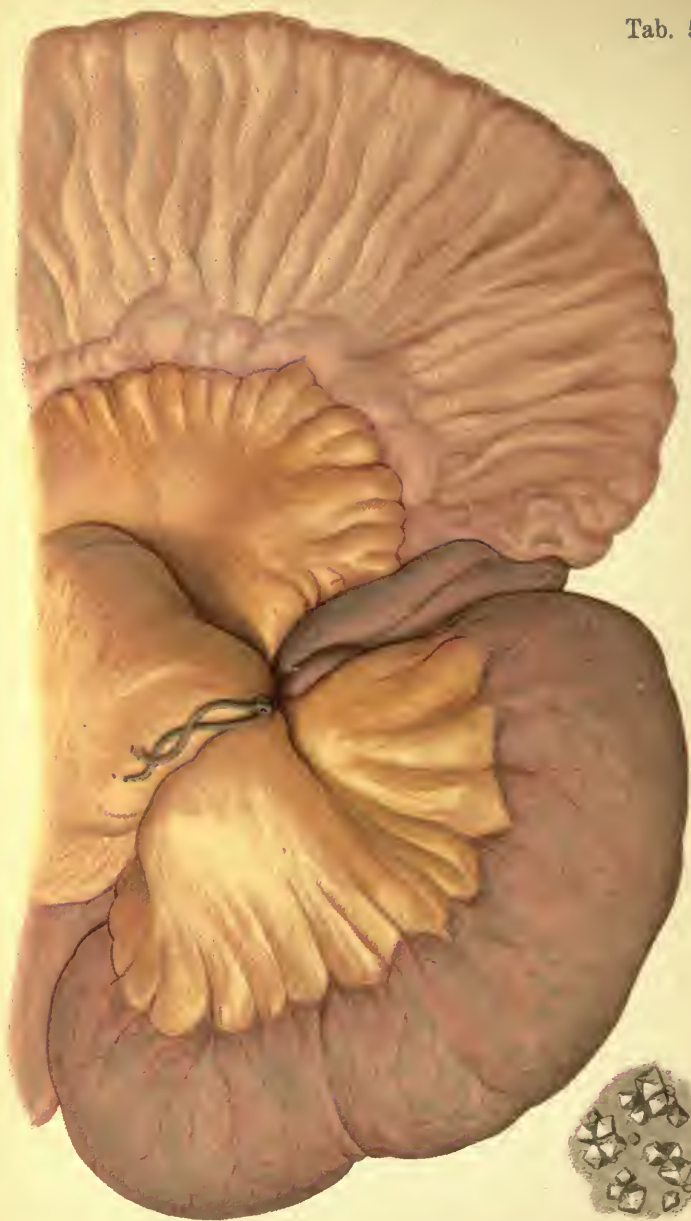Not less remarkable were the lesions on and in the intestines, especially the small intestine, represented in Plate 50. (See next Plate.)







Tab. 50.



## PLATE 50.

### **Small Intestine from a Case of Acute Arsenical Poisoning.**

The small intestine appears very flabby and contains throughout its entire length a large quantity of watery, turbid, whey-like contents, resembling rice-water. The wall of the intestine appears—as is evident from the constricted portion of the intestine in the illustration—externally smooth, but slightly cloudy, and of a very pale violet color. This color is in part dependent upon a fine and compact injection of the intestinal, especially the subperitoneal, vessels, and in part upon a serous infiltration of the coats of the bowel. After opening the intestine the mucous membrane is also found to be of a pale-violet color and to be finely injected. Its epithelium is desquamating, and throughout it is flabby, edematous, and somewhat cloudy. In the large intestine there is a moderate amount of seromucous contents; the mucous membrane is likewise flabby. The intestinal glands are swollen, but not infiltrated.

Of the remaining lesions, there are still to mention the tar-like character (inspissation) of the blood, the dryness of the tissues, and the absence of urine in the bladder.

The anatomical lesions, therefore, are those of an acute diffuse gastro-enteritis—such form as may occur after so-called sausage-poisoning or in arsenical poisoning, in cholera asiatica and cholera nostras. A positive distinction in one or the other direction could only be made by bacteriological and chemical investigation. But bearing in mind the rather characteristic necropsy-findings, the opinion was expressed that the case might be one of arsenical poisoning.

As a matter of fact, bacteriological examination of the reserved portions of the intestine proved negative, the chemical investigation, on the other hand, revealing a “considerable quantity” of arsenic. This, although no quantitative estimation was made, permits of no doubt that the case was one of arsenical poisoning. And this view is further confirmed because of the fact that, although the patient was ill seven days and during this time vomited considerably and had marked diarrhea, a “considerable quantity” of arsenic was nevertheless detected.

Imbedded in certain of the flakes from the sediment of the rice-water contents of the intestine, there were also found upon microscopic examination white, octahedral crystals with blunt edges (smaller illustration, Plate 50). These revealed the microscopic appearances of crystals of arsenic and upon chemical examination were found to be such.

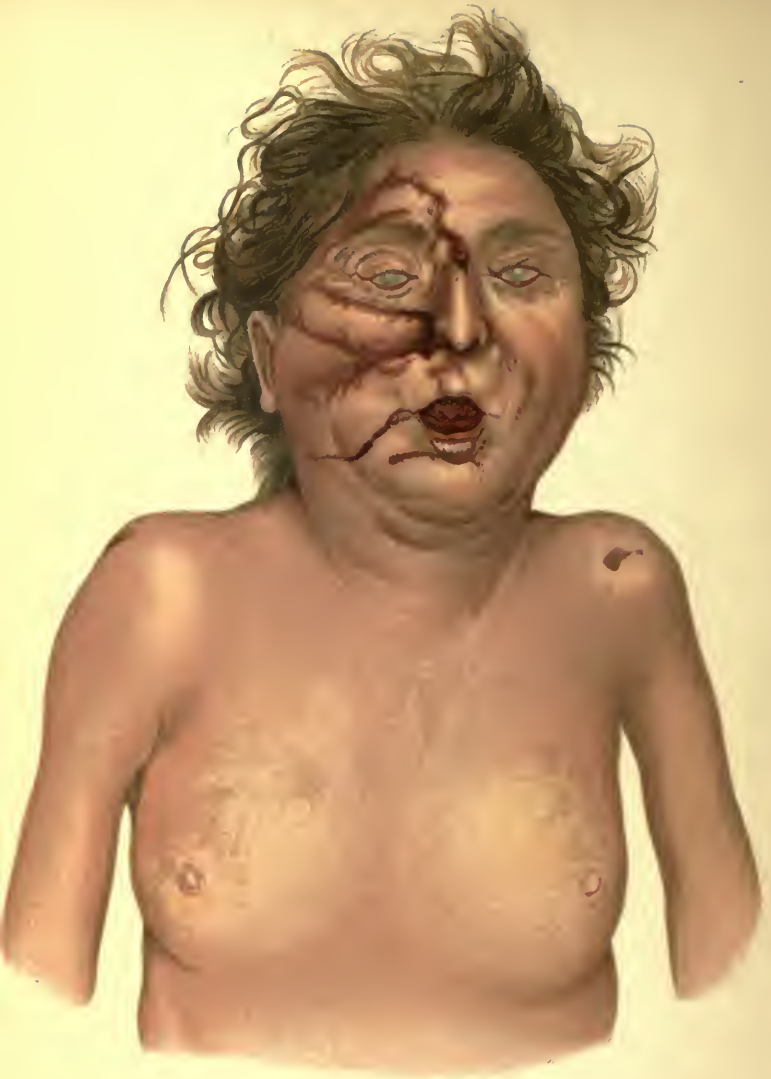Upon further inquiry it was elicited that the assertion that the woman and her two children became ill on May 26th, after partaking of sausage, originated with the husband, and was not based upon truth; that the sausage had been partaken of on the day previous and without

evil consequences; that the aforementioned persons became ill on the following day after the midday meal; that the man had been married thrice; that both the former wives had died suddenly and under suspicious circumstances; and that he was again engaged in courtship with a relative whom he had already promised to marry after the death of his wife. In addition, the police inspectors found, hidden beneath a stone in the residence of the accused, a small package which upon examination was found to contain arsenic. Finally the husband acknowledged that on May 27th he had sprinkled arsenic upon some meat, that as his wife and children subsequently demanded some, they were given of it to eat, and that he had been unable to prevent their partaking of it.

The husband subsequently withdrew this confession. In the exhumed body of his second wife, who died three years previously, arsenic was discovered. But to this one must not attach too much importance, as the earth of the cemetery was found to contain a large quantity of arsenic.

The husband was condemned to death because of murder by poison.





## PLATE 51.

### Carbonic-oxid Poisoning (Charcoal-fumes).

On the morning of November 6th, the woman the subject of the present illustration, clothed only in a chemise and petticoat, was found dead before her bed, lying with her face downward. In her small room there was a basin containing half-consumed charcoal, by burning which she had been accustomed to warm herself.

At first view the peculiar color of the body is remarkable. As a consequence of the abdominal posture, in which the body had doubtless remained for a considerable period of time, this color has developed more especially on its anterior surface. But certain portions of it, as, for instance, various prominent areas of the face, as also the anterior surface of the shoulders and the mammæ, which had been in direct contact with the floor and therefore subject to greater pressure, are distinguished from the surrounding areas by their pale color.

The skin is bright red in color and has a tinge of carmine, reminding one somewhat of the color of rouge. In addition the visible mucous membranes, especially the conjunctivæ and the lips, are of a remarkably bright-red color. In order to show this better in the illustration, they are somewhat everted. Similarly to the skin, the internal organs are bright red in color, particularly those which normally are of a lighter hue. The blood within the vessels is cherry-red in color and fluid. This is especially noticeable in the meninges and the brain. The former are bright red and injected. Both the white and the gray matter of the brain are manifestly reddened; on section blood exudes from the vessels in the form of bright-red droplets.

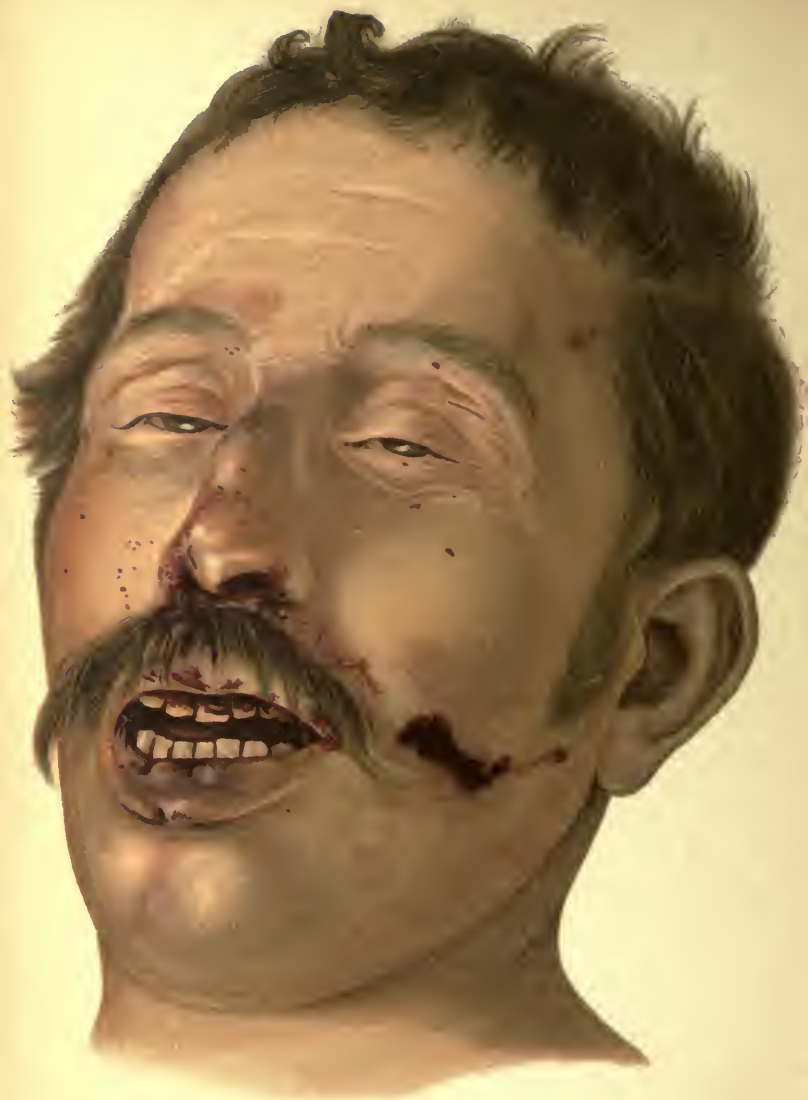These lesions, especially when considered in association with the other circumstances of the case, rendered clear the diagnosis of carbonic-oxid poisoning; and this diagnosis was confirmed by an examination of the blood. Spectroscopic examination of the blood diluted with water revealed indeed two absorption-lines in the green part of the spectrum, and these were not essentially different from those of oxy-hemoglobin. They differed from the latter, however, in that they did not, as do the latter, unite to form one after the addition of ammonium sulphid; they persist, as is the rule with carbonic-oxid-hemoglobin. In addition, when a few drops of the blood were added to a few drops of sodium hydrate in a white dish the former retained its beautiful red color. Ordinary blood, after such addition, loses its red color and becomes greenish.

That the poisoning was the result of charcoal-fumes, and was not due to illuminating-gas, is further indicated by the half-consumed charcoal found in the room, and by the absence of the odor of illuminating-gas.

On the bridge of the nose near its root there is an irregular slit-like laceration of the skin,  $2\frac{1}{2}$  cm. in length. It has contused edges and an irregular base. The latter is suffused with bright-red blood, although there is no deeper injury. From this, as also from the mouth and nose, blood had exuded and flown to the right, where it became dried in the form of partly branching streaks. This is evidently a so-called agonal injury, which has been caused by falling upon the face at the moment of the supervention of unconsciousness.







## PLATE 52.

### Agonal Injuries of the Face.

This plate illustrates an instructive instance of so-called agonal injuries; that is, those produced by a fall the result of other causes leading to death. These injuries possess a forensic importance, because of the fact that they may be looked upon as the consequences of traumata sustained during life at the hands of others, and because they may even be considered the real cause of death.

In the present case the appearances of the face are in reality such as would incline one to the belief that various traumata had been sustained during life; in other words, that the deceased had met with a violent death. This view would be considered especially likely in the case of an unknown individual or of one dying under suspicious circumstances.

One finds about the nose and the mouth a considerable quantity of coagulated, partly recent, partly dried blood, and, in addition, the region of the face about the mouth and nose seems as though sprinkled with blood. The bridge of the nose is swollen; toward the nasal bones it is prominent, of a bluish-red color, doughy to the touch, and on section is found to be markedly suffused with freshly coagulated blood. Beneath the suffusion the anterior ends of the nasal bones are splintered. On the left cheek there is an irregular, dried, bluish-red abrasion of the skin rather larger than a bean. On section of this area an extravasation of coagulated blood, almost as large as a dollar, is detected in the subcutaneous tissue. The lower lip is swollen and suffused. At about its center, corresponding in position with the incisor teeth, there is on the external margin of the lip one, and on its inner surface two, irregular lacerations of the mucous membrane, about  $\frac{1}{2}$  cm. in length. They have contused edges and irregular hemorrhagic bases. Finally, to the outer side of the left frontal protuberance there are two contused, slightly suffused areas about the size of beans.

Despite the rather remarkable nature of these lesions, they are but accidental injuries resulting from a fall engendered by a "natural cause" of death.

The man, a janitor, aged 53 years, at midday on a crowded thoroughfare, suddenly fell to the ground. As witnesses assert, he struck the ground with his face and died in a few moments. The anamnesis disclosed the facts that he had been ill for three years, and that he had suffered three strokes of apoplexy with consequent right-sided hemiplegia.

The necropsy revealed a recent apoplectic focus, the size of a goose-egg, destroying the right lenticular nucleus and the internal capsule, and invading the lateral ventricle. There was also a large apoplectic cicatrix in the left lenticular nucleus. It affected almost the entire length of the latter, and at its center was the seat of a transverse enlargement.

In addition, there were found arteriosclerosis, chronic nephritis, and a well-marked hypertrophy of the left ventricle of the heart.

Had the man been overtaken by sudden death while standing on a height, even more serious injuries might have resulted from the fall; as, for instance, fractures of the skull. In such cases the more severe the secondary or agonal injuries and the more they overshadow the real cause of death, the more likely are they to be taken for the latter. This possibility is further increased by the fact that such agonal injuries are, as a rule, associated with distinct suffusion and other manifestations of vital activity, and, therefore, simulate injuries occurring during life.

## PLATE 53.

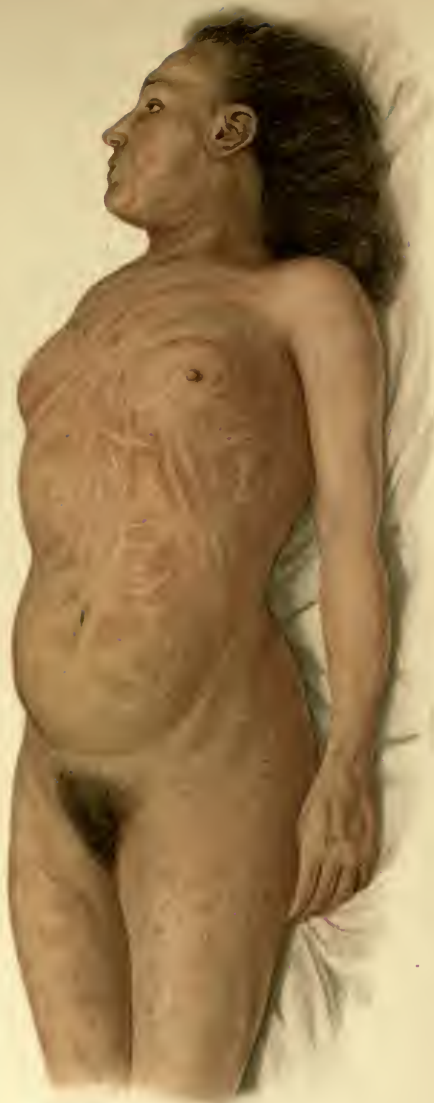### **Abnormal Situation of Postmortem Lividity as a Result of the Abdominal Position of the Body.**

The body of a young woman, clothed, rigid, and in the abdominal position, was found in the room of the deceased. The woman resided alone, and had not been seen during the preceding twenty-four hours. She is said to have appeared ill and to have complained of gastric pain during the two weeks prior to her death. She had, nevertheless, been able to repeatedly leave her room.

The body attracted attention because of the violet color of its anterior surface; the posterior surface revealed the ordinary cadaveric pallor. The violet color was, in general, diffuse. All over the chest, however, and on the upper part of the abdomen, and to a less degree on the anterior surface of the thighs, it was pervaded by numerous, longer and shorter, pale striations. These crossed each other frequently and irregularly, were rather sharply limited, and in marked contrast to the adjoining livid areas. They exhibited no other alterations of the skin. The livid areas were darkest on the anterior surface of the body. Laterally and posteriorly they decreased in intensity until they approached the cadaveric pallor of the posterior surface of the body. This is not evident in the illustration because of the shadow, which is depicted too intensely. These livid cutaneous areas were pervaded by various, scarcely discernible punctiform ecchymoses, which diminished in intensity from the thorax and abdomen toward the lateral portions of the body. The face, especially the left side, was also of a dirty violet color. The conjunctivæ were markedly injected, but without ecchymoses.

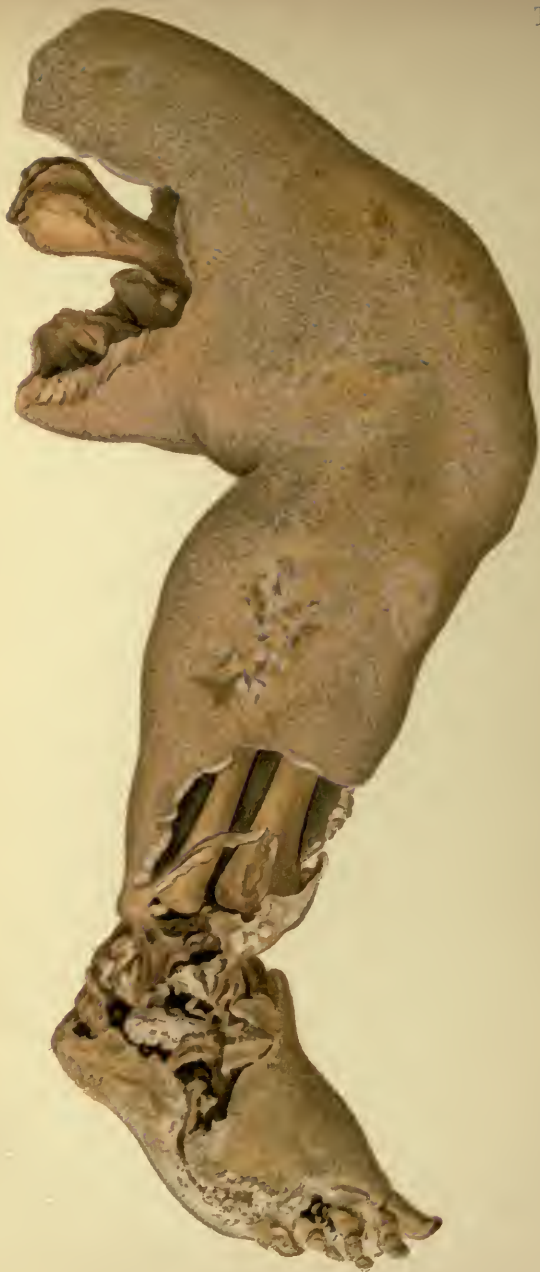The case is, therefore, an instance of abnormal distribution of the postmortem lividity. This has arisen in consequence of the body having remained for a certain time (twelve to twenty hours) in the abdominal position (abdomen downward). This fact could have been recognized from the above-mentioned findings, even had there been no positive evidence in support of it. The pale and intercrossing streaks have been produced by the folds of the clothing, and suggest, to a certain extent, the articles of apparel worn at the time of death.

The necropsy revealed a circumscribed pneumonia of the right upper lobe, acute splenic tumor, marked hyperplasia of the mesenteric glands and Peyer's plaques, with beginning necrosis of the latter, parenchymatous degeneration (cloudy swelling) of the parenchymatous organs—therefore typhoid fever—as the cause of death. According to the anatomical lesions, the disease was in about the second week of its course, and clinically was that form known as ambulatory typhoid fever.









## PLATE 54.

### **Lower Extremity of a Newly Born Child which Remained Several Months in Running Water; Formation of Adipocere.**

The external conformation of the extremity is preserved. On closer inspection, however, it is seen that this is dependent upon the subcutaneous fat, which has been converted into a calcareous, friable mass, and which presents itself cuirass-like or as a rigid tube. This contains but the denuded, freely movable bones and vestiges of tendons and ligaments; the musculature is wanting, and has evidently been removed through maceration.

The external surface of this hollow tube appears slightly irregular. On more careful examination the cutaneous covering is discovered to be entirely absent. The fine irregularities correspond with the exposed and external layer of the subcutaneous adipose tissue. The external surface of this mass is dirty yellowish-white in color; the surface when broken is pure white. Microscopical and chemical examination shows it to consist of crystalline fatty acids; they float on water and they liquefy upon being heated.

This substance, designated adipocere, is, therefore, nothing but the original fat of the parts, which, becoming rancid, decomposed into glycerin and fatty acids. Of the decomposition-products, the glycerin and the fluid fatty acids have been washed away, while the solid fatty acids remain.

PLATE 55.

**Portion of the Abdominal Skin of a Body which had been  
in Water Two or Three Months, and which Demon-  
strates the Formation of so-called Adipocere.**

One notices distinctly in the upper, especially in the upper left-hand section of the illustration, portions of the macerated cutis still preserved. To the left above, only the deeper layers of the cutis are present. In these we can distinctly recognize hair or glandular follicles.

The cutis is entirely absent from the remainder of the preparation. This part of it is formed by the subcutaneous fat, which reveals a coarsely granular but rather uniform surface, and already a certain rigidity. This, on microscopical examination, is found dependent upon the separation of the fatty acids in the original adipose tissue.







Fig. 188.

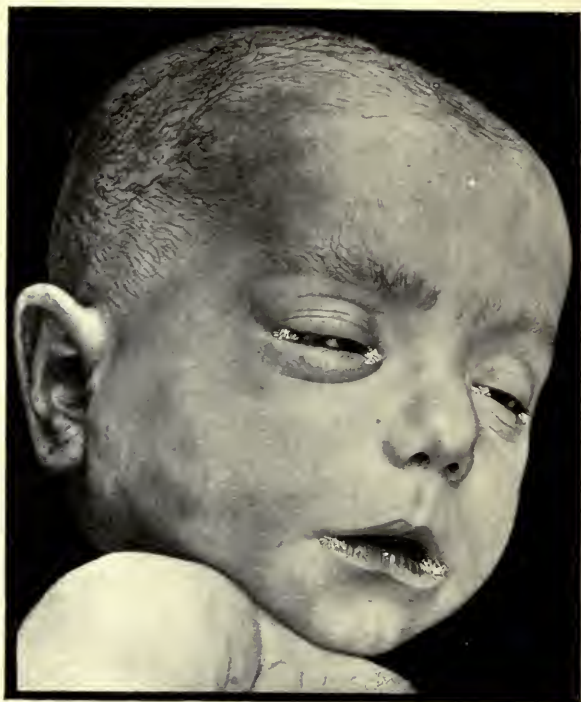
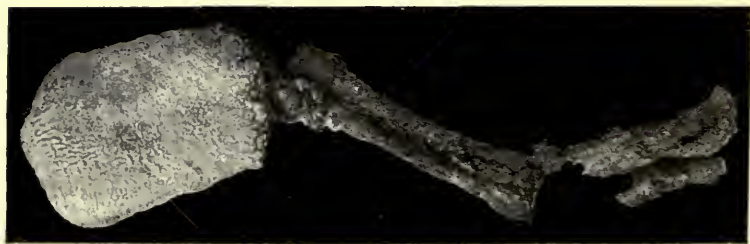
Fig. 189.



## FIGURES 188, 189.

### Fig. 188.—Larvæ of Flies in the Angles of the Eyelids and Mouth.

In FIG. 188 we see the head of a few-weeks-old child, whose body was exposed to the air, in August, for but a half-day. In the various angles of the eyelids and mouth there are whitish deposits which resemble sawdust. On closer inspection, however, these are found to consist of numerous delicate, smooth, oval, compressible bodies, about 1 mm. in length. They make up little conglomerate masses, and are loosely attached to the affected areas. These are the larvæ of flies, which are deposited on the human body by flies, especially by the *musca carnaria*, a carrion-fly. During the warm season this occurs early, frequently immediately after death, sometimes even during the agony. The flies seem instinctively to deposit their larvæ on mucous membranes or in the immediate vicinity thereof, as in these situations the larvæ most readily find nutriment. Hence the maggots crawling from the larvæ may penetrate into the deeper tissues.

The maggots, originally 1 to 1½ mm. in length, commonly develop the following day. They are very active and multiply with great rapidity. As new larvæ are constantly deposited and new maggots develop, within ten to fourteen days they may consume a child's body, with the exception of the skin, fasciæ, and other resistant tissues. In from three to four weeks they may likewise consume the body of an adult exposed to the air. The mature maggots crawl into the earth and beneath the body. They change into chrysalids at the end of about eight or ten days, and at the end of about another eight or ten days new flies develop from the chrysalids.

---

### Fig. 189.—Lower Extremity of a Newly Born Child Gnawed by Rats.

The left leg of a mature, newly born child, withdrawn from a closet-well five hours after a pretended precipitate labor. The foot, leg, knee, and lower epiphyseal end of the femur appear as a skeleton, this appearance being due to rats having consumed the soft parts.

The rest of the body was entirely fresh, and the stump of the soft parts of the left thigh limited transversely, with pale, finally dentate edges, appearing as though gnawed.

In addition, there were found refuse of the closet-well deep in the bronchi, in the stomach, and in the duodenum, and ecchymoses of the lungs and heart. From these findings it was concluded that the child was alive when it came into the fluid, and that it was drowned therein.

It is worthy of note, in the present case, that the gnawing by the rats was limited to the left leg; that it was so uniform; and that it occurred within such a short time—somewhat over four hours. The two latter facts are explicable from the voracity and probably large num-

ber of the rodents; the first, because the rest of the body being immersed in the filth, the left leg alone projected, and was thus accessible to these animals.

---

## FIGURES 190, 191.

### **Lower Half of the Body of a Newly Born Child with Numerous Puncture-like Wounds of the Skin.**

December 19th, in a large yew-tree, in the Belvedere garden, the decomposed body of a newly born, female child, 47 cm. in length, was found. It was wrapped in paper which had been softened by rain, and bound with a cord, but in such a manner that only the upper part of the body was covered, the lower part to above the genitalia being exposed.

On the anterior surface (FIG. 190) and on the posterior surface (FIG. 191) of the lower portion of the body there are numerous incisions in the skin, 3 to 4 mm. in length. They are mostly slit-like, run in the direction of the cleavage of the skin, and have rather sharp edges, which are in part dried, in part pale and non-reactive. Most of them penetrate the skin of the left thigh, many of them on its posterior aspect reaching to the muscles. Immediately above and below the popliteal space and at about the middle of the thigh there are, in addition, various obliquely directed lacerations of the skin. They are  $1\frac{1}{2}$  to 2 cm. in length, likewise non-reactive, and from them in part discolored tissues protrude. These incisions are deepest in the popliteal space, where they expose the vessels.

The necropsy revealed, in addition, rather fresh internal organs, crepitant lungs, and air-bubbles in the stomach. The cause of death was not ascertainable. In the lower epiphyseal cartilage of the femur there was a center of ossification, 5 mm. in diameter.

In respect to the numerous slit-like incisions of the skin of the lower extremities, as they exhibited no evidences of vital reaction, it was, in the first place, clear that they were produced postmortem; and it was further clear that they were a form of punctured wounds produced with a pointed and not with a cutting instrument. This latter fact is evident from the character and arrangement of the wounds, which much resemble those depicted in FIG. 107, and which were produced with a conical instrument. The first thought was that they were produced at the time the body was thrown among the branches of the yew-tree. In view, however, of the fact that analogous lesions have repeatedly been observed in decomposed bodies floating on water, it became quite certain that these wounds had been produced by birds with hard beaks (black-birds, ravens, sparrows), which had attacked the lower portions of the body not covered by the paper. The formation of such wounds produced by the birds through repeated thrusts with their beaks was favored, on the one hand, by the cleavage of the skin, and, on the other, by the advanced putrefaction of the body.

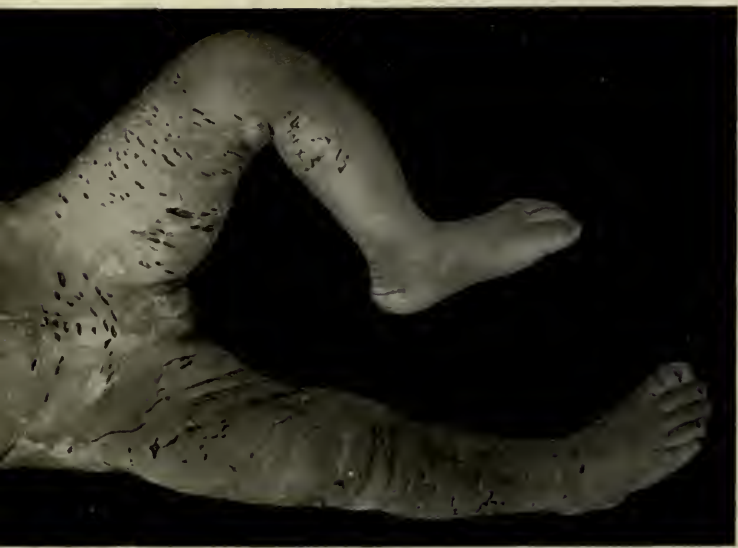

Fig. 190.

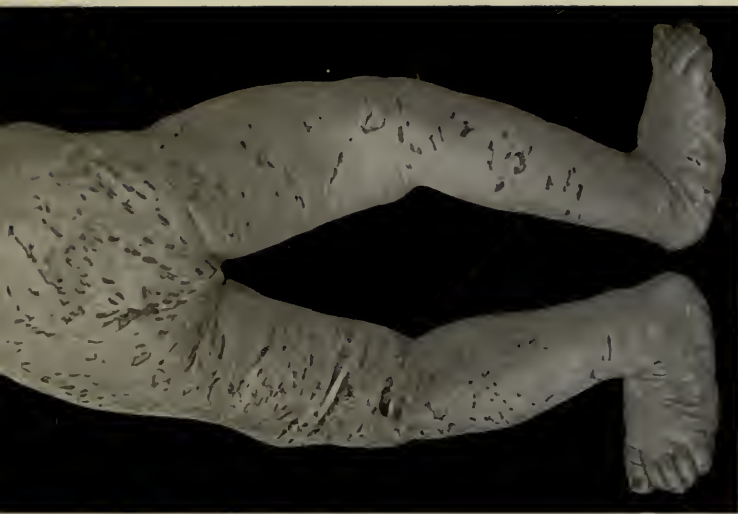
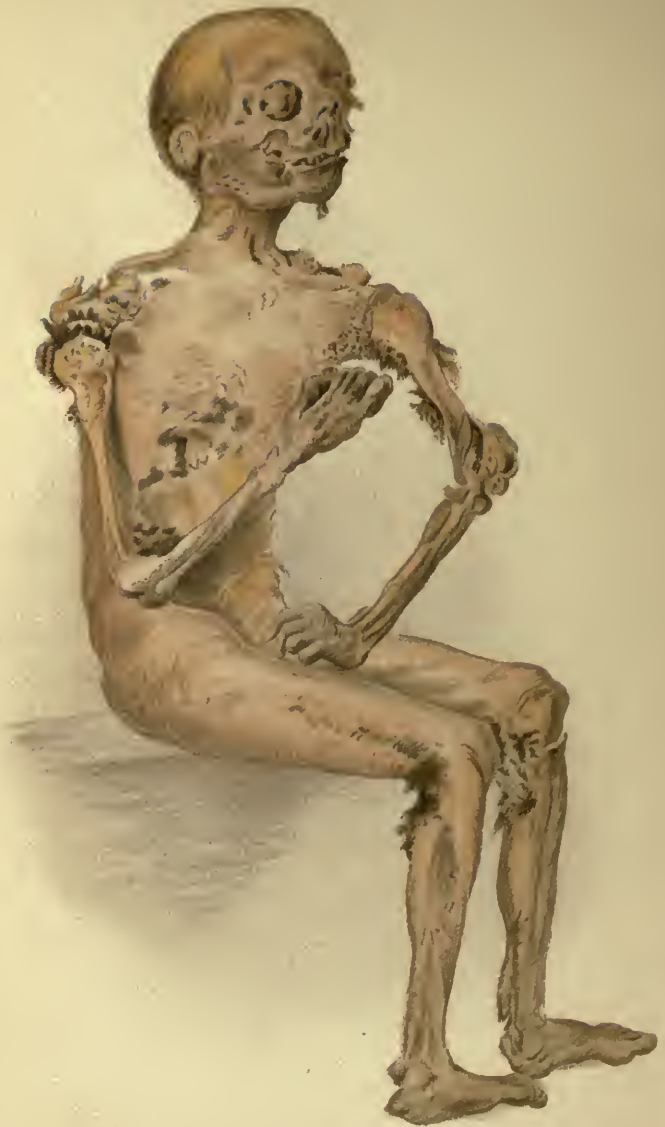

Fig. 191.







## PLATE 56.

### Mummified Cadaver.

The mummified cadaver of a man, aged 50 years, who hanged himself in an airy attic of a family vault, and was not discovered until the lapse of ten years.

The illustration is taken from the *Handbuche zum Gebrauche bei gerichtlichen Ausgrabungen und Aushebung* (Manual for Use at Legal Exhumations), by Orfila and Lesueur, Part II, 1835. It presents an instructive example of so-called *natural mummification* of a human body.

The body was found in a sitting posture hanging by a pocket handkerchief, and covered with cobwebs and dust. Of the clothing there remained but crumbling vestiges. The arms were placed as are a drummer's in action, and were in great measure deprived of soft parts. The form of the body was in general maintained. This was dependent upon the preservation of the hard, leather-like, shrunken skin, which was earth-colored, deprived of epithelium, and resonant when tapped. The panniculus adiposus and musculature, with the exception of the shrunken and dried tendons, were wanting. They were in great part replaced by dust-like detritus and a quantity of the excrement, dried larvæ, and chrysalis-remains of the beetle—*dermestes lardarius*. Of the internal organs there were found only dried vestiges of the lungs. On the head, there were only withered remains of skin, to which hairs of the head and beard were still attached. On the neck the groove produced by the strangulation-band was still discernible.

The man disappeared during November; that is, at a time of the year when conditions favorable for the processes of putrefaction were not present. This and the fact that the cadaver remained in an airy space protected from rain had induced a gradual drying of the entire body, although putrefaction had begun, but had been arrested in consequence of the absence of moisture. This drying was followed in the course of time by destruction of the musculature and of the organs by carrion-insects and their larvæ, until finally only the resistant skin remained as an empty dried envelope encircling the skeletal framework. This latter, with the remains of the tendons and the fasciæ, had not the body been discovered, would probably have lasted for many years to come.

## FIGURE 192.

### **Excessively Putrescent Body of an Old Man—in Great Part Consumed by Maggots—found Sixteen Days after Death.**

H. D., aged 78 years, an eccentric man, living alone, was found dead in his villa, on July 6th. He was sitting in his armchair, his arms hanging. He had been observed in the theater on June 19th, and was seen for the last time alive in his garden June 20th.

The body is clothed, the soft parts in great part even to the bones missing. The body is markedly putrescent, and is covered throughout with very active maggots and numerous chrysalids, which are also present in great number in the putrefying matter about the body.

The skin of the head is completely dried and leather-like, dirty brownish-black, anteriorly bald, posteriorly covered with a plentiful supply of whitish hair. The face is unrecognizable; the small amount of persistent soft parts, dried. The eyeballs are undiscernible; the orbital cavities, swarming with maggots.

At the situation of the mouth there is a wide opening surrounded by everted, dried soft parts. The jaw is without teeth and atrophic; the alveolar cavities have disappeared.

The soft parts of the neck are absent, thus exposing the vertebræ, which are disarticulated.

The thorax is covered with a thick shirt. Within the shirt there are found the disarticulated ribs entirely deprived of soft parts, and putrid and softened tissues covering the thoracic vertebræ. The thoracic and abdominal viscera are present only as unrecognizable, unctuous, highly malodorous remains, pervaded by a large number of maggots. The lumbar and sacral vertebræ are also exposed; in the pelvic cavity there is a brownish, unctuous, pulpy mass.

The bones of the upper extremities are in great part exposed; on the distal extremities of the forearm and on the hands there are still dirty reddish, moist remains of the soft parts, with here and there vestiges of the epidermis. The lower extremities, covered by trousers, are moist and unctuous. The anterior surfaces of the thighs are less moist and of a dirty brown color; here and there dried and leather-like. Of the feet, which are contained within shoes, the soft parts are almost entirely preserved. They are moist, and the true skin is exposed; in part, it is dirty red, in part green and undermined with numerous maggots. The nails of the fingers and toes, including the epidermis, have been stripped off; the external genitalia are no longer recognizable.

There is no injury to the bones; nor are there any indications of violence having been employed. The cause of death was not determinable.

Fig. 192.





In addition to a great number of maggots, there is a rather large quantity of chrysalis-forms, but none as yet empty. From these chrysalids, which were preserved in a glass, the first flies flew during the night of July 14th-15th, and the last on July 16th. The last was recognized as the *lucilia regina*.

We perceive, therefore, in the present case, in what a remarkably short time the destruction of a body exposed to the air is accomplished, and that under favorable circumstances the body of an adult may be deprived of the soft parts, leaving the bones exposed, within sixteen days. This rapid destruction is due less to putrefaction as such—that is, to the bacteria of putrefaction—than it is to maggots. These, during the warm season of the year, develop early from masses of larvæ deposited by flies (*vide* Fig. 188). They multiply rapidly and invade the soft parts, and, as new ones are continuously generated, they quickly consume the body.

As the growth, the change into chrysalis-forms of these maggots, and the development of new flies from the chrysalids, occur with considerable regularity (*vide* Fig. 188), these conditions may be employed to a certain extent to determine the time of death of a deceased person. This is well illustrated in the reported case.

FIGURE 193.

**Skull of a Five-year-old Child, with all the Temporary Teeth and the Germinal Deposits of the Permanent Teeth.**

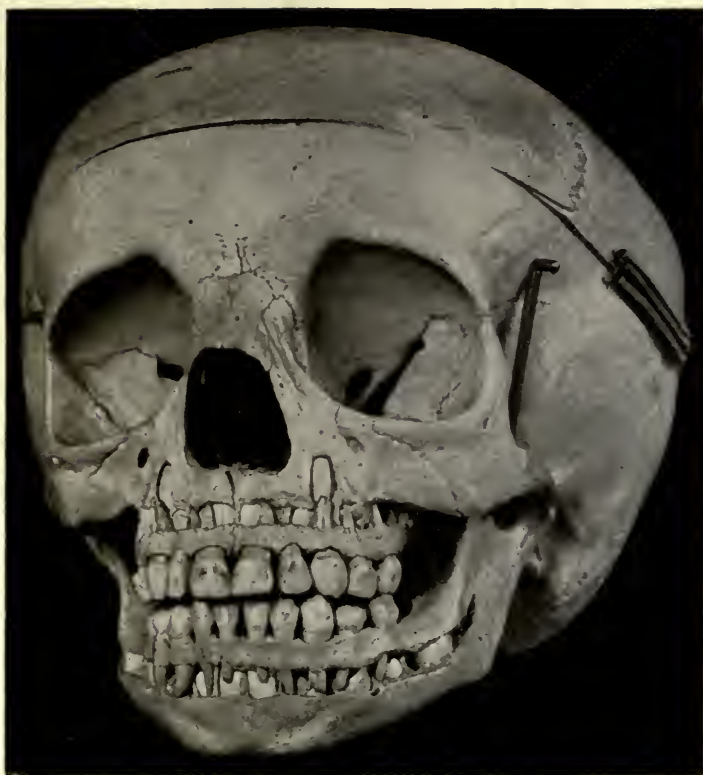This preparation is intended to illustrate important processes in the shedding of the temporary teeth which are of value in determining the age of the individual. It has been prepared by removing the anterior walls of the alveolar processes from a skull which possesses the twenty temporary teeth *in situ*. The germinal deposits of the permanent teeth which are already present are thus apparent.

As all the temporary teeth are present and their eruption complete, a condition which, as is well known, is found at the end of the second year of life, and as none of the permanent teeth have as yet appeared, it must be concluded that the skull is that of a child between the ages of two and six or seven years. Further, the good condition of the set of temporary teeth as a whole, and the appearances of the individual teeth as though they had been but little used, are evidences that the skull belongs to a period of life some years prior to the age at which the temporary teeth are shed.

As is also well known, the eruption of the permanent teeth, like that of the temporary teeth, ensues in a certain rather constant sequence, and, as a rule, the lower precede the upper. The first permanent teeth to appear are the first molars, in the sixth and seventh years; then follow, in the eighth year, the central incisors; in the ninth year, the outer incisors; in the tenth year, the bicuspid or premolars; in from the eleventh to the thirteenth year, the canines; in from the thirteenth to the sixteenth year, the second molars; and finally, in the eighteenth year or even much later, the third molars.

As is evident from the illustration, one may detect this sequence of the future eruption of the permanent teeth in their germinal deposits. It is manifest from the relatively marked development of the left lower first molar that this tooth will be the first to erupt, and that but the roof of the alveolar cavity prevents this. Next in readiness are the central incisors. The outer incisors are less prominent, though more so than the germs of the bicuspid or premolars. The canine teeth, especially the upper, are well developed, but they are situate so high that it is self-evident they cannot make their appearance until a long time subsequent to the other front teeth. The late eruption of the two posterior molar teeth is indicated by the fact that their germinal deposits are scarcely discernible.

Fig. 193.



## INDEX.

- Carunculæ myrtiformes*, Figs. 53-55  
*Caustic potash*, poisoning by, Figs. 186, 187  
     *soda*, poisoning by, Pls. 31, 32  
*Centers of ossification*, child (3½ months), Fig. 80  
     premature fetus, Fig. 80  
     mature fetus, Figs. 79, 80  
*Cervix*, after parturition, Pl. 1  
     divulsion of, from uterus, Fig. 78  
*Charcoal - fumes*, blood - alterations due to, Pl. 51  
     poisoning by, Pl. 51  
*Charred body*, Fig. 171  
*Chorion frondosum*, Fig. 72  
*Chorionic villi*, Figs. 71, 72  
*Chrysalids*, Pl. 56; Figs. 188, 192  
*Cicatrix of esophagus*, Figs. 172, 186  
     of stomach, Fig. 186  
*Cleavage of skin*, Figs. 107, 190, 191  
*Clitoris*, enlarged, Figs. 5, 6  
*Close-range gunshot-wound*, Pl. 19  
*Contusion of brain*, healed, Pl. 12  
     recent, Pls. 11, 15; Figs. 115-117, 128  
     of lung, Pl. 13  
     of viscera, Pl. 15  
*Corpus luteum*, Pl. 3  
*Corrosive sublimate*, blood-alterations due to, Pl. 30  
     poisoning by, Pls. 41-44  
*Cryptorchidism*, incomplete, Fig. 1  
*Cutting of throat*, Pl. 16; Figs. 104-106, 118, 185
- D.**
- Decidua reflexa*, Figs. 70-72  
     vera, Pl. 3; Fig. 74  
*Defects of ossification in fetal skull*, Fig. 84  
*Deflection of projectiles*, Pl. 20  
*Deformation of projectiles*, Figs. 141-169
- Deformity of penis*, Fig. 2  
*Descent of testicles*, incomplete, Fig. 1  
*Divulsion of cervix from uterus*, Fig. 78  
*Drowning*, hand after, Pls. 26, 27  
     lungs after, Pl. 25
- E.**
- Ear*, gunshot-wound of, Fig. 128  
*Embryo*, Pls. 3, 4; Figs. 71, 72, 74, 76  
*Encircling gunshot-wound*, Pl. 20  
*Epiphyses of child* (3½ months), Fig. 80  
     of mature fetus, Figs. 79, 80  
     of premature fetus, Fig. 80  
*Epispadias*, Fig. 4  
*Esophagus*, cicatrix of, Figs. 172, 186  
     perforation of, Fig. 187  
     scald-wound of, Fig. 172  
     stricture of, Figs. 172, 186, 187  
*Extradural hematoma*, Pls. 8, 9, 10  
*Extra-uterine pregnancy*, Pls. 3, 4
- F.**
- Fetal skull*, defects of ossification in, Fig. 84  
     suffocation, Pl. 5  
*Fetus*, mature, bones of, Figs. 79, 80  
     premature, bones of, Fig. 80  
*Fissures*, congenital, in skull of mature fetus, Fig. 83  
*Flames*, burns due to, Pl. 21; Figs. 170, 171  
*Flies*, larvæ of, Figs. 188, 192  
*Fracture of hyoid bone in person hanged*, Fig. 181  
     of larynx in person hanged, Figs. 181, 183  
     of ribs, Pls. 13, 15; Figs. 102, 103, 128

## INDEX.

Fracture of skull, Pls. 8, 10; Figs. 85-101, 109-111, 115-120  
Fungus-formation on cadaver in water, Pls. 28, 29

### G.

Genitalia, external, traumata of, Figs. 60-62  
Gunshot-wound, close-range, Pl. 19 encircling, Pl. 20  
of brain, Figs. 128, 129; Pl. 20  
of ear, Fig. 128  
of heart, Pl. 19; Figs. 121, 123, 128  
of lung, Fig. 123  
of mamma, Fig. 126  
of mouth, Figs. 124, 125, 127  
of skin, Pl. 19; Figs. 121, 122  
of skull, Figs. 89, 121, 122, 128, 130-140  
of tongue, Fig. 125

### H.

Hand after drowning, Pls. 26, 27  
Hanging in kneeling posture, Fig. 178  
in prone posture, Fig. 180  
in semi-sitting posture, Fig. 179  
lesions subsequent to, Pls. 22-24; Figs. 173-185  
Heart, gunshot-wound of, Pl. 19; Figs. 121, 123, 128  
Hematoma, extradural, Pls. 8, 9, 10  
Hemorrhage, intermeningeal, traumatic, Pls. 11, 12, 15; Figs. 85, 86, 91, 101, 110, 115, 116  
Hermaphroditism, masculine-pseudo, Figs. 5, 7  
Hydrochloric acid, blood-alterations due to, Pl. 30  
poisoning, Pls. 35, 36  
Hymen after parturition, Fig. 59  
annularis, Figs. 8, 9, 15, 17, 18  
bipartitus, Figs. 28-38, 45-47

Hymen, circular, Figs. 8, 9, 15, 17, 18  
deflorated, Figs. 45-58  
dentate, Figs. 21-24  
divided, Figs. 28-38, 45-47  
fimbriatus, Figs. 25-27  
irregular, Fig. 37  
labial form of, Fig. 24  
partim septus, Fig. 38  
semilunar, Figs. 10-13, 20  
septus, Figs. 28-38, 45-47  
after defloration, Figs. 56-58  
serrated, Figs. 21-24  
with congenital notches, Figs. 14-24  
with rudimentary septa, Figs. 39-44  
Hyoid bone, fracture of, in person hanged, Fig. 181

### I.

Incised wounds, Pl. 15; Figs. 113-116  
Infanticide, Fig. 81  
Infant, lungs of, Pl. 6  
Injuries, agonal, Pls. 51, 52  
Intermeningeal hemorrhage, traumatic, Pls. 11, 12, 15; Figs. 85, 86, 91, 101, 110, 115, 116  
Intestine, rupture of, Pl. 14  
stab-wound of, Pl. 18  
Irritant poisons, blood-alterations due to, Pl. 30

### J.

Jejunum, rupture of, Pl. 14

### L.

Lacerated wounds, Pl. 15  
Laceration of lungs, Figs. 102, 103, 128  
of meninges, Fig. 128  
of uterus, Fig. 76  
of vagina, Fig. 73

## INDEX.

Larvæ of dermestes lardarius, Pl. 56

of flies, Figs. 188, 192

Larynx, fracture of, in person  
hanged, Figs. 181, 183

Liver, rupture of, Fig. 111

Lividity, postmortem, abnormal po-  
sition of, Pls. 22, 53

Lungs after drowning, Pl. 25

contusion of, Pl. 13

gunshot-wound of, Fig. 123

of newly born infant, Fig. 6

laceration of, Figs. 102, 103, 128

putrefaction of, Pl. 6

Lysol-poisoning, Pl. 40

### M.

Maggots, Figs. 188, 192

Mamma, gunshot-wound of, Fig. 126

Masculine pseudohermaphrodisim,  
Figs. 5, 7

Meconium in respiratory passages,  
Pl. 5

Membranes, unruptured, causing  
suffocation, Pl. 7

Mercuric bichlorid, blood-altera-  
tions due to, Pl. 30  
poisoning by, Pls. 41-44

Migration of ovum, Pl. 3

Mouth, gunshot-wound of, Fig. 124,  
125, 127

Mummified cadaver, Pl. 56

Muscle, sternocleidomastoid, rup-  
ture of, Fig. 182

### N.

Newly born, centers of ossification  
in bones of, Fig. 80

lungs of, Pl. 6

skull of, Fig. 83

suffocation of, Fig. 81

Nitric acid, poisoning by, Pl. 37

Noose, position of, in hangings, Figs.  
173-180; Pls. 23, 24

### O.

Obstruction of pharynx, Figs. 81, 82

Organs, putrefaction of, Pl. 6

Ossification, centers of, in newly  
born, Fig. 79

defects of, in skull, Fig. 84

Os uteri after parturition, Fig. 67

of virgins, Figs. 63-66

Ovum, Pls. 3, 4; Figs. 71, 72, 74, 76

migration of, Pl. 3

### P.

Parturition, cervix after, Pl. 1

os uteri after, Fig. 67

uterus after, Pl. 1

vagina after, Pl. 1

Pelvis, flattened, Pl. 2

Penis, abnormal smallness of, Fig. 1

deformity of, Fig. 2

synechia of, Fig. 3

Perforation of esophagus, Fig. 187

of uterus, Fig. 74

Peritonitis, septic, Figs. 73, 77, 78

traumatic, Figs. 14, 18

Pharynx, obstruction of, Figs. 81, 82

Phosphorus-poisoning, Pls. 47, 48

Placenta, retention of, Figs. 68, 69

Poisoning by arsenic, Pls. 49, 50

by carbolic acid, Pls. 36, 38, 39

by carbonic oxid, Pl. 51

by charcoal-fumes, Pl. 51

by hydrochloric acid, Pls. 35, 36

by lysol, Pl. 40

by mercuric bichlorid, Pls. 41-44

by nitric acid, Pl. 37

by phosphorus, Pl. 47, 48

by potassium cyanid, Pls. 45, 46

by potassium hydrate, Figs. 186,  
187

by sodium hydrate, Pls. 31, 32

by sulphuric acid, Pls. 33, 34

Poisons, irritant, blood-alterations  
due to, Pl. 30

## INDEX.

- Postmortem injuries of the skin,  
     Pl. 22  
     lividity, abnormal position of, Pls.  
         22, 53  
 Potassium cyanid, poisoning by,  
     Pl. 45, 46  
     hydrate, poisoning by, Figs. 186,  
         187  
 Precipitate birth, pretended, Fig. 85  
 Pregnancy, uterus in early, Figs.  
     70, 71  
     extra-uterine (tubal), Pls. 3, 4  
 Premature respiration, Pl. 5  
 Projectiles, deflection of, Pl. 20  
     deformation of, Figs. 141-169  
 Pseudohermaphrodisim, masculine,  
     Figs. 5, 7  
 Punctured wounds of skin, Figs.  
     107, 112-114, 190, 191  
     of stomach, Fig. 108  
 Putrefaction of body, Fig. 192  
     of viscera, Pl. 6; Fig. 192
- R.**
- Rats, lesions due to gnawing of,  
     Fig. 189  
 Respiration, premature, Pl. 5  
 Retention of placenta, Figs. 68, 69  
 Ribs, fracture of, Pls. 13, 15; Figs.  
     102, 103, 128  
 Ricochet-shot, Pl. 20  
 Rupture of intestine, Pl. 14  
     of liver, Fig. 111  
     of sternocleidomastoid muscle,  
         Fig. 182  
     of uterus, spontaneous, Pl. 2  
     of vagina, Fig. 73
- S.**
- Sac, amniotic, Pls. 3, 4; Figs. 71, 72  
 Scald-wound of esophagus, Fig. 172  
 Scrotal synechia, Fig. 3  
 Sepsis after abortion, Figs. 74-78
- Skin, cleavage of, Fig. 107  
     gunshot-wound of, Pl. 19; Figs.  
         121, 122  
     punctured wound of, Figs. 107,  
         112, 190, 191  
 Skull, fracture of, Pls. 8, 10; Figs.  
     85-101, 109-111, 115-120  
     gunshot-wound of, Pl. 20; Figs.  
         89, 122, 128, 130-140  
     of newly born, Fig. 83  
     defects of ossification in, Fig. 84  
 Smallness of penis, Fig. 1  
 Sodium hydrate, blood-alterations  
     due to, Pl. 30  
     poisoning by, Pls. 31, 32  
 Stab-wounds, Pl. 17; Figs. 109, 110,  
     113, 114  
     of intestine, Pl. 18  
 Sternocleidomastoid muscle, rup-  
     ture of, Fig. 182  
 Stomach, cicatrix of, Fig. 186  
     punctured wounds of, Fig. 107  
 Stricture of esophagus, Figs. 172,  
     186, 187  
 Suffocation, fetal, Pl. 5  
     of newly born, Pl. 7; Figs. 81, 82  
 Sulphuric acid, blood-alterations  
     due to, Pl. 30  
     poisoning by, Pls. 33, 34
- T.**
- Teeth, permanent, Fig. 193  
     temporary, Fig. 193  
 Testicles, atrophy of, Fig. 1  
     incomplete descent of, Fig. 1  
 Throat-cutting, Pl. 16; Figs. 104-  
     106, 118, 185  
 Tongue, gunshot-wound of, Fig. 125  
 Traumatic extradural hematoma,  
     Pls. 8, 9, 10  
     intermeningeal hemorrhage, Pls.  
         11, 12, 15; Figs. 85, 86, 91,  
         101, 110, 115, 116

## INDEX.

Traumatic peritonitis, Pls. 14, 18

Tubal pregnancy, Pls. 3, 4

### U.

Umbilical vesicle, Fig. 72

Unruptured membranes (suffocation), Pl. 7

Uterus, after parturition, Pl. 1

divulsion of cervix from, Fig. 78

in early pregnancy, Figs. 70, 71

in virgins, Figs. 63-66

laceration of, Fig. 76

mouth of, after parturition, Fig. 67

perforation of, Figs. 75, 77

spontaneous rupture of, Pl. 2

### V.

Vagina after parturition, Pl. 1

laceration of, Fig. 73

perforation of, Fig. 77

punctured wound of, Fig. 74

Vesicle, umbilical, Fig. 72

Villi, chorionic, Fig. 71

Viscera, contusion of, Pl. 15

putrefaction of, Pl. 6; Fig. 192

### W.

Wound, gunshot-, at close range, Pl. 19

encircling, Pl. 20

of brain, Pl. 20; Figs. 128, 129

of ear, Fig. 128

of heart, Pl. 19; Figs. 121, 123, 128

of lung, Fig. 123

of mamma, Fig. 126

of mouth, Figs. 124, 125, 127

of skin, Fig. 122

of skull, Pl. 20; Figs. 89, 122, 128, 130-140

of tongue, Fig. 125

incised, Pl. 15; Figs. 113-116

lacerated, Pl. 15

punctured, of skin, Figs. 107, 112-114, 190, 191

of stomach, Fig. 108

of vagina, Fig. 74

scald-, of esophagus, Fig. 172

stab-, Pl. 17; Figs. 109, 110, 113, 114

of intestine, Pl. 18

## STANDARD

## Medical and Surgical Works

PUBLISHED BY

W. B. SAUNDERS, 925 Walnut Street, Philadelphia, Pa.

	PAGE		PAGE
*American Text-Book of Applied Therapeutics . . . . .	4	Lockwood's Practice of Medicine . . . . .	26
*American Text-Book of Dis. of Children . . . . .	9	Long's Syllabus of Gynecology . . . . .	20
*An American Text-Book of Diseases of the Eye, Ear, Nose, and Throat . . . . .	31	Macdonald's Surgical Diagnosis and Treatment . . . . .	31
*An American Text-Book of Genito-Urinary and Skin Diseases . . . . .	31	McFarland's Pathogenic Bacteria . . . . .	16
*American Text-Book of Gynecology . . . . .	8	Mallory and Wright's Pathological Technique . . . . .	31
*American Text-Book of Obstetrics . . . . .	5	Martin's Surgery . . . . .	28
*American Text-Book of Physiology . . . . .	3	Martin's Minor Surgery, Bandaging, and Venereal Diseases . . . . .	28
*American Text-Book of Practice . . . . .	6	Meigs' Feeding in Early Infancy . . . . .	16
*American Text-Book of Surgery . . . . .	7	Moore's Orthopedic Surgery . . . . .	31
Anders' Theory and Practice of Medicine . . . . .	31	Morris' Materia Medica and Therapeutics . . . . .	28
Ashton's Obstetrics . . . . .	28	Morris' Practice of Medicine . . . . .	28
Atlas of Skin Diseases . . . . .	12	Morten's Nurses' Dictionary . . . . .	24
Ball's Bacteriology . . . . .	28	Nancrede's Anatomy and Dissection . . . . .	17
Bastin's Laboratory Exercises in Botany . . . . .	22	Nancrede's Anatomy . . . . .	28
Beck's Surgical Asepsis . . . . .	26	Norris' Syllabus of Obstetrical Lectures . . . . .	21
Boisliniere's Obstetric Accidents . . . . .	23	Penrose's Gynecology . . . . .	31
Brockway's Physics . . . . .	28	Powell's Diseases of Children . . . . .	28
Burr's Nervous Diseases . . . . .	26	Pye's Bandaging and Surgical Dressing . . . . .	29
Butler's Materia Medica and Therapeutics . . . . .	29	Raymond's Physiology . . . . .	26
Cerna's Notes on the Newer Remedies . . . . .	18	Rowland's Clinical Skiagraphy . . . . .	14
Chapin's Compendium of Insanity . . . . .	31	Saundby's Renal and Urinary Diseases . . . . .	29
Chapman's Medical Jurisprudence . . . . .	26	*Saunders' American Year-Book of Medicine and Surgery . . . . .	32
Church and Peterson's Nervous and Mental Diseases . . . . .	31	Saunders' Medical Hand-Atlases . . . . .	33, 34
Clarkson's Histology . . . . .	14	Saunders' Pocket Medical Formulary . . . . .	19
Cohen and Eshner's Diagnosis . . . . .	28	Saunders' Pocket Medical Lexicon . . . . .	32
Corwin's Diagnosis of the Thorax . . . . .	29	Saunders' New Series of Manuals . . . . .	25, 26
Cragin's Gynecology . . . . .	28	Saunders' Series of Question Compendis . . . . .	27, 28
Crookshank's Text-Book of Bacteriology . . . . .	13	Sayre's Practice of Pharmacy . . . . .	28
DaCosta's Manual of Surgery . . . . .	26	Semple's Pathology and Morbid Anatomy . . . . .	28
De Schweinitz's Diseases of the Eye . . . . .	15	Semple's Legal Medicine, Toxicology, and Hygiene . . . . .	28
Dorland's Obstetrics . . . . .	26	Senn's Genito-Urinary Tuberculosis . . . . .	31
Frothingham's Bacteriological Guide . . . . .	16	Senn's Tumors . . . . .	11
Garrigues' Diseases of Women . . . . .	20	Senn's Syllabus of Lectures on Surgery . . . . .	21
Gleason's Diseases of the Ear . . . . .	28	Shaw's Nervous Diseases and Insanity . . . . .	28
*Gould and Pyle's Anomalies and Curiosities of Medicine . . . . .	30	Starr's Diet-Lists for Children . . . . .	24
Griffin's Materia Medica and Therapeutics . . . . .	26	Stelwagon's Diseases of the Skin . . . . .	28
Griffith's Care of the Baby . . . . .	24	Stengel's Manual of Pathology . . . . .	26
Gross's Autobiography . . . . .	10	Stevens' Materia Medica and Therapeutics . . . . .	18
Hampton's Nursing . . . . .	23	Stevens' Practice of Medicine . . . . .	17
Hare's Physiology . . . . .	28	Stewart's Manual of Physiology . . . . .	21
Hart's Diet in Sickness and in Health . . . . .	22	Stewart and Lawrance's Medical Electricity . . . . .	28
Haynes' Manual of Anatomy . . . . .	26	Stoney's Practical Points in Nursing . . . . .	13
Heisler's Embryology . . . . .	31	Sutton and Giles' Diseases of Women . . . . .	26
Hirst's Obstetrics . . . . .	31	Thomas's Diet-List and Sick-Room Dietary . . . . .	24
Hyde's Syphilis and Venereal Diseases . . . . .	26	Thornton's Dose-Book and Manual of Prescription-Writing . . . . .	26
Jackson and Gleason's Diseases of the Eye, Nose, and Throat . . . . .	28	Van Valzah and Nisbet's Diseases of the Stomach . . . . .	31
Keating's Pronouncing Dictionary . . . . .	10	Vierordt and Stuart's Medical Diagnosis . . . . .	12
Keating's Life Insurance . . . . .	23	Warren's Surgical Pathology . . . . .	11
Keen's Operation Blanks . . . . .	22	Wolff's Chemistry . . . . .	28
Keen's Surgery of Typhoid Fever . . . . .	31	Wolff's Examination of Urine . . . . .	28
Kyle's Diseases of Nose and Throat . . . . .	26		
Lainé's Temperature Charts . . . . .	18		

The works indicated thus (\*) are sold by SUBSCRIPTION (*not by booksellers*), usually through travelling solicitors, but they can be obtained *direct* from the office of publication (charges of shipment prepaid) by remitting the quoted prices. Full *descriptive circulars* of such works will be sent to any address upon application.

All the other books advertised in this catalogue are commonly for sale by *booksellers* in all parts of the United States; but any book will be sent by the publisher to any address (post-paid) on receipt of the price herein given.

For list of the latest publications, see page 31.

## GENERAL INFORMATION.

---

**One Price.** One price absolutely without deviation. No discounts allowed, regardless of the number of books purchased at one time. Prices on all works have been fixed extremely low, with the view to selling them strictly net and for cash.

**Orders.** An order accompanied by remittance will receive prompt attention, books being sent to any address in the United States, by mail or express, all charges prepaid. We prefer to send books by **express** when possible, and if sent C. O. D. **we pay all charges** for returning the money. Small orders of three dollars or less **must invariably be accompanied by remittance.**

**How to Send Money by Mail.** There are four ways by which money can be sent at our risk, namely: a post-office money order, an express money order, a bank-check (draft), and in a registered letter. Money sent in any other way is at the sender's risk. Silver should not be sent through the mail.

**Shipments.** All books, being packed in patent metal-edged boxes, necessarily reach our patrons by mail or express in excellent condition.

**Subscription Books.** Books in our catalogue marked "For sale by subscription only" may be secured by ordering them through any of our authorized travelling salesmen, or direct from the Philadelphia office; they are **not** for sale by booksellers. All other books in our catalogue can be procured of any bookseller at the advertised prices, or directly from us. *We handle only our own publications*, and cannot supply second-hand books nor the publications of other houses.

**Latest Editions.** In every instance the latest revised edition is sent.

**Bindings.** In ordering, be careful to state the style of binding desired—Cloth, Sheep, or Half-Morocco.

**Descriptive Circulars.** A complete descriptive circular, giving table of contents, etc. of any book sold by subscription only, will be sent free on application.

## For Sale by Subscription.

**AN AMERICAN TEXT-BOOK OF PHYSIOLOGY.** Edited by WILLIAM H. HOWELL, PH. D., M. D., Professor of Physiology in the Johns Hopkins University, Baltimore, Md. One handsome octavo volume of 1052 pages, fully illustrated. Prices: Cloth, \$6.00 net; Sheep or Half-Morocco, \$7.00 net.

This work is the most notable attempt yet made in America to combine in one volume the entire subject of Human Physiology by well-known teachers who have given especial study to that part of the subject upon which they write. The completed work represents the present status of the science of Physiology, particularly from the standpoint of the student of medicine and of the medical practitioner.

The collaboration of several teachers in the preparation of an elementary text-book of physiology is unusual, the almost invariable rule heretofore having been for a single author to write the entire book. One of the advantages to be derived from this collaboration method is that the more limited literature necessary for consultation by each author has enabled him to base his elementary account upon a comprehensive knowledge of the subject assigned to him; another, and perhaps the most important, advantage is that the student gains the point of view of a number of teachers. In a measure he reaps the same benefit as would be obtained by following courses of instruction under different teachers. The different standpoints assumed, and the differences in emphasis laid upon the various lines of procedure, chemical, physical, and anatomical, should give the student a better insight into the methods of the science as it exists to-day. The work will also be found useful to many medical practitioners who may wish to keep in touch with the development of modern physiology.

The main divisions of the subject-matter are as follows: General Physiology of Muscle and Nerve—Secretion—Chemistry of Digestion and Nutrition—Movements of the Alimentary Canal, Bladder, and Ureter—Blood and Lymph—Circulation—Respiration—Animal Heat—Central Nervous System—Special Senses—Special Muscular Mechanisms—Reproduction—Chemistry of the Animal Body.

### CONTRIBUTORS:

**HENRY P. BOWDITCH, M. D.,**  
Professor of Physiology, Harvard Medical School.

**JOHN G. CURTIS, M. D.,**  
Professor of Physiology, Columbia University, N. Y. (College of Physicians and Surgeons).

**HENRY H. DONALDSON, Ph. D.,**  
Head-Professor of Neurology, University of Chicago.

**W. H. HOWELL, Ph. D., M. D.,**  
Professor of Physiology, Johns Hopkins University.

**FREDERIC S. LEE, Ph. D.,**  
Adjunct Professor of Physiology, Columbia University, N. Y. (College of Physicians and Surgeons).

**WARREN P. LOMBARD, M. D.,**  
Professor of Physiology, University of Michigan.

**GRAHAM LUSK, Ph. D.,**  
Professor of Physiology, Yale Medical School.

**W. T. PORTER, M. D.,**  
Assistant Professor of Physiology, Harvard Medical School.

**EDWARD T. REICHERT, M. D.,**  
Professor of Physiology, University of Pennsylvania.

**HENRY SEWALL, Ph. D., M. D.,**  
Professor of Physiology, Medical Department, University of Denver.

## For Sale by Subscription.

**AN AMERICAN TEXT-BOOK OF APPLIED THERAPEUTICS.** For the Use of Practitioners and Students. Edited by JAMES C. WILSON, M. D., Professor of the Practice of Medicine and of Clinical Medicine in the Jefferson Medical College. One handsome octavo volume of 1326 pages. Illustrated. Prices: Cloth, \$7.00 net; Sheep or Half-Morocco, \$8.00 net.

*The arrangement* of this volume has been based, so far as possible, upon modern pathologic doctrines, beginning with the intoxications, and following with infections, diseases due to internal parasites, diseases of undetermined origin, and finally the disorders of the several bodily systems—digestive, respiratory, circulatory, renal, nervous, and cutaneous. It was thought proper to include also a consideration of the disorders of pregnancy.

*The list of contributors* comprises the names of many who have acquired distinction as practitioners and teachers of practice, of clinical medicine, and of the specialties.

### CONTRIBUTORS:

- |                                         |                                            |
|-----------------------------------------|--------------------------------------------|
| Dr. I. E. Atkinson, Baltimore, Md.      | Dr. James Hendrie Lloyd, Philadelphia, Pa. |
| Sanger Brown, Chicago, Ill.             | John Noland Mackenzie, Baltimore, Md.      |
| John B. Chapin, Philadelphia, Pa.       | J. W. McLaughlin, Austin, Texas.           |
| William C. Dabney, Charlottesville, Va. | A. Lawrence Mason, Boston, Mass.           |
| John Chalmers DaCosta, Philada., Pa.    | Charles K. Mills, Philadelphia, Pa.        |
| I. N. Danforth, Chicago, Ill.           | John K. Mitchell, Philadelphia, Pa.        |
| John L. Dawson, Jr., Charleston, S. C.  | W. P. Northrup, New York City.             |
| F. X. Dercum, Philadelphia, Pa.         | William Osler, Baltimore, Md.              |
| George Dock, Ann Arbor, Mich.           | Frederick A. Packard, Philadelphia, Pa.    |
| Robert T. Edes, Jamaica Plain, Mass.    | Theophilus Parvin, Philadelphia, Pa.       |
| Augustus A. Eshner, Philadelphia, Pa.   | Beaven Rake, London, England.              |
| J. T. Eskridge, Denver, Col.            | E. O. Shakespeare, Philadelphia, Pa.       |
| F. Forchheimer, Cincinnati, O.          | Wharton Sinkler, Philadelphia, Pa.         |
| Carl Frese, Philadelphia, Pa.           | Louis Starr, Philadelphia, Pa.             |
| Edwin E. Graham, Philadelphia, Pa.      | Henry W. Stelwagon, Philadelphia, Pa.      |
| John Guit  ras, Philadelphia, Pa.       | James Stewart, Montreal, Canada.           |
| Frederick P. Henry, Philadelphia, Pa.   | Charles G. Stockton, Buffalo, N. Y.        |
| Guy Hinsdale, Philadelphia, Pa.         | James Tyson, Philadelphia, Pa.             |
| Orville Horwitz, Philadelphia, Pa.      | Victor C. Vaughan, Ann Arbor, Mich.        |
| W. W. Johnston, Washington, D. C.       | James T. Whittaker, Cincinnati, O.         |
| Ernest Laplace, Philadelphia, Pa.       | J. C. Wilson, Philadelphia, Pa.            |
| A. Laveran, Paris, France.              |                                            |

*The articles*, with two exceptions, are the contributions of American writers. Written from the standpoint of the practitioner, the aim of the work is to facilitate the application of knowledge to the prevention, the cure, and the alleviation of disease. The endeavor throughout has been to conform to the title of the book—Applied Therapeutics—to indicate the course of treatment to be pursued at the bedside, rather than to name a list of drugs that have been used at one time or another.

While the scientific superiority and the practical desirability of the metric system of weights and measures is admitted, it has not been deemed best to discard entirely the older system of figures, so that both sets have been given where occasion demanded.

## For Sale by Subscription.

**AN AMERICAN TEXT-BOOK OF OBSTETRICS.** Edited by RICHARD C. NORRIS, M. D.; Art Editor, ROBERT L. DICKINSON, M. D. One handsome octavo volume of over 1000 pages, with nearly 900 colored and half-tone illustrations. Prices: Cloth, \$7.00; Sheep or Half-Morocco, \$8.00.

The advent of each successive volume of the *series* of the AMERICAN TEXT-BOOKS has been signalized by the most flattering comment from both the Press and the Profession. The high consideration received by these text-books, and their attainment to an authoritative position in current medical literature, have been matters of deep *international* interest, which finds its fullest expression in the demand for these publications from all parts of the civilized world.

In the preparation of the "AMERICAN TEXT-BOOK OF OBSTETRICS" the editor has called to his aid proficient collaborators whose professional prominence entitles them to recognition, and whose disquisitions exemplify **Practical Obstetrics**. While these writers were each assigned special themes for discussion, the correlation of the subject-matter is, nevertheless, such as ensures logical connection in treatment, the deductions of which thoroughly represent the latest advances in the science, and which elucidate *the best modern methods of procedure*.

The more conspicuous feature of the treatise is its wealth of illustrative matter. The production of the illustrations had been in progress for several years, under the personal supervision of Robert L. Dickinson, M. D., to whose artistic judgment and professional experience is due the **most sumptuously illustrated work of the period**. By means of the photographic art, combined with the skill of the artist and draughtsman, conventional illustration is superseded by rational methods of delineation.

Furthermore, the volume is a revelation as to the possibilities that may be reached in mechanical execution, through the unsparing hand of its publisher.

### CONTRIBUTORS:

Dr. James C. Cameron.  
Edward P. Davis.  
Robert L. Dickinson.  
Charles Warrington Earle.  
James H. Etheridge.  
Henry J. Garrigues.  
Barton Cooke Hirst.  
Charles Jewett.

Dr. Howard A. Kelly.  
Richard C. Norris.  
Chauncey D. Palmer.  
Theophilus Parvin.  
George A. Piersol.  
Edward Reynolds.  
Henry Schwarz.

"At first glance we are overwhelmed by the magnitude of this work in several respects, viz.: First, by the size of the volume, then by the array of eminent teachers in this department who have taken part in its production, then by the profuseness and character of the illustrations, and last, but not least, the conciseness and clearness with which the text is rendered. This is an entirely new composition, embodying the highest knowledge of the art as it stands to-day by authors who occupy the front rank in their specialty, and there are many of them. We cannot turn over these pages without being struck by the superb illustrations which adorn so many of them. We are confident that this most practical work will find instant appreciation by practitioners as well as students."—*New York Medical Times*.

Permit me to say that your American Text-Book of Obstetrics is the most magnificent medical work that I have ever seen. I congratulate you and thank you for this superb work, which alone is sufficient to place you first in the ranks of medical publishers.

With profound respect I am sincerely yours,

ALEX. J. C. SKENE.

## For Sale by Subscription.

**AN AMERICAN TEXT-BOOK ON THE THEORY AND PRACTICE OF MEDICINE.** By American Teachers. Edited by WILLIAM PEPPER, M. D., LL.D., Provost and Professor of the Theory and Practice of Medicine and of Clinical Medicine in the University of Pennsylvania. Complete in two handsome royal-octavo volumes of about 1000 pages each, with illustrations to elucidate the text wherever necessary. Price per Volume: Cloth, \$5.00 net; Sheep or Half-Morocco, \$6.00 net.

### VOLUME I. CONTAINS:

Hygiene.—Fever (Ephemeral, Simple Continued, Typhus, Typhoid, Epidemic Cerebrospinal Meningitis, and Relapsing).—Scarlatina, Measles, Rôtheln, Variola, Varioloid, Vaccinia, Varicella, Mumps, Whooping-cough, Anthrax, Hydrophobia, Trichinosis, Actino-

mycosis, Glanders, and Tetanus.—Tuberculosis, Scrofula, Syphilis, Diphtheria, Erysipelas, Malaria, Cholera, and Yellow Fever.—Nervous, Muscular, and Mental Diseases etc.

### VOLUME II. CONTAINS:

Urine (Chemistry and Microscopy).—Kidney and Lungs.—Air-passages (Larynx and Bronchi) and Pleura.—Pharynx, Esophagus, Stomach and Intestines (including Intestinal Parasites), Heart, Aorta, Arteries and Veins.

—Peritoneum, Liver, and Pancreas.—Diathetic Diseases (Rheumatism, Rheumatoid Arthritis, Gout, Lithæmia, and Diabetes).—Blood and Spleen.—Inflammation, Embolism, Thrombosis, Fever, and Bacteriology.

The articles are not written as though addressed to students in lectures, but are exhaustive descriptions of diseases, with the newest facts as regards Causation, Symptomatology, Diagnosis, Prognosis, and Treatment, including a large number of approved formulæ. The recent advances made in the study of the bacterial origin of various diseases are fully described, as well as the bearing of the knowledge so gained upon prevention and cure. The subjects of Bacteriology as a whole and of Immunity are fully considered in a separate section.

Methods of diagnosis are given the most minute and careful attention, thus enabling the reader to learn the very latest methods of investigation without consulting works specially devoted to the subject.

### CONTRIBUTORS:

Dr. J. S. Billings, Philadelphia.  
Francis Delafield, New York.  
Reginald H. Fitz, Boston.  
James W. Holland, Philadelphia.  
Henry M. Lyman, Chicago.  
William Osler, Baltimore.

Dr. William Pepper, Philadelphia.  
W. Gilman Thompson, New York.  
W. H. Welch, Baltimore.  
James T. Whittaker, Cincinnati.  
James C. Wilson, Philadelphia.  
Horatio C. Wood, Philadelphia.

"We reviewed the first volume of this work, and said: 'It is undoubtedly one of the best text-books on the practice of medicine which we possess.' A consideration of the second and last volume leads us to modify that verdict and to say that the completed work is, in our opinion, THE BEST of its kind it has ever been our fortune to see. It is complete, thorough, accurate, and clear. It is well written, well arranged, well printed, well illustrated, and well bound. It is a model of what the modern text-book should be."—*New York Medical Journal*.

"A library upon modern medical art. The work must promote the wider diffusion of sound knowledge."—*American Lancet*.

"A trusty counsellor for the practitioner or senior student, on which he may implicitly rely."—*Edinburgh Medical Journal*.

## For Sale by Subscription.

**AN AMERICAN TEXT-BOOK OF SURGERY.** Edited by WILLIAM W. KEEN, M.D., LL.D., and J. WILLIAM WHITE, M.D., PH. D. Forming one handsome royal-octavo volume of 1250 pages (10 x 7 inches), with 500 wood-cuts in text, and 37 colored and half-tone plates, many of them engraved from original photographs and drawings furnished by the authors. Prices: Cloth, \$7.00 net; Sheep or Half-Morocco, \$8.00 net.

### SECOND EDITION, REVISED AND ENLARGED,

With a Section devoted to "The Use of the Röntgen Rays in Surgery."

The want of a text-book which could be used by the practitioner and at the same time be recommended to the medical student has been deeply felt, especially by teachers of surgery; hence, when it was suggested to a number of these that it would be well to unite in preparing a text-book of this description, great unanimity of opinion was found to exist, and the gentlemen below named gladly consented to join in its production. While there is no distinctive American Surgery, yet America has contributed very largely to the progress of modern surgery, and among the foremost of those who have aided in developing this art and science will be found the authors of the present volume. All of them are teachers of surgery in leading medical schools and hospitals in the United States and Canada.

Especial prominence has been given to Surgical Bacteriology, a feature which is believed to be unique in a surgical text-book in the English language. Asepsis and Antisepsis have received particular attention. The text is brought well up to date in such important branches as cerebral, spinal, intestinal, and pelvic surgery, the most important and newest operations in these departments being described and illustrated.

The text of the entire book has been submitted to all the authors for their mutual criticism and revision—an idea in book-making that is entirely new and original. The book as a whole, therefore, expresses on all the important surgical topics of the day the consensus of opinion of the eminent surgeons who have joined in its preparation.

One of the most attractive features of the book is its illustrations. Very many of them are original and faithful reproductions of photographs taken directly from patients or from specimens.

### CONTRIBUTORS:

Dr. Charles H. Burnett, Philadelphia.  
Phineas S. Conner, Cincinnati.  
Frederic S. Dennis, New York.  
William W. Keen, Philadelphia.  
Charles B. Nancrede, Ann Arbor, Mich.  
Roswell Park, Buffalo, N. Y.  
Lewis S. Pilcher, New York.

Dr. Nicholas Senn, Chicago.  
Francis J. Shepherd, Montreal, Canada.  
Lewis A. Stimson, New York.  
William Thomson, Philadelphia.  
J. Collins Warren, Boston.  
J. William White, Philadelphia.

"If this text-book is a fair reflex of the present position of American surgery, we must admit it is of a very high order of merit, and that English surgeons will have to look very carefully to their laurels if they are to preserve a position in the van of surgical practice."—*London Lancet*.

## For Sale by Subscription.

### AN AMERICAN TEXT-BOOK OF GYNECOLOGY, MEDICAL AND SURGICAL, for the use of Students and Practitioners.

Edited by J. M. BALDY, M. D. Forming a handsome royal-octavo volume, with 341 illustrations in text and 38 colored and half-tone plates. Prices: Cloth, \$6.00 net; Sheep or Half-Morocco, \$7.00 net.

### SECOND EDITION, THOROUGHLY REVISED.

In this volume all anatomical descriptions, excepting those essential to a clear understanding of the text, have been omitted, the illustrations being largely depended upon to elucidate the anatomy of the parts. This work, which is thoroughly practical in its teachings, is intended, as its title implies, to be a working text-book for physicians and students. A clear line of treatment has been laid down in every case, and although no attempt has been made to discuss mooted points, still the most important of these have been noted and explained. The operations recommended are fully illustrated, so that the reader, having a picture of the procedure described in the text under his eye, cannot fail to grasp the idea. All extraneous matter and discussions have been carefully excluded, the attempt being made to allow no unnecessary details to cumber the text. The subject-matter is brought up to date at every point, and the work is as nearly as possible the combined opinions of the ten specialists who figure as the authors.

### CONTRIBUTORS:

Dr. Henry T. Byford.  
John M. Baldy.  
Edwin Cragin.  
J. H. Etheridge.  
William Goodell.

Dr. Howard A. Kelly.  
Florian Krug.  
E. E. Montgomery.  
William R. Pryor.  
George M. Tuttle.

"The most notable contribution to gynecological literature since 1887, . . . and the most complete exponent of gynecology which we have. No subject seems to have been neglected, . . . and the gynecologist and surgeon, and the general practitioner who has any desire to practise diseases of women, will find it of practical value. In the matter of illustrations and plates the book surpasses anything we have seen."—*Boston Medical and Surgical Journal*.

"A valuable addition to the literature of Gynecology. The writers are progressive, aggressive, and earnest in their convictions."—*Medical News*, Philadelphia.

"A thoroughly modern text-book, and gives reliable and well-tempered advice and instruction."—*Edinburgh Medical Journal*.

"The harmony of its conclusions and the homogeneity of its style give it an individuality which suggests a single rather than a multiple authorship."—*Annals of Surgery*.

"It must command attention and respect as a worthy representation of our advanced clinical teaching."—*American Journal of Medical Sciences*.

## For Sale by Subscription.

**AN AMERICAN TEXT-BOOK OF THE DISEASES OF CHILDREN.** By American Teachers. Edited by LOUIS STARR, M. D., assisted by THOMPSON S. WESTCOTT, M. D. In one handsome royal-8vo volume of 1250 pages, profusely illustrated with wood-cuts, half-tone and colored plates. Net Prices: Cloth, \$7.00; Sheep or Half-Morocco, \$8.00.

### SECOND EDITION, REVISED AND ENLARGED.

The plan of this work embraces a series of original articles written by some sixty well-known pædiatrists, representing collectively the teachings of the most prominent medical schools and colleges of America. The work is intended to be a PRACTICAL book, suitable for constant and handy reference by the practitioner and the advanced student.

Especial attention has been given to the latest accepted teachings upon the etiology, symptoms, pathology, diagnosis, and treatment of the disorders of children, with the introduction of many special formulæ and therapeutic procedures.

Special chapters embrace at unusual length the Diseases of the Eye, Ear, Nose and Throat, and the Skin; while the introductory chapters cover fully the important subjects of Diet, Hygiene, Exercise, Bathing, and the Chemistry of Food. Tracheotomy, Intubation, Circumcision, and such minor surgical procedures coming within the province of the medical practitioner are carefully considered.

### CONTRIBUTORS:

Dr. S. S. Adams, Washington.  
 John Ashhurst, Jr., Philadelphia.  
 A. D. Blackader, Montreal, Canada.  
 David Bovaird, New York.  
 Dillon Brown, New York.  
 Edward M. Buckingham, Boston.  
 Charles W. Burr, Philadelphia.  
 W. E. Casselberry, Chicago.  
 Henry Dwight Chapin, New York.  
 W. S. Christopher, Chicago.  
 Archibald Church, Chicago.  
 Floyd M. Crandall, New York.  
 Andrew F. Currier, New York.  
 Roland G. Curtin, Philadelphia.  
 J. M. DaCosta, Philadelphia.  
 I. N. Danforth, Chicago.  
 Edward P. Davis, Philadelphia.  
 John B. Deaver, Philadelphia.  
 G. E. de Schweinitz, Philadelphia.  
 John Dorning, New York.  
 Charles Warrington Earle, Chicago.  
 Wm. A. Edwards, San Diego, Cal.  
 F. Forchheimer, Cincinnati.  
 J. Henry Fruitnight, New York.  
 J. P. Crozer Griffith, Philadelphia.  
 W. A. Hardaway, St. Louis.  
 M. P. Hatfield, Chicago.  
 Barton Cooke Hirst, Philadelphia.  
 H. Illoway, Cincinnati.  
 Henry Jackson, Boston.  
 Charles G. Jennings, Detroit.  
 Henry Koplik, New York.

Dr. Thomas S. Latimer, Baltimore.  
 Albert R. Leeds, Hoboken, N. J.  
 J. Hendrie Lloyd, Philadelphia.  
 George Roe Lockwood, New York.  
 Henry M. Lyman, Chicago.  
 Francis T. Miles, Baltimore.  
 Charles K. Mills, Philadelphia.  
 James E. Moore, Minneapolis.  
 F. Gordon Morrill, Boston.  
 John H. Musser, Philadelphia.  
 Thomas R. Neilson, Philadelphia.  
 W. P. Northrup, New York.  
 William Osler, Baltimore.  
 Frederick A. Packard, Philadelphia.  
 William Pepper, Philadelphia.  
 Frederick Peterson, New York.  
 W. T. Plant, Syracuse, New York.  
 William M. Powell, Atlantic City.  
 B. Alexander Randall, Philadelphia.  
 Edward O. Shakespeare, Philadelphia.  
 F. C. Shattuck, Boston.  
 J. Lewis Smith, New York.  
 Louis Starr, Philadelphia.  
 M. Allen Starr, New York.  
 Charles W. Townsend, Boston.  
 James Tyson, Philadelphia.  
 W. S. Thayer, Baltimore.  
 Victor C. Vaughan, Ann Arbor, Mich.  
 Thompson S. Westcott, Philadelphia.  
 Henry R. Wharton, Philadelphia.  
 J. William White, Philadelphia.  
 J. C. Wilson, Philadelphia.

**A NEW PRONOUNCING DICTIONARY OF MEDICINE**, with **Phonetic Pronunciation, Accentuation, Etymology, etc.** By JOHN M. KEATING, M. D., LL.D., Fellow of the College of Physicians of Philadelphia; Vice-President of the American Pædiatric Society; Ex-President of the Association of Life Insurance Medical Directors; Editor "Cyclopædia of the Diseases of Children," etc.; and HENRY HAMILTON, author of "A New Translation of Virgil's Æneid into English Rhyme;" co-author of "Saunders' Medical Lexicon," etc.; with the Collaboration of J. CHALMERS DACOSTA, M. D., and FREDERICK A. PACKARD, M. D. With an Appendix containing important Tables of Bacilli, Micrococci, Leucomaines, Ptomaines, Drugs and Materials used in Antiseptic Surgery, Poisons and their Antidotes, Weights and Measures, Thermometric Scales, New Official and Unofficial Drugs, etc. One very attractive volume of over 800 pages. Second Revised Edition. Prices: Cloth, \$5.00 net; Sheep or Half-Morocco, \$6.00 net; with Denison's Patent Ready-Reference Index; without patent index, Cloth, \$4.00 net; Sheep or Half-Morocco, \$5.00 net.

#### PROFESSIONAL OPINIONS.

"I am much pleased with Keating's Dictionary, and shall take pleasure in recommending it to my classes."

HENRY M. LYMAN, M. D.,

*Professor of Principles and Practice of Medicine, Rush Medical College, Chicago, Ill.*

"I am convinced that it will be a very valuable adjunct to my study-table, convenient in size and sufficiently full for ordinary use."

C. A. LINDSLEV, M. D.,

*Professor of Theory and Practice of Medicine, Medical Dept. Yale University;  
Secretary Connecticut State Board of Health, New Haven, Conn.*

**AUTOBIOGRAPHY OF SAMUEL D. GROSS, M. D.**, Emeritus Professor of Surgery in the Jefferson Medical College of Philadelphia, with **Reminiscences of His Times and Contemporaries.** Edited by his sons, SAMUEL W. GROSS, M. D., LL.D., late Professor of Principles of Surgery and of Clinical Surgery in the Jefferson Medical College, and A. HALLER GROSS, A. M., of the Philadelphia Bar. Preceded by a Memoir of Dr. Gross, by the late Austin Flint, M. D., LL.D. In two handsome volumes, each containing over 400 pages, demy 8vo, extra cloth, gilt tops, with fine Frontispiece engraved on steel. Price per Volume, \$2.50 net.

This autobiography, which was continued by the late eminent surgeon until within three months of his death, contains a full and accurate history of his early struggles, trials, and subsequent successes, told in a singularly interesting and charming manner, and embraces short and graphic pen-portraits of many of the most distinguished men—surgeons, physicians, divines, lawyers, statesmen, scientists, etc.—with whom he was brought in contact in America and in Europe; the whole forming a retrospect of more than three-quarters of a century.

**SURGICAL PATHOLOGY AND THERAPEUTICS.** By JOHN COLLINS WARREN, M. D., LL.D., Professor of Surgery, Medical Department Harvard University; Surgeon to the Massachusetts General Hospital, etc. A handsome octavo volume of 832 pages, with 136 relief and lithographic illustrations, 33 of which are printed in colors, and all of which were drawn by William J. Kaula from original specimens. Prices: Cloth, \$6.00 net; Half-Morocco, \$7.00 net.

"The volume is for the bedside, the amphitheatre, and the ward. It deals with things not as we see them through the microscope alone, but as the practitioner sees their effect in his patients; not only as they appear in and affect culture-media, but also as they influence the human body; and, following up the demonstrations of the nature of diseases, the author points out their logical treatment." (*New York Medical Journal*). "It is the handsomest specimen of book-making \* \* \* that has ever been issued from the American medical press" (*American Journal of the Medical Sciences*, Philadelphia).

**Without Exception, the Illustrations are the Best ever Seen in a Work of this Kind.**

"A most striking and very excellent feature of this book is its illustrations. Without exception, from the point of accuracy and artistic merit, they are the best ever seen in a work of this kind. \* \* \* Many of those representing microscopic pictures are so perfect in their coloring and detail as almost to give the beholder the impression that he is looking down the barrel of a microscope at a well-mounted section."—*Annals of Surgery*, Philadelphia.

## **PATHOLOGY AND SURGICAL TREATMENT OF TUMORS.**

By N. SENN, M. D., Ph. D., LL. D., Professor of Practice of Surgery and of Clinical Surgery, Rush Medical College; Professor of Surgery, Chicago Polyclinic; Attending Surgeon to Presbyterian Hospital; Surgeon-in-Chief, St. Joseph's Hospital, Chicago. One volume of 710 pages, with 515 engravings, including full-page colored plates. Prices: Cloth, \$6.00 net; Half-Morocco, \$7.00 net.

Books specially devoted to this subject are few, and in our text-books and systems of surgery this part of surgical pathology is usually condensed to a degree incompatible with its scientific and clinical importance. The author spent many years in collecting the material for this work, and has taken great pains to present it in a manner that should prove useful as a text-book for the student, a work of reference for the busy practitioner, and a reliable, safe guide for the surgeon. The more difficult operations are fully described and illustrated. More than *one hundred* of the illustrations are original, while the remainder were selected from books and medical journals not readily accessible.

"The most exhaustive of any recent book in English on this subject. It is well illustrated, and will doubtless remain as the principal monograph on the subject in our language for some years. The book is handsomely illustrated and printed, . . . and the author has given a notable and lasting contribution to surgery."—*Journal of American Medical Association*, Chicago.

**MEDICAL DIAGNOSIS.** By Dr. OSWALD VIERORDT, Professor of Medicine at the University of Heidelberg. Translated, with additions, from the Fifth Enlarged German Edition, with the author's permission, by FRANCIS H. STUART, A. M., M. D. In one handsome royal-octavo volume of 600 pages. 194 fine wood-cuts in the text, many of them in colors. Prices: Cloth, \$4.00 net; Sheep or Half-Morocco, \$5.00 net.

**FOURTH AMERICAN EDITION, FROM THE FIFTH REVISED AND ENLARGED GERMAN EDITION.**

In this work, as in no other hitherto published, are given full and accurate explanations of the phenomena observed at the bedside. It is distinctly a clinical work by a master teacher, characterized by thoroughness, fulness, and accuracy. It is a mine of information upon the points that are so often passed over without explanation. Especial attention has been given to the germ-theory as a factor in the origin of disease.

This valuable work is now published in German, English, Russian, and Italian. The issue of a third American edition within two years indicates the favor with which it has been received by the profession.

**THE PICTORIAL ATLAS OF SKIN DISEASES AND SYPHILITIC AFFECTIONS.** (American Edition.) Translation from the French. Edited by J. J. PRINGLE, M. B., F. R. C. P., Assistant Physician to, and Physician to the department for Diseases of the Skin at, the Middlesex Hospital, London. Photo-lithochromes from the famous models of dermatological and syphilitic cases in the Museum of the Saint-Louis Hospital, Paris, with explanatory wood-cuts and letter-press. In 12 Parts, at \$3.00 per Part. Parts 1 to 8 now ready.

"The plates are beautifully executed."—JONATHAN HUTCHINSON, M. D. (London Hospital).

"The plates in this Atlas are remarkably accurate and artistic reproductions of *typical* examples of skin disease. The work will be of great value to the practitioner and student."—WILLIAM ANDERSON, M. D. (St. Thomas Hospital).

"If the succeeding parts of this Atlas are to be similar to Part 1, now before us, we have no hesitation in cordially recommending it to the favorable notice of our readers as one of the finest dermatological atlases with which we are acquainted."—*Glasgow Medical Journal*, Aug., 1895.

"Of all the atlases of skin diseases which have been published in recent years, the present one promises to be of greatest interest and value, especially from the standpoint of the general practitioner."—*American Medico-Surgical Bulletin*, Feb. 22, 1896.

"The introduction of explanatory wood-cuts in the text is a novel and most important feature which greatly furthers the easier understanding of the excellent plates, than which nothing, we venture to say, has been seen better in point of correctness, beauty, and general merit."—*New York Medical Journal*, Feb. 15, 1896.

"An interesting feature of the Atlas is the descriptive text, which is written for each picture by the physician who treated the case or at whose instigation the models have been made. We predict for this truly beautiful work a large circulation in all parts of the medical world where the names *St. Louis* and *Baretta* have preceded it."—*Medical Record*, N. Y., Feb. 1, 1896.

**PRACTICAL POINTS IN NURSING.** For Nurses in Private Practice. By EMILY A. M. STONEY, Graduate of the Training-School for Nurses, Lawrence, Mass.; Superintendent of the Training-School for Nurses, Carney Hospital, South Boston, Mass. 456 pages, handsomely illustrated with 73 engravings in the text, and 9 colored and half-tone plates. Cloth. Price, \$1.75 net.

**SECOND EDITION, THOROUGHLY REVISED.**

In this volume the author explains, in popular language and in the shortest possible form, the entire range of *private* nursing as distinguished from *hospital* nursing, and the nurse is instructed how best to meet the various emergencies of medical and surgical cases when distant from medical or surgical aid or when thrown on her own resources.

An especially valuable feature of the work will be found in the directions to the nurse how to *improvise* everything ordinarily needed in the sick-room, where the embarrassment of the nurse, owing to the want of proper appliances, is frequently extreme.

The work has been logically divided into the following sections:

- I. The Nurse: her responsibilities, qualifications, equipment, etc.
- II. The Sick-Room: its selection, preparation, and management.
- III. The Patient: duties of the nurse in medical, surgical, obstetric, and gynecologic cases.
- IV. Nursing in Accidents and Emergencies.
- V. Nursing in Special Medical Cases.
- VI. Nursing of the New-born and Sick Children.
- VII. Physiology and Descriptive Anatomy.

The APPENDIX contains much information in compact form that will be found of great value to the nurse, including Rules for Feeding the Sick; Recipes for Invalid Foods and Beverages; Tables of Weights and Measures; Table for Computing the Date of Labor; List of Abbreviations; Dose-List; and a full and complete Glossary of Medical Terms and Nursing Treatment.

"This is a well-written, eminently practical volume, which covers the entire range of private nursing as distinguished from hospital nursing, and instructs the nurse how best to meet the various emergencies which may arise and how to prepare everything ordinarily needed in the illness of her patient."—*American Journal of Obstetrics and Diseases of Women and Children*, Aug., 1896.

**A TEXT-BOOK OF BACTERIOLOGY**, including the Etiology and Prevention of Infective Diseases and an account of Yeasts and Moulds, Hæmatozoa, and Psorosperms. By EDGAR M. CROOKSHANK, M. B., Professor of Comparative Pathology and Bacteriology, King's College, London. A handsome octavo volume of 700 pages, with 273 engravings in the text, and 22 original and colored plates. Price, \$6.50 net.

This book, though nominally a Fourth Edition of Professor Crookshank's "MANUAL OF BACTERIOLOGY," is practically a new work, the old one having been reconstructed, greatly enlarged, revised throughout, and largely rewritten, forming a text-book for the Bacteriological Laboratory, for Medical Officers of Health, and for Veterinary Inspectors.

**A TEXT-BOOK OF HISTOLOGY, DESCRIPTIVE AND PRACTICAL.** For the Use of Students. By ARTHUR CLARKSON, M. B., C. M., Edin., formerly Demonstrator of Physiology in the Owen's College, Manchester; late Demonstrator of Physiology in the Yorkshire College, Leeds. Large 8vo, 554 pages, with 22 engravings in the text, and 174 beautifully colored original illustrations. Price, strongly bound in Cloth, \$6.00 net.

The purpose of the writer in this work has been to furnish the student of Histology, in one volume, with both the descriptive and the practical part of the science. The first two chapters are devoted to the consideration of the general methods of Histology; subsequently, in each chapter, the structure of the tissue or organ is first systematically described, the student is then taken tutorially over the specimens illustrating it, and, finally, an appendix affords a short note of the methods of preparation.

"We would most cordially recommend it to all students of histology."—*Dublin Medical Journal*.

"It is pleasant to give unqualified praise to the colored illustrations; . . . the standard is high, and many of them are not only extremely beautiful, but very clear and demonstrative. . . . The plan of the book is excellent."—*Liverpool Medical Journal*.

**ARCHIVES OF CLINICAL SKIAGRAPHY.** By SYDNEY ROWLAND, B. A., Camb. A series of collotype illustrations, with descriptive text, illustrating the applications of the New Photography to Medicine and Surgery. Price, per Part, \$1.00. Parts I. to V. now ready.

The object of this publication is to put on record in permanent form some of the most striking applications of the new photography to the needs of Medicine and Surgery.

The progress of this new art has been so rapid that, although Prof. Röntgen's discovery is only a thing of yesterday, it has already taken its place among the approved and accepted aids to diagnosis.

**WATER AND WATER SUPPLIES.** By JOHN C. THRESH, D. Sc., M. B., D. P. H., Lecturer on Public Health, King's College, London; Editor of the "Journal of State Medicine," etc. 12mo, 438 pages, illustrated. Handsomely bound in Cloth, with gold side and back stamps. Price, \$2.25 net.

This work will furnish any one interested in public health the information requisite for forming an opinion as to whether any supply or proposed supply is sufficiently wholesome and abundant, and whether the cost can be considered reasonable.

The work does not pretend to be a treatise on Engineering, yet it contains sufficient detail to enable any one who has studied it to consider intelligently any scheme which may be submitted for supplying a community with water.

**DISEASES OF THE EYE. A Hand-Book of Ophthalmic Practice.** By G. E. DE SCHWEINITZ, M. D., Professor of Ophthalmology in the Jefferson Medical College, Philadelphia, etc. A handsome royal-octavo volume of 679 pages, with 256 fine illustrations, many of which are original, and 2 chromo-lithographic plates. Prices: Cloth, \$4.00 net; Sheep or Half-Morocco, \$5.00 net.

The object of this work is to present to the student, and to the practitioner who is beginning work in the fields of ophthalmology, a plain description of the optical defects and diseases of the eye. To this end special attention has been paid to the clinical side of the question; and the method of examination, the symptomatology leading to a diagnosis, and the treatment of the various ocular defects have been brought into prominence.

### THIRD EDITION, THOROUGHLY REVISED.

The entire book has been thoroughly revised. In addition to this general revision, special paragraphs on the following new matter have been introduced: Filamentous Keratitis, Blood-staining of the Cornea, Essential Phthisis Bulbi, Foreign Bodies in the Lens, Circinate Retinitis, Symmetrical Changes at the Macula Lutea in Infancy, Hyaline Bodies in the Papilla, Monocular Diplopia, Subconjunctival Injections of Germicides, Infiltration-Anæsthesia, and Sterilization of Collyria. Brief mention of Ophthalmia Nodosa, Electric Ophthalmia, and Angioid Streaks in the Retina also finds place. An Appendix has been added, containing a full description of the method of determining the corneal astigmatism with the ophthalmometer of Javal and Schiötz, and the rotations of the eyes with the tropometer of Stevens. The chapter on Operations has been enlarged and rewritten.

"A clearly written, comprehensive manual. . . . One which we can commend to students as a reliable text-book, written with an evident knowledge of the wants of those entering upon the study of this special branch of medical science."—*British Medical Journal*.

"The work is characterized by a lucidity of expression which leaves the reader in no doubt as to the meaning of the language employed. . . . We know of no work in which these diseases are dealt with more satisfactorily, and indications for treatment more clearly given, and in harmony with the practice of the most advanced ophthalmologists."—*Maritime Medical News*.

"It is hardly too much to say that for the student and practitioner beginning the study of Ophthalmology, it is the best single volume at present published."—*Medical News*.

"The latest and one of the best books on Ophthalmology. The book is thoroughly up to date, and is certainly a work which not only commends itself to the student, but is a ready reference for the busy practitioner."—*International Medical Review*.

### PROFESSIONAL OPINIONS.

"A work that will meet the requirements not only of the specialist, but of the general practitioner in a rare degree. I am satisfied that unusual success awaits it."

WILLIAM PEPPER, M. D.

*Provost and Professor of Theory and Practice of Medicine and Clinical Medicine  
in the University of Pennsylvania.*

"Contains in concise and reliable form the accepted views of Ophthalmic Science."

WILLIAM THOMSON, M. D.,

*Professor of Ophthalmology, Jefferson Medical College, Philadelphia, Pa.*

**TEXT-BOOK UPON THE PATHOGENIC BACTERIA.** Specially written for Students of Medicine. By JOSEPH MCFARLAND, M. D., Professor of Pathology and Bacteriology in the Medico-Chirurgical College of Philadelphia, etc. 497 pages, finely illustrated. Price, Cloth, \$2.50 net.

**SECOND EDITION, REVISED AND GREATLY ENLARGED.**

The work is intended to be a text-book for the medical student and for the practitioner who has had no recent laboratory training in this department of medical science. The instructions given as to needed apparatus, cultures, stainings, microscopic examinations, etc. are ample for the student's needs, and will afford to the physician much information that will interest and profit him relative to a subject which modern science shows to go far in explaining the etiology of many diseased conditions.

In this second edition the work has been brought up to date in all departments of the subject, and numerous additions have been made to the technique in the endeavor to make the book fulfil the double purpose of a systematic work upon bacteria and a laboratory guide.

"It is excellently adapted for the medical students and practitioners for whom it is avowedly written. . . . The descriptions given are accurate and readable, and the book should prove useful to those for whom it is written.—*London Lancet*, Aug. 29, 1896.

"The author has succeeded admirably in presenting the essential details of bacteriological technics, together with a judiciously chosen summary of our present knowledge of pathogenic bacteria. . . . The work, we think, should have a wide circulation among English-speaking students of medicine."—*N. Y. Medical Journal*, April 4, 1896.

"The book will be found of considerable use by medical men who have not had a special bacteriological training, and who desire to understand this important branch of medical science."—*Edinburgh Medical Journal*, July, 1896.

**LABORATORY GUIDE FOR THE BACTERIOLOGIST.** By LANGDON FROTHINGHAM, M. D. V., Assistant in Bacteriology and Veterinary Science, Sheffield Scientific School, Yale University. Illustrated. Price, Cloth, 75 cents.

The technical methods involved in bacteria-culture, methods of staining, and microscopical study are fully described and arranged as simply and concisely as possible. The book is especially intended for use in laboratory work.

"It is a convenient and useful little work, and will more than repay the outlay necessary for its purchase in the saving of time which would otherwise be consumed in looking up the various points of technique so clearly and concisely laid down in its pages."—*American Med.-Surg. Bulletin*.

**FEEDING IN EARLY INFANCY.** By ARTHUR V. MEIGS, M. D. Bound in limp cloth, flush edges. Price, 25 cents net.

**SYNOPSIS:** Analyses of Milk—Importance of the Subject of Feeding in Early Infancy—Proportion of Casein and Sugar in Human Milk—Time to Begin Artificial Feeding of Infants—Amount of Food to be Administered at Each Feeding—Intervals between Feedings—Increase in Amount of Food at Different Periods of Infant Development—Unsuitableness of Condensed Milk as a Substitute for Mother's Milk—Objections to Sterilization or "Pasteurization" of Milk—Advances made in the Method of Artificial Feeding of Infants.

**ESSENTIALS OF ANATOMY AND MANUAL OF PRACTICAL DISSECTION**, containing "Hints on Dissection." By CHARLES B. NANCREDE, M. D., Professor of Surgery and Clinical Surgery in the University of Michigan, Ann Arbor; Corresponding Member of the Royal Academy of Medicine, Rome, Italy; late Surgeon Jefferson Medical College, etc. Fourth and revised edition. Post 8vo, over 500 pages, with handsome full-page lithographic plates in colors, and over 200 illustrations. Price: Extra Cloth or Oilcloth for the dissection-room, \$2.00 net.

Neither pains nor expense has been spared to make this work the most exhaustive yet concise Student's Manual of Anatomy and Dissection ever published, either in America or in Europe.

The colored plates are designed to aid the student in dissecting the muscles, arteries, veins, and nerves. The wood-cuts have all been specially drawn and engraved, and an Appendix added containing 60 illustrations representing the structure of the entire human skeleton, the whole being based on the eleventh edition of Gray's *Anatomy*.

"The plates are of more than ordinary excellence, and are of especial value to students in their work in the dissecting-room."—*Journal of American Medical Association*.

"Should be in the hands of every medical student."—*Cleveland Medical Gazette*.

"A concise and judicious work."—*Buffalo Medical and Surgical Journal*.

**A MANUAL OF PRACTICE OF MEDICINE.** By A. A. STEVENS, A. M., M. D., Instructor of Physical Diagnosis in the University of Pennsylvania, and Demonstrator of Pathology in the Woman's Medical College of Philadelphia. Specially intended for students preparing for graduation and hospital examinations, and includes the following sections: General Diseases, Diseases of the Digestive Organs, Diseases of the Respiratory System, Diseases of the Circulatory System, Diseases of the Nervous System, Diseases of the Blood, Diseases of the Kidneys, and Diseases of the Skin. Each section is prefaced by a chapter on General Symptomatology. Post 8vo, 520 pages. Numerous illustrations and selected formulæ. Price, \$2.50, bound in flexible leather.

#### FIFTH EDITION, REVISED AND ENLARGED.

Contributions to the science of medicine have poured in so rapidly during the last quarter of a century that it is well-nigh impossible for the student, with the limited time at his disposal, to master elaborate treatises or to cull from them that knowledge which is absolutely essential. From an extended experience in teaching, the author has been enabled, by classification, to group allied symptoms, and by the judicious elimination of theories and redundant explanations to bring within a comparatively small compass a complete outline of the practice of medicine.

**MANUAL OF MATERIA MEDICA AND THERAPEUTICS.**

By A. A. STEVENS, A. M., M. D., Instructor of Physical Diagnosis in the University of Pennsylvania, and Demonstrator of Pathology in the Woman's Medical College of Philadelphia. 445 pages. Price, Cloth, \$2.25.

**SECOND EDITION, REVISED.**

This wholly new volume, which is based on the last edition of the *Pharmacopœia*, comprehends the following sections: Physiological Action of Drugs; Drugs; Remedial Measures other than Drugs; Applied Therapeutics; Incompatibility in Prescriptions; Table of Doses; Index of Drugs; and Index of Diseases; the treatment being elucidated by more than two hundred formulæ.

"The author is to be congratulated upon having presented the medical student with as accurate a manual of therapeutics as it is possible to prepare."—*Therapeutic Gazette*.

"Far superior to most of its class; in fact, it is very good. Moreover, the book is reliable and accurate."—*New York Medical Journal*.

"The author has faithfully presented modern therapeutics in a comprehensive work, . . . and it will be found a reliable guide."—*University Medical Magazine*.

**NOTES ON THE NEWER REMEDIES: their Therapeutic Applications and Modes of Administration.** By DAVID CERNA, M. D., PH. D., Demonstrator of and Lecturer on Experimental Therapeutics in the University of Pennsylvania. Post-octavo, 253 pages. Price, \$1.25.

**SECOND EDITION, RE-WRITTEN AND GREATLY ENLARGED.**

The work takes up in alphabetical order all the newer remedies, giving their physical properties, solubility, therapeutic applications, administration, and chemical formula.

It thus forms a very valuable addition to the various works on therapeutics now in existence.

Chemists are so multiplying compounds, that, if each compound is to be thoroughly studied, investigations must be carried far enough to determine the practical importance of the new agents.

"Especially valuable because of its completeness, its accuracy, its systematic consideration of the properties and therapy of many remedies of which doctors generally know but little, expressed in a brief yet terse manner."—*Chicago Clinical Review*.

**TEMPERATURE CHART.** Prepared by D. T. LAINÉ, M. D. Size 8 × 13½ inches. Price, per pad of 25 charts, 50 cents.

A conveniently arranged chart for recording Temperature, with columns for daily amounts of Urinary and Fecal Excretions, Food, Remarks, etc. On the back of each chart is given in full the method of Brand in the treatment of Typhoid Fever.

**SAUNDERS' POCKET MEDICAL LEXICON**; or, Dictionary of Terms and Words used in Medicine and Surgery. By JOHN M. KEATING, M. D., editor of "Cyclopædia of Diseases of Children," etc.; author of the "New Pronouncing Dictionary of Medicine;" and HENRY HAMILTON, author of "A New Translation of Virgil's *Æneid* into English Verse;" co-author of a "New Pronouncing Dictionary of Medicine." A new and revised edition. 32mo, 282 pages. Prices: Cloth, 75 cents; Leather Tucks, \$1.00.

This new and comprehensive work of reference is the outcome of a demand for a more modern handbook of its class than those at present on the market, which, dating as they do from 1855 to 1884, are of but trifling use to the student by their not containing the hundreds of new words now used in current literature, especially those relating to Electricity and Bacteriology.

"Remarkably accurate in terminology, accentuation, and definition."—*Journal of American Medical Association*.

"Brief, yet complete . . . it contains the very latest nomenclature in even the newest departments of medicine."—*New York Medical Record*.

**SAUNDERS' POCKET MEDICAL FORMULARY.** By WILLIAM M. POWELL, M. D., Attending Physician to the Mercer House for Invalid Women at Atlantic City. Containing 1800 Formulæ, selected from several hundred of the best-known authorities. Forming a handsome and convenient pocket companion of nearly 300 printed pages, with blank leaves for Additions; with an Appendix containing Posological Table, Formulæ and Doses for Hypodermatic Medication, Poisons and their Antidotes, Diameters of the Female Pelvis and Foetal Head, Obstetrical Table, Diet List for Various Diseases, Materials and Drugs used in Antiseptic Surgery, Treatment of Asphyxia from Drowning, Surgical Remembrancer, Tables of Incompatibles, Eruptive Fevers, Weights and Measures, etc. Fourth edition, revised and greatly enlarged. Handsomely bound in morocco, with side index, wallet, and flap. Price, \$1.75 net.

A concise, clear, and correct record of the many hundreds of famous formulæ which are found scattered through the works of the *most eminent physicians and surgeons* of the world. The work is helpful to the student and practitioner alike, as through it they become acquainted with numerous formulæ which are not found in text-books, but have been collected from among *the rising generation of the profession, college professors, and hospital physicians and surgeons*.

"This little book, that can be conveniently carried in the pocket, contains an immense amount of material. It is very useful, and as the name of the author of each prescription is given is unusually reliable."—*New York Medical Record*.

"Designed to be of immense help to the general practitioner in the exercise of his daily calling."—*Boston Medical and Surgical Journal*.

**DISEASES OF WOMEN.** By HENRY J. GARRIGUES, A. M., M. D., Professor of Gynecology and Obstetrics in the New York School of Clinical Medicine; Gynecologist to St. Mark's Hospital and to the German Dispensary, New York City. In one handsome octavo volume of 728 pages, illustrated by 335 engravings and colored plates. Prices: Cloth, \$4.00 net; Sheep or Half Morocco, \$5.00 net.

A PRACTICAL work on gynecology for the use of students and practitioners, written in a terse and concise manner. The importance of a thorough knowledge of the anatomy of the female pelvic organs has been fully recognized by the author, and considerable space has been devoted to the subject. The chapters on Operations and on Treatment are thoroughly modern, and are based upon the large hospital and private practice of the author. The text is elucidated by a large number of illustrations and colored plates, many of them being original, and forming a complete atlas for studying *embryology* and the *anatomy* of the *female genitalia*, besides exemplifying, whenever needed, morbid conditions, instruments, apparatus, and operations.

*Second Edition, Thoroughly Revised.*

The first edition of this work met with a most appreciative reception by the medical press and profession both in this country and abroad, and was adopted as a text-book or recommended as a book of reference by nearly *one hundred* colleges in the United States and Canada. The author has availed himself of the opportunity afforded by this revision to embody the latest approved advances in the treatment employed in this important branch of Medicine. He has also more extensively expressed his own opinion on the comparative value of the different methods of treatment employed.

"One of the best text-books for students and practitioners which has been published in the English language; it is condensed, clear, and comprehensive. The profound learning and great clinical experience of the distinguished author find expression in this book in a most attractive and instructive form. Young practitioners, to whom experienced consultants may not be available, will find in this book invaluable counsel and help."

THAD. A. REAMY, M. D., LL.D.,

*Professor of Clinical Gynecology, Medical College of Ohio; Gynecologist to the Good Samaritan and Cincinnati Hospitals.*

**A SYLLABUS OF GYNECOLOGY**, arranged in conformity with "An American Text-Book of Gynecology." By J. W. LONG, M. D., Professor of Diseases of Women and Children, Medical College of Virginia, etc. Price, Cloth (interleaved), \$1.00 net.

Based upon the teaching and methods laid down in the larger work, this will not only be useful as a supplementary volume, but to those who do not already possess the text-book it will also have an independent value as an aid to the practitioner in gynecological work, and to the student as a guide in the lecture-room, as the subject is presented in a manner at once systematic, clear, succinct, and practical.

**A MANUAL OF PHYSIOLOGY, with Practical Exercises. For Students and Practitioners.** By G. N. STEWART, M. A., M. D., D. Sc., lately Examiner in Physiology, University of Aberdeen, and of the New Museums, Cambridge University; Professor of Physiology in the Western Reserve University, Cleveland, Ohio. Handsome octavo volume of 800 pages, with 278 illustrations in the text, and 5 colored plates. Price, Cloth, \$3.50 net.

"It will make its way by sheer force of merit, and amply deserves to do so. It is one of the very best English text-books on the subject."—*London Lancet*.

"Of the many text-books of physiology published, we do not know of one that so nearly comes up to the ideal as does Professor Stewart's volume."—*British Medical Journal*.

### **ESSENTIALS OF PHYSICAL DIAGNOSIS OF THE THORAX.**

By ARTHUR M. CORWIN, A. M., M. D., Demonstrator of Physical Diagnosis in the Rush Medical College, Chicago; Attending Physician to the Central Free Dispensary, Department of Rhinology, Laryngology, and Diseases of the Chest. 200 pages. Illustrated. Cloth, flexible covers. Price, \$1.25 net.

**SYLLABUS OF OBSTETRICAL LECTURES in the Medical Department, University of Pennsylvania.** By RICHARD C. NORRIS, A. M., M. D., Lecturer on Clinical and Operative Obstetrics, University of Pennsylvania. Third edition, thoroughly revised and enlarged. Crown 8vo. Price, Cloth, interleaved for notes, \$2.00 net.

"This work is so far superior to others on the same subject that we take pleasure in calling attention briefly to its excellent features. It covers the subject thoroughly, and will prove invaluable both to the student and the practitioner. The author has introduced a number of valuable hints which would only occur to one who was himself an experienced teacher of obstetrics. The subject-matter is clear, forcible, and modern. We are especially pleased with the portion devoted to the practical duties of the accoucheur, care of the child, etc. The paragraphs on antiseptics are admirable; there is no doubtful tone in the directions given. No details are regarded as unimportant; no minor matters omitted. We venture to say that even the old practitioner will find useful hints in this direction which he cannot afford to despise."—*New York Medical Record*.

**A SYLLABUS OF LECTURES ON THE PRACTICE OF SURGERY, arranged in conformity with "An American Text-Book of Surgery."** By N. SENN, M. D., PH. D., Professor of Surgery in Rush Medical College, Chicago, and in the Chicago Polyclinic. Price, \$2.00.

This, the latest work of its eminent author, himself one of the contributors to "An American Text-Book of Surgery," will prove of exceptional value to the advanced student who has adopted that work as his text-book. It is not only the syllabus of an unrivalled course of surgical practice, but it is also an epitome of or supplement to the larger work.

"The author has evidently spared no pains in making his Syllabus thoroughly comprehensive, and has added new matter and alluded to the most recent authors and operations. Full references are also given to all requisite details of surgical anatomy and pathology."—*British Medical Journal*, London.

**AN OPERATION BLANK**, with Lists of Instruments, etc. required in Various Operations. Prepared by W. W. KEEN, M. D., LL.D., Professor of Principles of Surgery in the Jefferson Medical College, Philadelphia. Price per Pad, containing Blanks for fifty operations, 50 cents net.

### SECOND EDITION, REVISED FORM.

A convenient blank, suitable for all operations, giving complete instructions regarding necessary preparation of patient, etc., with a full list of dressings and medicines to be employed.

On the back of each blank is a list of instruments used—viz. general instruments, etc., required for all operations; and special instruments for surgery of the brain and spine, mouth and throat, abdomen, rectum, male and female genito-urinary organs, the bones, etc.

The whole forming a neat pad, arranged for hanging on the wall of a surgeon's office or in the hospital operating-room.

"Will serve a useful purpose for the surgeon in reminding him of the details of preparation for the patient and the room as well as for the instruments, dressings, and antiseptics needed."—*New York Medical Record*

"Covers about all that can be needed in any operation."—*American Lancet*.

"The plan is a capital one."—*Boston Medical and Surgical Journal*.

**LABORATORY EXERCISES IN BOTANY.** By EDSON S. BASTIN, M. A., Professor of Materia Medica and Botany in the Philadelphia College of Pharmacy. Octavo volume of 536 pages, 87 full-page plates. Price, Cloth, \$2.50.

This work is intended for the beginner and the advanced student, and it fully covers the structure of flowering plants, roots, ordinary stems, rhizomes, tubers, bulbs, leaves, flowers, fruits, and seeds. Particular attention is given to the gross and microscopical structure of plants, and to those used in medicine. Illustrations have freely been used to elucidate the text, and a complete index to facilitate reference has been added.

"There is no work like it in the pharmaceutical or botanical literature of this country, and we predict for it a wide circulation."—*American Journal of Pharmacy*.

**DIET IN SICKNESS AND IN HEALTH.** By MRS. ERNEST HART, formerly Student of the Faculty of Medicine of Paris and of the London School of Medicine for Women; with an INTRODUCTION by Sir Henry Thompson, F. R. C. S., M. D., London. 220 pages; illustrated. Price, Cloth, \$1.50.

Useful to those who have to nurse, feed, and prescribe for the sick. In each case the accepted causation of the disease and the reasons for the special diet prescribed are briefly described. Medical men will find the dietaries and recipes practically useful, and likely to save them trouble in directing the dietetic treatment of patients.

**HOW TO EXAMINE FOR LIFE INSURANCE.** By JOHN M. KEATING, M. D., Fellow of the College of Physicians and Surgeons of Philadelphia; Vice-President of the American Pædiatric Society; Ex-President of the Association of Life Insurance Medical Directors. Royal 8vo, 211 pages, with two large half-tone illustrations, and a plate prepared by Dr. McClellan from special dissections; also, numerous cuts to elucidate the text. Second edition. Price, Cloth, \$2.00 net.

"This is by far the most useful book which has yet appeared on insurance examination, a subject of growing interest and importance. Not the least valuable portion of the volume is Part II., which consists of instructions issued to their examining physicians by twenty-four representative companies of this country. As the proofs of these instructions were corrected by the directors of the companies, they form the latest instructions obtainable. If for these alone, the book should be at the right hand of every physician interested in this special branch of medical science."—*The Medical News*, Philadelphia.

**NURSING: ITS PRINCIPLES AND PRACTICE.** By ISABEL ADAMS HAMPTON, Graduate of the New York Training School for Nurses attached to Bellevue Hospital; Superintendent of Nurses and Principal of the Training School for Nurses, Johns Hopkins Hospital, Baltimore, Md.; late Superintendent of Nurses, Illinois Training School for Nurses, Chicago, Ill. In one very handsome 12mo volume of 484 pages, profusely illustrated. Price, Cloth, \$2.00 net.

This original work on the important subject of nursing is at once comprehensive and systematic. It is written in a clear, accurate, and readable style, suitable alike to the student and the lay reader. Such a work has long been a desideratum with those entrusted with the management of hospitals and the instruction of nurses in training-schools. It is also of especial value to the graduated nurse who desires to acquire a practical working knowledge of the care of the sick and the hygiene of the sick-room.

**OBSTETRIC ACCIDENTS, EMERGENCIES, AND OPERATIONS.** By L. CH. BOISLINIERE, M. D., late Emeritus Professor of Obstetrics in the St. Louis Medical College. 381 pages, handsomely illustrated. Price, \$2.00 net.

"For the use of the practitioner who, when away from home, has not the opportunity of consulting a library or of calling a friend in consultation. He then, being thrown upon his own resources, will find this book of benefit in guiding and assisting him in emergencies."

**INFANT'S WEIGHT CHART.** Designed by J. P. CROZER GRIFFITH, M. D., Clinical Professor of Diseases of Children in the University of Pennsylvania. 25 charts in each pad. Price per pad, 50 cents net.

A convenient blank for keeping a record of the child's weight during the first two years of life. Printed on each chart is a curve representing the average weight of a healthy infant, so that any deviation from the normal can readily be detected.

**THE CARE OF THE BABY.** By J. P. CROZER GRIFFITH, M. D., Clinical Professor of Diseases of Children, University of Pennsylvania; Physician to the Children's Hospital, Philadelphia, etc. 404 pages, with 67 illustrations in the text, and 5 plates. 12mo. Price, \$1.50.

**SECOND EDITION, REVISED.**

A reliable guide not only for mothers, but also for medical students and practitioners whose opportunities for observing children have been limited.

"The whole book is characterized by rare good sense, and is evidently written by a master hand. It can be read with benefit not only by mothers, but by medical students and by any practitioners who have not had large opportunities for observing children."—*American Journal of Obstetrics*.

**THE NURSE'S DICTIONARY of Medical Terms and Nursing Treatment**, containing Definitions of the Principal Medical and Nursing Terms, Abbreviations, and Physiological Names, and Descriptions of the Instruments, Drugs, Diseases, Accidents, Treatments, Operations, Foods, Appliances, etc. encountered in the ward or the sick-room. By HONNOR MORTEN, author of "How to Become a Nurse," "Sketches of Hospital Life," etc. 16mo, 140 pages. Price, Cloth, \$1.00.

This little volume is intended for use merely as a small reference-book which can be consulted at the bedside or in the ward. It gives sufficient explanation to the nurse to enable her to comprehend a case until she has leisure to look up larger and fuller works on the subject.

**DIET LISTS AND SICK-ROOM DIETARY.** By JEROME B. THOMAS, M. D., Visiting Physician to the Home for Friendless Women and Children and to the Newsboys' Home; Assistant Visiting Physician to the Kings County Hospital; Assistant Bacteriologist, Brooklyn Health Department. Price, Cloth, \$1.50 (Send for specimen List.)

One hundred and sixty detachable (perforated) diet lists for Albuminuria, Anæmia and Debility, Constipation, Diabetes, Diarrhoea, Dyspepsia, Fevers, Gout or Uric-Acid Diathesis, Obesity, and Tuberculosis. Also forty detachable sheets of Sick-Room Dietary, containing full instructions for preparation of easily-digested foods necessary for invalids. Each list is *numbered only*, the disease for which it is to be used in no case being mentioned, an index key being reserved for the physician's private use.

**DIETS FOR INFANTS AND CHILDREN IN HEALTH AND IN DISEASE.** By LOUIS STARR, M. D., Editor of "An American Text-Book of the Diseases of Children." 230 blanks (pocket-book size), perforated and neatly bound in flexible morocco. Price, \$1.25 net.

The first series of blanks are prepared for the first seven months of infant life; each blank indicates the ingredients, but not the *quantities*, of the food, the latter directions being left for the physician. After the seventh month, modifications being less necessary, the diet lists are printed in full. *Formula* for the preparation of diluents and foods are appended.



# SAUNDERS' NEW SERIES OF MANUALS

---

for Students  
and  
Practitioners.

THAT there exists a need for thoroughly reliable hand-books on the leading branches of Medicine and Surgery is a fact amply demonstrated by the favor with which the SAUNDERS NEW SERIES OF MANUALS have been received by medical students and practitioners and by the Medical Press. These manuals are not merely condensations from present literature, but are ably written by well-known authors and practitioners, most of them being teachers in representative American colleges. Each volume is concisely and authoritatively written and exhaustive in detail, without being encumbered with the introduction of "cases," which so largely expand the ordinary text-book. These manuals will therefore form an admirable collection of advanced lectures, useful alike to the medical student and the practitioner: to the latter, too busy to search through page after page of elaborate treatises for what he wants to know, they will prove of inestimable value; to the former they will afford safe guides to the essential points of study.

The SAUNDERS NEW SERIES OF MANUALS are conceded to be superior to any similar books now on the market. No other manuals afford so much information in such a concise and available form. A liberal expenditure has enabled the publisher to render the mechanical portion of the work worthy of the high literary standard attained by these books.

Any of these Manuals will be mailed on receipt of price (see next page for List).

W. B. SAUNDERS, Publisher,  
925 Walnut Street, Philadelphia.

# SAUNDERS' NEW SERIES OF MANUALS.

## VOLUMES PUBLISHED.

**PHYSIOLOGY.** By JOSEPH HOWARD RAYMOND, A. M., M. D., Professor of Physiology and Hygiene and Lecturer on Gynecology in the Long Island College Hospital, etc. Price, \$1.25 net.

**SURGERY, General and Operative.** By JOHN CHALMERS DACOSTA, M. D., Demonstrator of Surgery, Jefferson Medical College, Philadelphia, etc. Octavo, 911 pages, 386 illustrations. Cloth, \$4.00 net; Half-Morocco, \$5.00 net.

**DOSE-BOOK AND MANUAL OF PRESCRIPTION-WRITING.** By E. Q. THORNTON, M. D., Demonstrator of Therapeutics, Jefferson Medical College, Philadelphia. Price, \$1.25 net.

**MEDICAL JURISPRUDENCE.** By HENRY C. CHAPMAN, M. D., Professor of Institutes of Medicine and Medical Jurisprudence in the Jefferson Medical College of Philadelphia, etc. Price, \$1.50 net.

**SURGICAL ASEPSIS.** By CARL BECK, M. D., Surgeon to St. Mark's Hospital and to the German Poliklinik; Instructor in Surgery, New York Post-Graduate Medical School, etc. Price, \$1.25 net.

**MANUAL OF ANATOMY.** By IRVING S. HAYNES, M. D., Adjunct Professor of Anatomy and Demonstrator of Anatomy, Medical Department of the New York University, etc. (Double number.) Price, \$2.50 net.

**SYPHILIS AND THE VENEREAL DISEASES.** By JAMES NEVINS HYDE, M. D., Professor of Skin and Venereal Diseases, and FRANK H. MONTGOMERY, M. D., Lecturer on Dermatology and Genito-urinary Diseases, in Rush Medical College, Chicago. (Double number.) Price, \$2.50 net.

**PRACTICE OF MEDICINE.** By GEORGE ROE LOCKWOOD, M. D., Professor of Practice in the Woman's Medical College of the New York Infirmary, etc. (Double number.) Price, \$2.50 net.

**OBSTETRICS.** By W. A. NEWMAN DORLAND, M. D., Asst. Demonstrator of Obstetrics, University of Pennsylvania; Chief of Gynecological Dispensary, Pennsylvania Hospital. (Double number.) Price, \$2.50 net.

**DISEASES OF WOMEN.** By J. BLAND SUTTON, F. R. C. S., Assistant Surgeon to the Middlesex Hospital, and Surgeon to the Chelsea Hospital for Women, London; and ARTHUR E. GILES, M. D., B. Sc. Lond., F. R. C. S. Edin., Assistant Surgeon to the Chelsea Hospital for Women, London. 436 pages, handsomely illustrated. (Double number.) Price, \$2.50 net.

## VOLUMES IN PREPARATION.

**NERVOUS DISEASES.** By CHARLES W. BURR, M. D., Clinical Professor of Nervous Diseases, Medico-Chirurgical College, Philadelphia, etc.

**NOSE AND THROAT.** By D. BRADEN KYLE, M. D., Clinical Professor of Laryngology and Rhinology, Jefferson Medical College, Philadelphia.

\*.\* There will be published in the same series, at short intervals, carefully prepared works on various subjects, by prominent specialists.

# SAUNDERS' QUESTION COMPENDS.

Arranged in Question and Answer Form.

---

THE LATEST, MOST COMPLETE, and BEST ILLUSTRATED  
SERIES OF COMPENDS EVER ISSUED.

---

Now the Standard Authorities in Medical Literature

WITH

Students and Practitioners in every City of the United  
States and Canada.

---

## THE REASON WHY.

They are the advance guard of "Student's Helps"—that DO HELP; they are the leaders in their special line, *well and authoritatively written by able men, who, as teachers in the large colleges, know exactly what is wanted by a student preparing for his examinations.* The judgment exercised in the selection of authors is fully demonstrated by their professional elevation. Chosen from the ranks of Demonstrators, Quiz-masters, and Assistants, most of them have become Professors and Lecturers in their respective colleges.

Each book is of convenient size (5 × 7 inches), containing on an average 250 pages, profusely illustrated, and elegantly printed in clear, readable type, on fine paper.

The entire series, numbering twenty-four subjects, has been kept thoroughly revised and enlarged when necessary, many of them being in their fourth and fifth editions.

## TO SUM UP.

Although there are numerous other Quizzes, Manuals, Aids, etc. in the market, none of them approach the "Blue Series of Question Compends;" and the claim is made for the following points of excellence:

1. Professional distinction and reputation of authors.
2. Conciseness, clearness, and soundness of treatment.
3. Size of type and quality of paper and binding.

\* \* \* Any of these Compends will be mailed on receipt of price (see over for List).

# SAUNDERS' QUESTION-COMPEND SERIES.

Price, Cloth, \$1.00 per copy, except when otherwise noted.

1. **ESSENTIALS OF PHYSIOLOGY.** 3d edition. Illustrated. Revised and enlarged by H. A. HARE, M. D. (Price, \$1.00 net.)
2. **ESSENTIALS OF SURGERY.** 6th edition, with an Appendix on Antiseptic Surgery. 90 illustrations. By EDWARD MARTIN, M. D.
3. **ESSENTIALS OF ANATOMY.** 5th edition, with an Appendix. 180 illustrations. By CHARLES B. NANCREDE, M. D.
4. **ESSENTIALS OF MEDICAL CHEMISTRY, ORGANIC AND INORGANIC.** 4th edition, revised, with an Appendix. By LAWRENCE WOLFF, M. D.
5. **ESSENTIALS OF OBSTETRICS.** 4th edition, revised and enlarged. 75 illustrations. By W. EASTERLY ASHTON, M. D.
6. **ESSENTIALS OF PATHOLOGY AND MORBID ANATOMY.** 7th thousand. 46 illustrations. By C. E. ARMAND SEMPLE, M. D.
7. **ESSENTIALS OF MATERIA MEDICA, THERAPEUTICS, AND PRESCRIPTION-WRITING.** 4th edition. By HENRY MORRIS, M. D.
- 8, 9. **ESSENTIALS OF PRACTICE OF MEDICINE.** By HENRY MORRIS, M. D. An Appendix on URINE EXAMINATION. Illustrated. By LAWRENCE WOLFF, M. D. 3d edition, enlarged by some 300 Essential Formulæ, selected from eminent authorities, by WM. M. POWELL, M. D. (Double number, price \$2.00.)
10. **ESSENTIALS OF GYNÆCOLOGY.** 4th edition, revised. With 62 illustrations. By EDWIN B. CRAGIN, M. D.
11. **ESSENTIALS OF DISEASES OF THE SKIN.** 3d edition, revised and enlarged. 71 letter-press cuts and 15 half-tone illustrations. By HENRY W. STELWAGON, M. D. (Price, \$1.00 net.)
12. **ESSENTIALS OF MINOR SURGERY, BANDAGING, AND VENEREAL DISEASES.** 2d edition, revised and enlarged. 78 illustrations. By EDWARD MARTIN, M. D.
13. **ESSENTIALS OF LEGAL MEDICINE, TOXICOLOGY, AND HYGIENE.** 130 illustrations. By C. E. ARMAND SEMPLE, M. D.
14. **ESSENTIALS OF DISEASES OF THE EYE, NOSE, AND THROAT.** 124 illustrations. 2d edition, revised. By EDWARD JACKSON, M. D., and E. BALDWIN GLEASON, M. D.
15. **ESSENTIALS OF DISEASES OF CHILDREN.** Second edition. By WILLIAM H. POWELL, M. D.
16. **ESSENTIALS OF EXAMINATION OF URINE.** Colored "VOGEL SCALE," and numerous illustrations. By LAWRENCE WOLFF, M. D. (Price, 75 cents.)
17. **ESSENTIALS OF DIAGNOSIS.** By S. SOLIS-COHEN, M. D., and A. A. ESHNER, M. D. 55 illustrations, some in colors. (Price, \$1.50 net.)
18. **ESSENTIALS OF PRACTICE OF PHARMACY.** By L. E. SAYRE. 2d edition, revised.
20. **ESSENTIALS OF BACTERIOLOGY.** 3d edition. 82 illustrations. By M. V. BALL, M. D.
21. **ESSENTIALS OF NERVOUS DISEASES AND INSANITY** 48 illustrations. 3d edition, revised. By JOHN C. SHAW, M. D.
22. **ESSENTIALS OF MEDICAL PHYSICS.** 155 illustrations. 2d edition, revised. By FRED J. BROCKWAY, M. D. (Price, \$1.00 net.)
23. **ESSENTIALS OF MEDICAL ELECTRICITY.** 65 illustrations. By DAVID D. STEWART, M. D., and EDWARD S. LAWRENCE, M. D.
24. **ESSENTIALS OF DISEASES OF THE EAR.** By E. B. GLEASON, M. D. 114 illustrations. Second edition, revised and enlarged.

# RECENT PUBLICATIONS

---

## PENROSE'S DISEASES OF WOMEN

**A Text-Book of Diseases of Women.** By CHARLES B. PENROSE, M.D., PH.D., Professor of Gynecology in the University of Pennsylvania; Surgeon to the Gynecean Hospital, Philadelphia. Octavo volume of 529 pages, handsomely illustrated. Cloth, \$3.50 net.

"I shall value very highly the copy of Penrose's "Diseases of Women" received. I have already recommended it to my class as THE BEST book."—HOWARD A. KELLY, *Professor of Gynecology and Obstetrics, Johns Hopkins University, Baltimore, Md.*

## SENN'S GENITO-URINARY TUBERCULOSIS

**Tuberculosis of the Genito-Urinary Organs, Male and Female.** By NICHOLAS SENN, M.D., PH.D., LL.D., Professor of the Practice of Surgery and of Clinical Surgery, Rush Medical College, Chicago. Handsome octavo volume of 320 pages, illustrated. Cloth, \$3.00 net.

## SUTTON AND GILES' DISEASES OF WOMEN

**Diseases of Women.** By J. BLAND SUTTON, F.R.C.S., Assistant Surgeon to Middlesex Hospital, and Surgeon to Chelsea Hospital, London; and ARTHUR E. GILES, M.D., B.Sc. Lond., F.R.C.S. Edin., Assistant Surgeon to Chelsea Hospital, London. 436 pages, handsomely illustrated. Cloth, \$2.50 net.

## BUTLER'S MATERIA MEDICA, THERAPEUTICS, AND PHARMACOLOGY. Second Edition, Revised

**A Text-Book of Materia Medica, Therapeutics, and Pharmacology.** By GEORGE F. BUTLER, PH.G., M.D., Professor of Materia Medica and of Clinical Medicine in the College of Physicians and Surgeons, Chicago; Professor of Materia Medica and Therapeutics, Northwestern University, Woman's Medical School, etc. Octavo, 858 pages, illustrated. Cloth, \$4.00 net; Sheep, \$5.00 net.

## SAUNDBY'S RENAL AND URINARY DISEASES

**Lectures on Renal and Urinary Diseases.** By ROBERT SAUNDBY, M.D. Edin., Fellow of the Royal College of Physicians, London, and of the Royal Medico-Chirurgical Society; Physician to the General Hospital; Consulting Physician to the Eye Hospital and to the Hospital for Diseases of Women; Professor of Medicine in Mason College, Birmingham, etc. Octavo volume of 434 pages, with numerous illustrations and 4 colored plates. Cloth, \$2.50 net.

## PYE'S BANDAGING

**Elementary Bandaging and Surgical Dressing, with Directions Concerning the Immediate Treatment of Cases of Emergency. For the Use of Dressers and Nurses.** By WALTER PYE, F.R.C.S., Late Surgeon to St. Mary's Hospital, London. Small 12mo, with over 80 illustrations. Cloth, flexible covers. Price, 75 cents net.

## MALLORY AND WRIGHT'S PATHOLOGICAL TECHNIQUE

**Pathological Technique.** By FRANK B. MALLORY, A.M., M.D., Assistant Professor of Pathology, Harvard University Medical School; and JAMES H. WRIGHT, A.M., M.D., Instructor in Pathology, Harvard University Medical School. Octavo volume of 396 pages, handsomely illustrated. Cloth, \$2.50 net.

"I have been looking forward to the publication of this book, and I am glad to say that I find it to be a most useful laboratory and post-mortem guide, full of practical information, and well up to date."—WILLIAM H. WELCH, *Professor of Pathology, Johns Hopkins University, Baltimore, Md.*

## ANDERS' PRACTICE OF MEDICINE. Second Edition

**A Text-Book of the Practice of Medicine.** By JAMES M. ANDERS, M.D., PH.D., LL.D., Professor of the Practice of Medicine and of Clinical Medicine, Medico-Chirurgical College, Philadelphia. In one handsome octavo volume of 1287 pages, fully illustrated. Cloth, \$5.50 net; Sheep or Half Morocco, \$6.50 net.

# ANOMALIES

## AND

### CURIOSITIES OF MEDICINE.

BY

GEORGE M. GOULD, M. D., AND WALTER L. PYLE, M. D.

Several years of exhaustive research have been spent by the authors in the great medical libraries of the United States and Europe in collecting the material for this work. **Medical literature of all ages and all languages** has been carefully searched, as a glance at the Bibliographic Index will show. The facts, which will be of **extreme value to the author and lecturer**, have been arranged and annotated, and full reference footnotes given, indicating whence they have been obtained.

In view of the persistent and dominant interest in the anomalous and curious, a **thorough and systematic collection** of this kind (the first of which the authors have knowledge) must have its own peculiar sphere of usefulness.

As a complete and authoritative **Book of Reference** it will be of value not only to members of the medical profession, but to all persons interested in general scientific, sociologic, and medico-legal topics; in fact, the general interest of the subject and the dearth of any complete work upon it make this volume **one of the most important literary innovations of the day.**

An especially valuable feature of the book consists of the **Indexing.** Besides a complete and comprehensive **General Index**, containing numerous cross-references to the subjects discussed, and the names of the authors of the more important reports, there is a convenient **Bibliographic Index** and a **Table of Contents.**

The plan has been adopted of printing the **topical headings in bold-face type**, the reader being thereby enabled to tell at a glance the subject-matter of any particular paragraph or page.

**Illustrations** have been freely employed throughout the work, there being 165 relief cuts and 130 half-tones in the text, and 12 colored and half-tone full-page plates—a total of over 320 separate figures.

The careful rendering of the text and references, the wealth of illustrations, the mechanical skill represented in the typography, the printing, and the binding, combine to make this book one of the most attractive medical publications ever issued.

---

Handsome Imperial Octavo Volume of 968 Pages.

PRICES: Cloth, \$6.00 net; Half Morocco, \$7.00 net.

## JUST ISSUED

### AN AMERICAN TEXT-BOOK OF GENITO-URINARY AND SKIN DISEASES

Edited by L. BOLTON BANGS, M.D., Late Professor of Genito-Urinary and Venereal Diseases, New York Post-Graduate Medical School and Hospital; and WILLIAM A. HARDAWAY, M.D., Professor of Diseases of the Skin, Missouri Medical College. Octavo volume of over 1200 pages, with 300 illustrations in the text, and 20 full-page colored plates. Prices: Cloth, \$7.00 net; Sheep or Half Morocco, \$8.00 net.

### MOORE'S ORTHOPEDIC SURGERY

**A Manual of Orthopedic Surgery.** By JAMES E. MOORE, M.D., Professor of Orthopedics and Adjunct Professor of Clinical Surgery, University of Minnesota, College of Medicine and Surgery. 8vo, 356 pages, handsomely illustrated. Cloth, \$2.50 net.

### MACDONALD'S SURGICAL DIAGNOSIS AND TREATMENT

**Surgical Diagnosis and Treatment.** By J. W. MACDONALD, M.D. Edin., L.R.C.S. Edin., Professor of the Practice of Surgery and of Clinical Surgery in Hamline University; Visiting Surgeon to St. Barnabas' Hospital, Minneapolis, etc. Octavo volume of 800 pages, handsomely illustrated. Cloth, \$5.00 net; Half Morocco, \$6.00 net.

### CHAPIN ON INSANITY

**A Compendium of Insanity.** By JOHN B. CHAPIN, M.D., LL.D., Physician-in-Chief, Pennsylvania Hospital for the Insane; late Physician-Superintendent of the Willard State Hospital, New York, etc. 12mo., 234 pages, illustrated. Cloth, \$1.25 net.

### KEEN ON THE SURGERY OF TYPHOID FEVER

**The Surgical Complications and Sequels of Typhoid Fever.** By WM. W. KEEN, M.D., LL.D., Professor of the Principles of Surgery and of Clinical Surgery, Jefferson Medical College, Philada. Octavo volume of 400 pages. Cloth, \$3.00 net.

### VAN VALZAH AND NISBET'S DISEASES OF THE STOMACH

**Diseases of the Stomach.** By WILLIAM W. VAN VALZAH, M.D., Professor of General Medicine and Diseases of the Digestive System and the Blood, New York Polyclinic; and J. DOUGLAS NISBET, M.D., Adjunct Professor of General Medicine and Diseases of the Digestive System and the Blood, New York Polyclinic. Octavo volume of 674 pages, illustrated. Cloth, \$3.50 net.

## IN PREPARATION

### AN AMERICAN TEXT-BOOK OF DISEASES OF THE EYE, EAR, NOSE, AND THROAT

Edited by G. E. DE SCHWEINITZ, M.D., Professor of Ophthalmology in the Jefferson Medical College; and B. ALEXANDER RANDALL, M.D., Professor of Diseases of the Ear in the University of Pennsylvania and in the Philadelphia Polyclinic.

### CHURCH AND PETERSON'S NERVOUS AND MENTAL DISEASES

**Nervous and Mental Diseases.** By ARCHIBALD CHURCH, M.D., Professor of Mental Diseases and Medical Jurisprudence, Northwestern University Medical School, Chicago; and FREDERICK PETERSON, M.D., Clinical Professor of Mental Diseases, Woman's Medical College, New York, etc.

### KYLE ON THE NOSE AND THROAT

**Diseases of the Nose and Throat.** By D. BRADEN KYLE, M.D., Clinical Professor of Laryngology and Rhinology, Jefferson Medical College, Philadelphia; Consulting Laryngologist, Rhinologist, and Otologist, St. Agnes' Hospital, etc.

### STENGEL'S PATHOLOGY

**A Manual of Pathology.** By ALFRED STENGEL, M.D., Physician to the Philadelphia Hospital; Professor of Clinical Medicine in the Woman's Medical College; Physician to the Children's Hospital, etc.

### HIRST'S OBSTETRICS

**A Text-Book of Obstetrics.** By BARTON COOKE HIRST, M.D., Professor of Obstetrics, University of Pennsylvania.

### HEISLER'S EMBRYOLOGY

**A Text-Book of Embryology.** By JOHN C. HEISLER, M.D., Professor of Anatomy, Medico-Chirurgical College, Philadelphia.

NOW READY, VOLUMES FOR 1896, 1897, 1898.

SAUNDERS'  
AMERICAN YEAR-BOOK OF MEDICINE and SURGERY.

Edited by GEORGE M. GOULD, A. M., M. D.

Assisted by Eminent American Specialists and Teachers.

NOTWITHSTANDING the rapid multiplication of medical and surgical works, still these publications fail to meet fully the requirements of the *general physician*, inasmuch as he feels the need of something more than mere text-books of well-known principles of medical science. Mr. Saunders has long been impressed with this fact, which is confirmed by the unanimity of expression from the profession at large, as indicated by advices from his large corps of canvassers.

This deficiency would best be met by current journalistic literature, but most practitioners have scant access to this almost unlimited source of information, and the busy practiser has but little time to search out in periodicals the many interesting cases whose study would doubtless be of inestimable value in his practice. Therefore, a work which places before the physician in convenient form *an epitomization of this literature by persons competent to pronounce upon*

**The Value of a Discovery or of a Method of Treatment**

cannot but command his highest appreciation. It is this critical and judicial function that will be assumed by the Editorial staff of the "American Year-Book of Medicine and Surgery."

It is the special purpose of the Editor, whose experience peculiarly qualifies him for the preparation of this work, not only to review the contributions to American journals, but also the methods and discoveries reported in the leading medical journals of Europe, thus enlarging the survey and making the work characteristically **international**. These reviews will not simply be a series of undigested abstracts indiscriminately run together, nor will they be retrospective of "news" *one or two years old*, but the treatment presented will be *synthetic* and *dogmatic*, and will include **only what is new**. Moreover, through expert condensation by experienced writers these discussions will be

**Comprised in a Single Volume of about 1200 Pages.**

The work will be replete with **original** and **selected** illustrations skilfully reproduced, for the most part in Mr. Saunders' own studios established for the purpose, thus ensuring accuracy in delineation, affording efficient aids to a right comprehension of the text, and adding to the attractiveness of the volume. Prices: Cloth, \$6.50 net; Half Morocco, \$7.50 net.


W. B. SAUNDERS, Publisher,  
925 Walnut Street, Philadelphia.

The knowledge gained is equal to a post-graduate course.

Uniform with the "American Text-Book" Series.







# Date Due


University of California  
SOUTHERN REGIONAL LIBRARY FACILITY  
305 De Neve Drive - Parking Lot 17 • Box 951388  
LOS ANGELES, CALIFORNIA 90095-1388

Return this material to the library from which it was borrowed.

AC MAY 03 2004

# VOLUMES N

UC SOUTHERN REGIONAL LIBRARY FACILITY



A 000 509 954 4

## Atlas of Internal Medicine

DR. CHR. JAKOB, of Erlang

ESHNER, M.D., Professor of Clinical Medicine in the Philadelphia Polyclinic; Attending Physician to the Philadelphia Hospital. 68 colored plates. Cloth, \$3.00 net.

## Atlas of Legal Medicine.

By DR. E. VON HOFMANN, of Vienna. Edited by FREDERICK PETERSON, M.D., Clinical Professor of Mental Diseases, Woman's Medical College, New York; Chief of Clinic Nervous Dept. College of Physicians and Surgeons, New York.

W700

on 56

et.

H713a

1898

## Atlas

of M

ture

Penn

ment

figur

Hofmann, Eduard von

Atlas of legal medicine.

## Atlas

Vier

Prof

Surg

and

W700

H713a

1898

## Atlas

Hofmann, Eduard von

DR.

BAN

Dise

pital

A. S

Atlas of legal medicine.

IN

## Atlas

of Z

sor o

phia.

## Atlas

Vien

by A

MEDICAL SCIENCES LIBRARY  
UNIVERSITY OF CALIFORNIA, IRVINE  
IRVINE, CALIFORNIA 92664

